

# Intracranial meningiomas in childhood

Martin Cooper, M.D.\*  
Donald F. Dohn, M.D.

*Department of Neurological  
Surgery*

Intracranial meningiomas in children are rare. In the 15 series reviewed by Mendiratta et al,<sup>1</sup> which included 2,620 intracranial tumors in childhood, meningiomas accounted for 1.5%. The incidence of meningiomas in adult intracranial tumors varies from 10% to 15%. From 1960 through 1973, seven children with intracranial meningiomas were seen in the Department of Neurological Surgery at the Cleveland Clinic. These patients, all of whom underwent surgery, form the basis for this paper. The series included five girls and two boys; other reported series do not show this sex predilection. At the time of diagnosis their ages ranged from 7 to 14 years (average, 11 years). Childhood, in this series, is defined as 16 years of age and younger.

## Symptoms

Headache was an initial symptom in three patients. This corroborated the findings of Crouse and Berg,<sup>2</sup> in which headache was the initial symptom in 11 of 13 patients. Seizures occurred in four of the seven patients and were manifested by "drop attacks," periods of "absence," generalized tonic-clonic convulsions, and focal motor episodes. Gradual hemiparesis occurred in two patients. Three patients complained of double vision. The duration of the various symptoms ranged from several weeks to 6 years.

\* Fellow, Department of Neurological Surgery.

### Physical findings

Neurological examination revealed mild confusion and disorientation in three patients. Two patients had papilledema and one had monocular blindness. Deficits in visual fields were present in two; central type facial weakness occurred in three; spastic hemiparesis was present in two patients.

### Roentgenography

Skull roentgenograms showed abnormalities in all seven patients. In one patient there was thinning of the posterior clinoids and erosion of the floor of the sella turcica from chronic increased pressure. Another patient had separation of the cranial sutures. Three patients had large calcified masses easily discernible on the plain roentgenograms. One calcified mass was midline and at operation was found to be a falx meningioma. Another was suprasellar with lateral extension. The third was in the temporal region and proved to be a sphenoid wing meningioma. It was a rock hard calcified mass wrapped around the internal carotid artery and its bifurcation.

Cerebral angiography was performed in six of the seven patients. In only one was there a hypertrophic feeding vessel. This was the anterior choroidal artery in a patient (case 5) with an intraventricular meningioma. The angiograms in the other patients so studied revealed either displacement or draping of the intracranial vessels without tumor stain.

Pneumoencephalography was done in three patients and demonstrated blunting of the tip of a temporal horn, displacement of ventricular

structures, and protrusion of the tumor into the interpeduncular cistern.

### Other studies

Electroencephalography was performed in three patients. Delta wave abnormalities were reported in two and diffuse dysrhythmia in one. Isotopic brain scans performed in four patients were positive in all and significantly helpful in localization.

### Review of cases

All seven patients underwent intracranial surgery. One patient (case 2) had complete removal of a sphenoid wing meningioma at the age of 14 years. She is free of seizures and is neurologically well 13 years following surgery.

A falx meningioma was totally removed from a second patient (case 4) who is doing well 6 years after surgery, except for occasional spells of "absence."

Another patient (case 5) who had an intraventricular tumor removed completely is now 4 years postoperative. She has a left homonymous hemianopsia secondary to the surgical cerebral incision, but is otherwise normal.

An 8-year-old boy (case 6) had been operated elsewhere for a tumor 9 months and 1 month prior to his admission to the Cleveland Clinic. At the second recurrence the tumor, which filled the middle fossa, was removed completely except for a fringe along the tentorial edge attached to the trochlear nerve. This attachment was bipolar coagulated, and the patient was given cobalt 60 therapy postoperatively. Except for one seizure, he is now doing well 3½ years following surgery.

Two patients died. One patient

**Table. Intracranial meningiomas, 1960-1973, Cleveland Clinic**

| Case | Age | Sex | Symptoms   | Signs  | Procedures                                  | Pathology   | Postoperative results   | Follow-up  |
|------|-----|-----|--|--|---|---|---|--|
| 1    | 7   | F   | Left arm and leg weakness, decreased visual acuity   | Left hemiparesis with hyperreflexia and Babinski sign, papilledema | Right parietal occipital craniotomy 7-13-61 | Sarcomatous pial meningioma (convexity)                 | Seizures, left hemiparesis, cobalt 60 irradiation to head and spine | Progressive course—seizures, paraplegia secondary to spinal metastases; died 8-19-62 |
| 2    | 14  | F   | Seizures since age 8, blackout spells, intermittent double vision  | Nystagmus  | Left temporal craniotomy 7-27-61            | Fibroblastic meningioma (sphenoid wing)                 | No neurological deficit, seizure free                               | 13 yr, doing well  |
| 3    | 13  | F   | Headaches, nausea, vomiting, visual impairment   | Right optic atrophy, left papilledema, lethargy                    | Right frontal craniotomy 4-5-63             | Meningioma (atypical and actively growing), basalsellar | Left hemiparesis, lethargy, seizure disorder, cobalt 60 irradiation | Continued problems, several shunt procedures for hydrocephalus; died 10-10-66        |
| 4    | 13  | F   | Cerebellar medulloblastoma, operated at age 11 mo, cobalt irradiation, residual mild unsteadiness of gait; new symptom—one generalized seizure | Ataxic gait, positive Romberg, nystagmus, dysmetria                | Right parietal occipital craniotomy 8-6-68  | Meningothelial meningioma (falx)                        | Minor spells, poor memory   | 6 yr, static   |
| 5    | 14  | F   | Headaches, syncopal attacks, double vision, visual hallucinations  | Papilledema  | Right parietal craniotomy 10-9-69           | Meningothelial meningioma (intraventricular)            | Left homonymous hemianopsia "auras" of nausea                       | 4 yr, static   |
| 6    | 8   | M   | Headaches and left sided focal seizures, 2 prior craniotomies for subtotal removal of meningioma (11-69 and 7-71—another hospital)             | Normal examination   | Left temporal craniotomy 8-21-70            | Meningothelial meningioma                               | No neurological deficit   | 3½ yr, doing well except for rare seizures   |
| 7    | 10  | M   | Headaches, clumsy walking, awkward use of left arm and hand  | Left facial weakness, spastic hemiparesis, left hemiatrophy        | Right frontotemporal craniotomy 9-7-73      | Transitional meningioma (sphenoid wing)                 | Mild left hemiparesis   | 1 yr, improving  |

(case 1) with a sarcomatous meningioma died 14 months following her first admission and surgery. The tumor had spread to her spinal canal and she was paraplegic at the time of her death. She died at home and no autopsy was done.

The second patient (case 3) who had an actively growing suprasellar meningioma died 3½ years after her first admission and surgery.

The remaining patient, our most recent (case 7), will be described in more detail because of the interesting features of his case.

### Case report

A 10-year-old, right-handed white boy was admitted on August 26, 1973. He had been adopted at age 5 months; his family history was not known. The boy had walked at one year. His speech was considered normal, and he was toilet trained before he was 3 years old. In kindergarten he was thought to be clumsy. The child began to complain of generalized headaches 3 months before admission. The headache was occasionally associated with nausea. In April 1973 the patient was noted to be awkward in the use of his left hand. By June he limped and dragged his left foot and carried his left shoulder much lower than the right.

Examination showed one café au lait spot on the right buttock and mild hemiatrophy of the left arm and leg. The neurological examination showed left spastic hemiparesis more pronounced distally than proximally. There was an associated hemiplegic gait, central facial weakness, and hyperreflexia on the left. He also had left homonymous hemianopsia.

Roentgenography of the skull demonstrated a large, fluffy calcification in right parasellar and middle fossa regions (*Fig. 1*). The electroencephalogram had a right temporal delta wave abnormality. A pneumoencephalogram was diagnostic of a mass in the anterior basal region, with elevation

of the floor of the right lateral ventricle and displacement of the anterior third ventricle to the left (*Fig. 2*). Right carotid angiography showed only minimal displacement of the middle cerebral and anterior choroidal arteries (*Figs. 3 A and B*).

On September 7, 1973, the patient underwent a right frontotemporal craniotomy with subtotal removal of the tumor. All soft portions of the tumor were removed. Much of the calcified areas were also removed; however, those parts encasing the internal carotid artery and its bifurcation were left in place for fear of lacerating the vessels. The pathologic diagnosis was transitional meningioma. The patient had an uneventful postoperative course and when seen 1 year later he was doing well and demonstrated improvement in the left hemiparesis.

### Discussion

**Incidence.** Ingraham and Matson<sup>3</sup> reported three meningiomas in a series of 750 intracranial tumors in children younger than age 14 years seen at the Boston Childrens Hospital during a 30-year period prior to 1967. These three tumors were falx, intraventricular, and parasagittal with frontal bone invasion respectively. Bailey et al<sup>4</sup> found two meningiomas in 100 intracranial tumors in children. In a group of 606 children with brain tumors, Keith et al<sup>5</sup> found only three meningiomas. Cuneo and Rand,<sup>6</sup> in 83 cases in the pediatric age range found two meningiomas. One of these tumors was in the chiasmal region, the other was in the left occipital area. Cushing and Eisenhardt<sup>7</sup> found six meningiomas in patients younger than 20 years in their total series of 315 meningioma cases. Of 273 brain tumors in children, French<sup>8</sup> found seven cases of meningiomas.

**Location.** Most intracranial meningiomas in children are supratentorial.

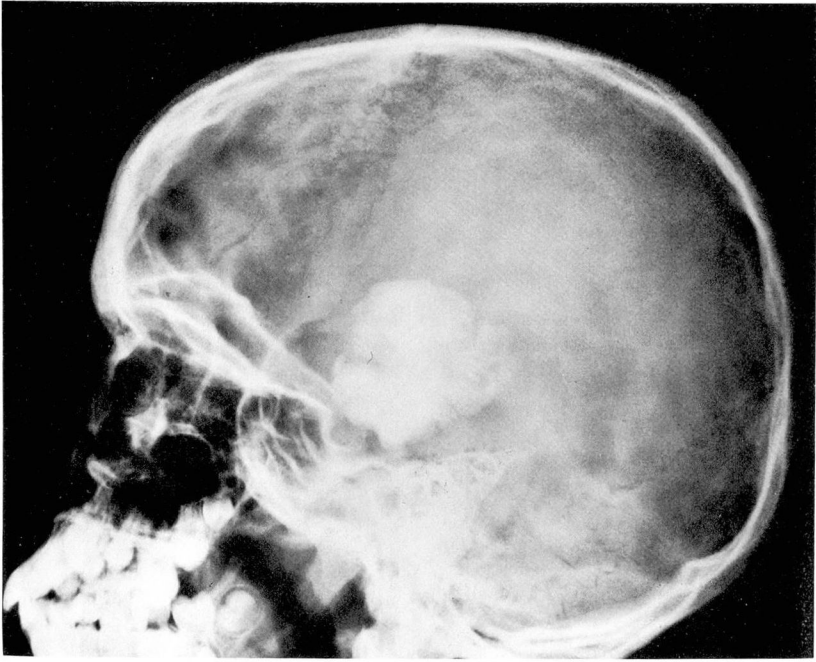

Fig. 1. Case 7. Plain skull roentgenogram, lateral view showing large temporal calcified mass.

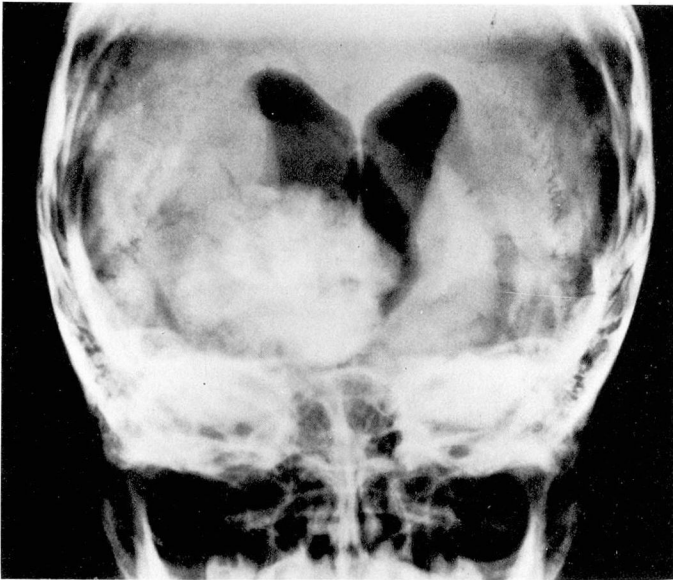


Fig. 2. Case 7. Pneumoencephalogram, anteroposterior view demonstrating calcified mass displacing and deforming third ventricle.



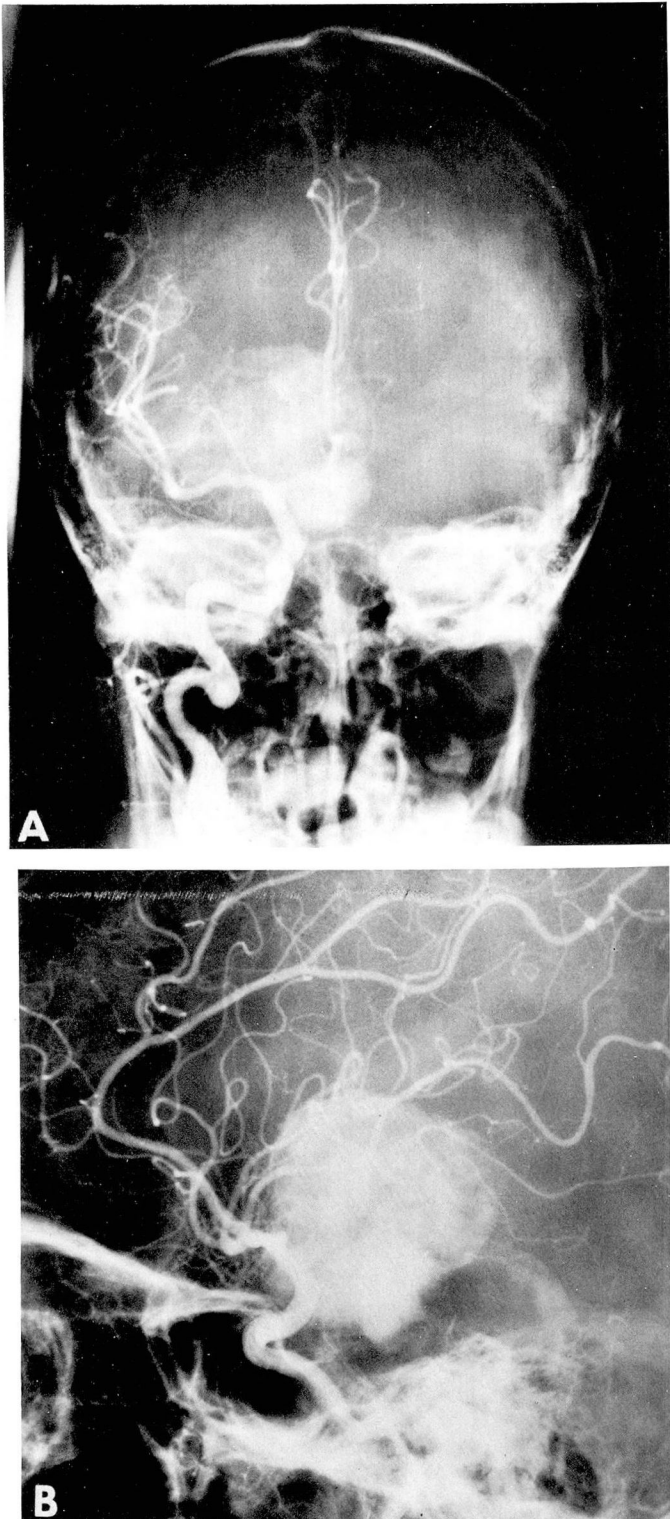


Fig. 3 A and B, Right carotid angiogram showing surprisingly little displacement of vessels; *top*, anteroposterior view—*anterior choroidal artery is displaced laterally and elevated*; *bottom*, lateral view—*some stretching of internal carotid artery*.

Crouse and Berg<sup>2</sup> however, reported that 6 of 13 children with meningiomas had posterior fossa localization. An interesting case reported by Bengochea et al,<sup>9</sup> a 3-year-old child with left facial paralysis and deafness, was found to have a meningioma of the internal auditory meatus. Porras<sup>10</sup> reported a case in which the child who had nausea, vomiting, and unsteady gait was found to have a meningioma in the foramen magnum. Teng and Papatheodorou,<sup>11</sup> reporting the case of a 4-year-old child with both suprachiasmatic and intraventricular meningiomas, pointed out that one of the interesting features of meningiomas in this age group is the occasional lack of dural attachment. Abraham and Chandhy<sup>12</sup> reviewed the literature and collected 12 cases of meningiomas of the posterior fossa without dural attachment and, within this group, four patients were 16 years of age or younger.

### **Congenital occurrence**

Particularly rare is the occurrence of congenital meningiomas. Mendiratta et al<sup>1</sup> reported myoclonic and focal motor seizures in an infant who was found to have subdural cysts and a large retrosylvian meningioma. Cuneo and Rand<sup>6</sup> described a 3-month-old boy who had vomiting and rigidity since birth, and bilateral corticospinal tract signs. At surgery a large calcified angioblastic meningioma was found. In a case reported by Taptas,<sup>13</sup> a boy at age 2 months was noted to have enlargement of the head, and at 4 months papilledema. Although a subdural hematoma was suspected he was found to have a fibroblastic meningioma.

### **Pathology**

Meningiomas in childhood tend to grow rapidly and have sarcomatous changes. Globus<sup>14</sup> believed that undifferentiated mesoderm was the origin of the meningeal membranes, and that growth from the undifferentiated cells could lead to a mesenchymatous meningioma, which could be transformed into a sarcomatous form. In our series we had one case of sarcomatous meningioma and another with a histologic picture of cellular atypia and rapid growth. Both of these patients died following a progressive course and represent our only mortality. They lived only 14 months and 40 months after diagnosis. Four of Crouse and Berg's<sup>2</sup> 13 cases were meningeal sarcomas and one was a meningioma with sarcomatous changes. As in adult meningiomas, the histologic type cannot be exactly correlated with prognosis or recurrence rate. Our case 6 illustrates this point. Despite a benign microscopic appearance, the tumor recurred twice and seemingly was brought under control by the use of cobalt 60 irradiation. Of special note is our patient (case 2) in whom a benign meningioma developed approximately 12 years after she had received irradiation with cobalt 60 for a malignant medulloblastoma. She still has no evidence of recurrence of the medulloblastoma, despite the 18 years that have elapsed since diagnosis. The development of mesodermal tumors of the central nervous system following radiation therapy have been described recently.<sup>15</sup>

### **Treatment**

The treatment of meningiomas in childhood as in adults is primarily surgical. Meningeal sarcomas present

a particularly difficult problem in treatment and should be irradiated. In our opinion certain meningiomas, regardless of their histologic picture, should be irradiated if they recur aggressively.

### Summary

Seven children with meningiomas were operated on at the Cleveland Clinic between 1960 and 1973. The locations varied including one intraventricular meningioma; none were in the posterior fossa. All demonstrated changes on the plain skull roentgenograms; three with large calcifications. One occurred probably as a late effect of cobalt 60 irradiation for a posterior fossa glioma. The only two with a malignant histologic picture are dead. The other five are doing well.

### References

1. Mendiratta SS, Rosenblum JA, Strobos RJ: Congenital meningioma. *Neurology* **17**: 914-918, 1967.
2. Crouse SK, Berg BO: Intracranial meningiomas in childhood and adolescence. *Neurology* **22**: 135-141, 1972.
3. Ingraham FD, Matson DD: *Neurosurgery of Infancy and Childhood*. Second edition. Springfield, Illinois, Charles C Thomas, 1969.
4. Bailey P, Buchanan DN, Bucy PC: *Intracranial Tumors of Infancy and Childhood*. Chicago, University of Chicago Press, 1939.
5. Keith HM, Craig WM, Kernohan JW: Brain tumors in children. *Pediatrics* **3**: 839-844, 1949.
6. Cuneo HM, Rand CW: *Brain Tumors of Childhood*. Springfield, Illinois, Charles C Thomas, 1952.
7. Cushing H, Eisenhardt L: *Meningiomas, Their Classification, Regional Behavior, Life History, and Surgical End Results*. Springfield, Illinois, Charles C Thomas, 1938.
8. French L: Tumors—Intracranial and cranial, in *Pediatric Neurosurgery*. Edited by IJ Jackson, RK Thompson, Springfield, Illinois, Charles C Thomas, 1959.
9. Bengochea FG, Fusté R, Carrera JCF, et al: Meningioma of the internal auditory meatus in a child 3 years old. *J Neurosurg* **13**: 215-218, 1956.
10. Porras CL: Meningioma in the foramen magnum in a boy aged 8 years. *J Neurosurg* **20**: 167-168, 1963.
11. Teng P, Papatheodorou C: Suprachiasmatic and intraventricular meningioma in a 4-year-old child. *J Neurosurg* **20**: 174-176, 1963.
12. Abraham J, Chandy J: Meningiomas of the posterior fossa without dural attachment. A case report. *J Neurosurg* **20**: 177-179, 1963.
13. Taptas JN: Intracranial meningioma in a four-month-old infant simulating subdural hematoma. *J Neurosurg* **18**: 120-121, 1961.
14. Globus JH: Meningiomas; their origin, divergence in structure, and relationship to contiguous tissues in light of phylogenesis and ontogenesis of meninges; with suggestion of simplified classification of meningeal neoplasms, in *Tumors of the Nervous System*. *Assoc Res Nerv Ment Dis, Proc* **16**: 210-265, 1935.
15. Norwood CW, Kelly DL Jr, Davis CH Jr, et al: Irradiation induced mesodermal tumors of the central nervous system; report on two meningiomas following x-ray treatment for gliomas. *Surg Neurol* **2**: 161-164, 1974.