

Anaerobic pleuropulmonary infections

Clinical considerations

Sydney M. Finegold, M.D.*
John G. Bartlett, M.D.†

Anaerobic infections are undoubtedly the most commonly overlooked of all bacterial infections. This is the case in pleuropulmonary infections, particularly when specimens for anaerobic culture usually are not obtained and standard microbiologic techniques often are inadequate. The purpose of this paper is to discuss a few of the clinical problems associated with anaerobic pleuropulmonary infections, to mention techniques for collection of materials for proper culture of anaerobic pulmonary pathogens, and to consider briefly the spectrum of pulmonary diseases produced by anaerobes based on our recent experiences.

Figure 1 is the posteroanterior chest roentgenogram of a 67-year-old man who had just been admitted to the hospital with an extensive necrotizing pneumonia involving much of the left lung. There was apparently an empyema at the right base as well, but numerous attempts at recovering fluid from this area by thoracentesis were unsuccessful. Coughed sputum culture yielded *Pseudomonas aeruginosa* in heavy growth. The house officer questioned this laboratory report, since this patient had not been hospitalized previously, and it would be most unusual for someone to come into the hospital with an extensive necrotizing pneumonia due to *P. aeruginosa* in the absence of any severe underlying disease. Furthermore, the patient had been chronically ill for 6 months and had lost 27.3 kg before becoming acutely ill and

* Department of Medicine, Wadsworth Veterans Hospital, and the University of California Medical Center, Los Angeles, California.

† Infectious Disease Section, Veterans Administration Hospital, Sepulveda, California and the University of California Medical Center, Los Angeles, California.

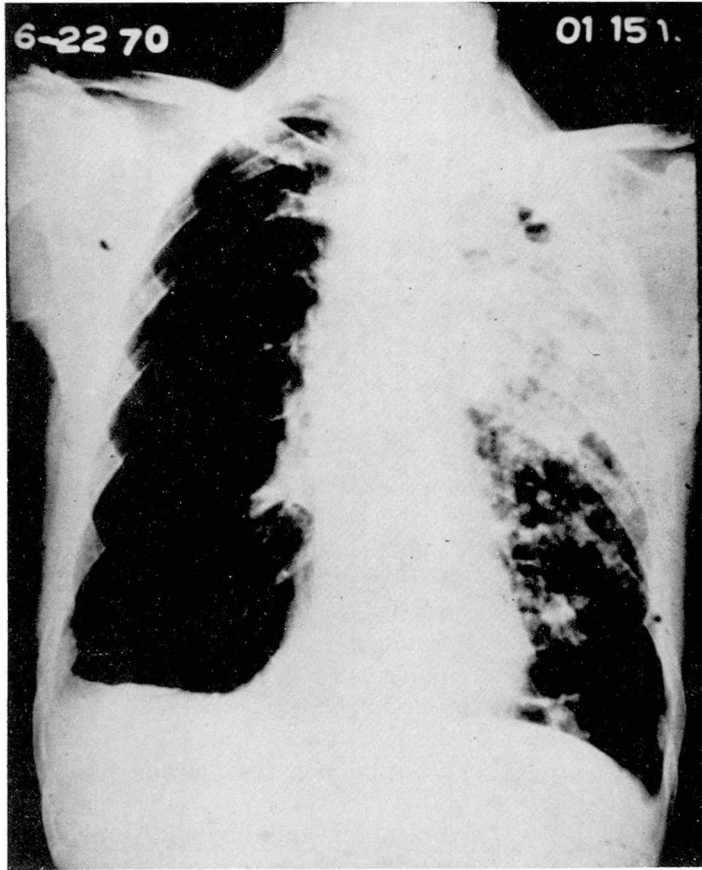


Fig. 1. Chest roentgenogram showing necrotizing pneumonia involving left lung.

seeking hospitalization. Again, this is not the clinical picture of *Pseudomonas pneumoniae*. In addition, this patient was an alcoholic and thus might well have aspirated and was bringing up foul-smelling sputum, a sure indication that anaerobes must be involved in the process. Accordingly, a transtracheal aspiration was done to bypass the indigenous flora of the mouth and upper respiratory tract. This specimen yielded no *P. aeruginosa*, but instead six different anaerobic organisms, all in high counts. Had the patient been treated with gentamicin on the basis of the original lab-

oratory report, he undoubtedly would have died, inasmuch as anaerobes typically are resistant to aminoglycosides. This case is not an unusual one. Among 70 patients with documented anaerobic pulmonary infection, there were 23 instances of potential aerobic pathogens (*Staphylococcus aureus*, 7; *P. aeruginosa*, 7; *Diplococcus pneumoniae*, 9; *Klebsiella-Enterobacter*, 2; *Escherichia coli*, 4; *Haemophilus influenzae*, 3) recovered from expectorated sputum, but not found on transtracheal aspiration or in material otherwise more directly collected. Figure 2 shows that there are significant

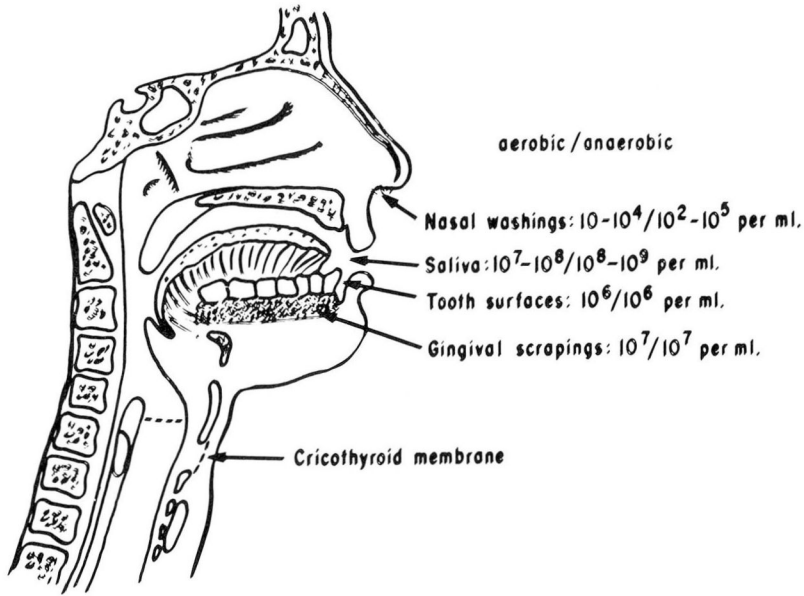


Fig. 2. Drawing showing location of aerobic and anaerobic bacteria. (Reproduced with permission of author. Hoepfich PD: Etiologic diagnosis of lower respiratory tract infections. Calif Med 112: 1-8, 1970.)

numbers of both aerobic and anaerobic bacteria in the mouth and upper respiratory passages, and further emphasizes the necessity of bypassing such areas of normal flora in order to document accurately the nature of pulmonary infection. This is particularly true in the case of suspected anaerobic infection. Transtracheal aspiration¹ is perhaps best performed through the cricothyroid membrane. *Figure 3* shows a transtracheal aspiration being performed on a patient. The polyethylene tube has been inserted through the needle into the trachea. The needle has been withdrawn and the specimen is now being obtained by the use of suction and a Luken's trap.

A second important consideration for the clinician attempting to document the presence of anaerobes in pulmonary infection is proper transport of the specimen. Since anaerobes in

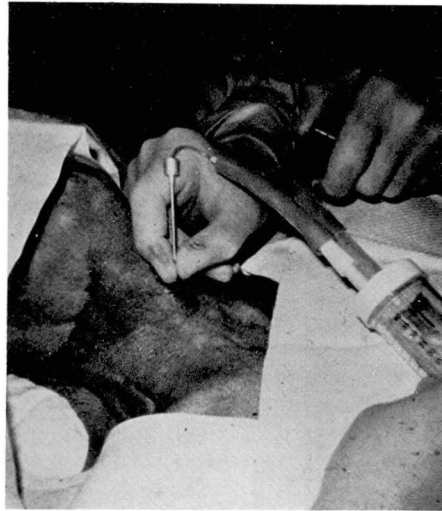


Fig. 3. Photograph showing transtracheal aspiration.

such specimens will die after relatively brief exposure to air, it is important that the material be placed under anaerobic conditions as soon as possible.

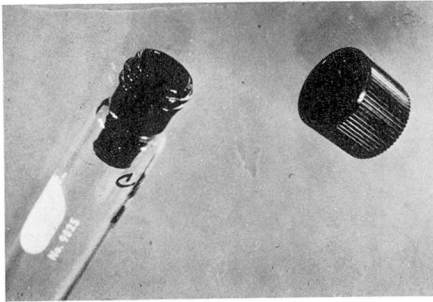


Fig. 4. Photograph of gassed-out tube with butyl rubber stopper.

Figure 4 illustrates a tube which has been gassed out with oxygen-free gas and stoppered with a butyl rubber stopper. The specimen is injected through the stopper into the anaerobic atmosphere and the tube is then capped. Another suitable and less expensive transport technique is shown in Figure 5. Plastic disposable syringes with tight-fitting plungers are suitable for transport purposes. All air is expelled from the syringe and needle, and the needle is then capped with a rubber stopper as for arterial blood gas measurements. With this transport setup, it is important that the specimen be received in the laboratory within 20 minutes.

We consider here the picture of anaerobic pleuropulmonary infection as illustrated by the first 100 cases that we have studied.² In Table 1, these cases are listed in terms of the type of pulmonary involvement and in two time periods. During the earlier time period, transtracheal aspiration was seldom used and empyema fluid was the most common source of material for establishing this diagnosis. Thus, the cases documented between 1969 and 1972, when transtracheal aspiration was used commonly, more accurately reflect the true picture of this

type of infection. With the use of transtracheal aspiration, diagnosis was possible even in the absence of empyema and cases could be diagnosed earlier—before development of abscesses or empyema. Table 2 shows the predisposing conditions in the 100 cases. The two major predisposing factors were aspiration, usually related to altered consciousness, and periodontal disease. A detailed breakdown of the culture

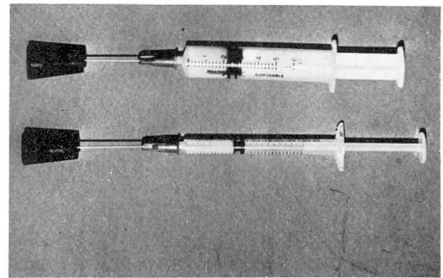


Fig. 5. Photograph of syringes containing exudate, with rubber stoppers on needles to preserve anaerobic conditions.

Table 1. Anaerobic pleuropulmonary disease; types of infection

	No. of cases	
	1958–1968	1969–1972
Pulmonary abscess without empyema	6	20
Pulmonary abscess with empyema	4	2
Necrotizing pneumonitis without empyema	7	10
Necrotizing pneumonitis with empyema	6	1
Empyema without abscess	20	8
Pneumonitis without empyema or abscess	0	15
Infected bronchogenic carcinoma cavity	1	0
Total	44	56
Total with empyema	30	11

Table 2. Anaerobic pleuropulmonary disease; predisposing conditions (100 cases)

	No. of cases
Aspiration	
Altered consciousness	63
Dysphagia	5
Intestinal obstruction	5
Preceding anaerobic infection	
Periodontitis	30
Intraabdominal	6
Local underlying conditions	
Bland pulmonary infarction	9
Bronchogenic carcinoma	7
Bronchiectasis	6
Systemic underlying condition	13
None apparent	15

sources utilized in the diagnosis of these cases is noted in *Table 3*. Distinctive clinical features which suggested the possibility of anaerobic pulmonary infection in these 100 cases were pulmonary parenchymal necrosis (70 cases), subacute or chronic presentation (57 cases), suspected aspiration (74 cases), and putrid discharge (53 cases). Only the putrid discharge is virtually specific, although one must keep in mind that odor may be imparted to sputum from anaerobic processes such as gingivitis in the mouth. Parenchymal necrosis is not specific for anaerobic infection, but is commonly seen in this condition. Subacute or chronic presentation of the illness, noted in almost two thirds of the cases, is unusual for bacterial pulmonary infections other than tuberculosis or mycotic infections.

The results of bacteriologic studies in these 100 cases are listed in *Table 4*. Anaerobic gram-negative bacilli were the most common anaerobes encountered and two anaerobic gram-negative bacilli (*Fusobacterium nucleatum* and

Bacteroides melaninogenicus) were particularly common. However, *Bacteroides fragilis* was also present in 21% of cases. *Figures 6 and 7* show the microscopic morphology of *F. nucleatum* and *B. melaninogenicus*, respectively. Anaerobic and microaerophilic streptococci and cocci were also seen with some frequency in these infections. Anaerobic gram-positive bacilli and clostridia were less commonly encountered. Potential aerobic pathogens were recovered from one third of these cases. Despite the presence of these aerobic pathogens, quantitative aspects of the bacteriology as well as distinctive clinical features indicated that these infections were anaerobic in origin. Symptoms were commonly present 2 to 4 weeks prior to therapy when abscess formation or empyema was part of the clinical picture (*Table 5*). Cases with only pneumonitis had a much shorter duration of symptoms prior to therapy and were undoubtedly treated before they had an opportunity to develop these complications. Note in *Table 5*, also, that fever persists for some time after therapy has been instituted, particularly in the case of empyema. In

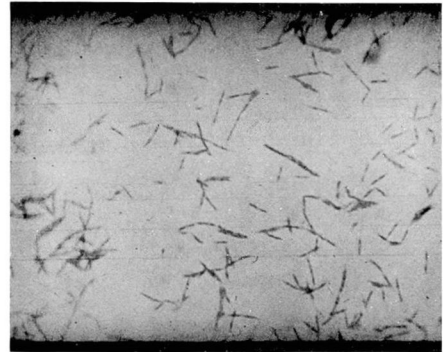Table 3. Anaerobic pleuropulmonary disease; culture sources (100 cases)

	No. of cases
Pleural fluid	40 (7)*
Percutaneous transtracheal aspirate	57 (2)
Percutaneous transthoracic aspirate	1
Thoracotomy specimen	5 (2)
Blood culture	2 (2)
Distant metastatic site	1
Autopsy material	2 (1)

* Two or more sources yielded anaerobes.

Table 4. Anaerobic pleuropulmonary disease; bacteriologic results (100 cases)

	Organism isolated No. of cases	Organism isolated in pure culture No. of cases
Anaerobic gram-negative bacilli		
<i>Fusobacterium nucleatum</i>	34	6
<i>F. necrophorum</i>	1	0
<i>Bacteroides melanogenicus</i>	31	1
<i>B. fragilis</i>	21	2
<i>B. oralis</i>	16	0
<i>B. pneumosintes</i>	1	0
Unidentified	10	0
Anaerobic gram-negative cocci		
<i>Veillonella</i>	7	0
Anaerobic gram-positive cocci		
Microaerophilic streptococcus	26	12
<i>Peptostreptococcus</i>	19	3
<i>Peptococcus</i>	15	0
Anaerobic gram-positive bacilli		
<i>Propionibacterium</i> species	9	0
<i>Eubacterium</i> species	5	0
<i>Bifidobacterium</i>	3	0
Unidentified catalase-negative nonsporulating	10	1
<i>Clostridium perfringens</i>	5	2
<i>Clostridium</i> species	2	0
Concurrent aerobic potential pathogens		
<i>Staphylococcus aureus</i>	9	0
<i>Pseudomonas aeruginosa</i>	7	0
<i>Escherichia coli</i>	7	0
<i>Klebsiella-Enterobacter</i>	6	0
<i>Proteus</i> species	4	0
<i>Diplococcus pneumoniae</i>	4	0
<i>Haemophilus influenzae</i>	3	0
<i>Pseudomonas maltophilia</i>	1	0
<i>Eikenella corrodens</i>	1	0
Group A beta-hemolytic streptococcus	1	0
<i>Providencia</i>	1	0

**Fig. 6.** Photomicrograph of Gram-stain smear of a pure culture of *F. nucleatum*.

the latter case, this undoubtedly reflects inadequate early drainage. The mortality is generally low, except in the cases of necrotizing pneumonia where it was 25%.

We studied 26 cases of lung abscess. Criteria for inclusion as a case of lung abscess included a pulmonary cavity at least 2 cm in diameter on roentgenogram, availability of a pretreatment transtracheal aspirate for culture, and absence of any other potential cause of pulmonary cavitation (hematogenous infection, tuberculosis, nonbacterial disease). The location of the abscess by lateral chest roentgenogram is noted in *Figure 8*. Most of the abscesses occurred in dependent segments, either the posterior segments of the upper lobes or the superior segments of the lower lobes or other dependent lower lobe segments. Anaerobic organisms only were isolated from 16 cases; only two had aerobic isolates alone; in eight patients both anaerobic and aerobic organisms were recovered.

Our bacteriologic studies in 79 cases of empyema (excluding cases of post-operative empyema) also establish that this disease is primarily anaerobic in etiology. Only 17 cases (22%) yielded

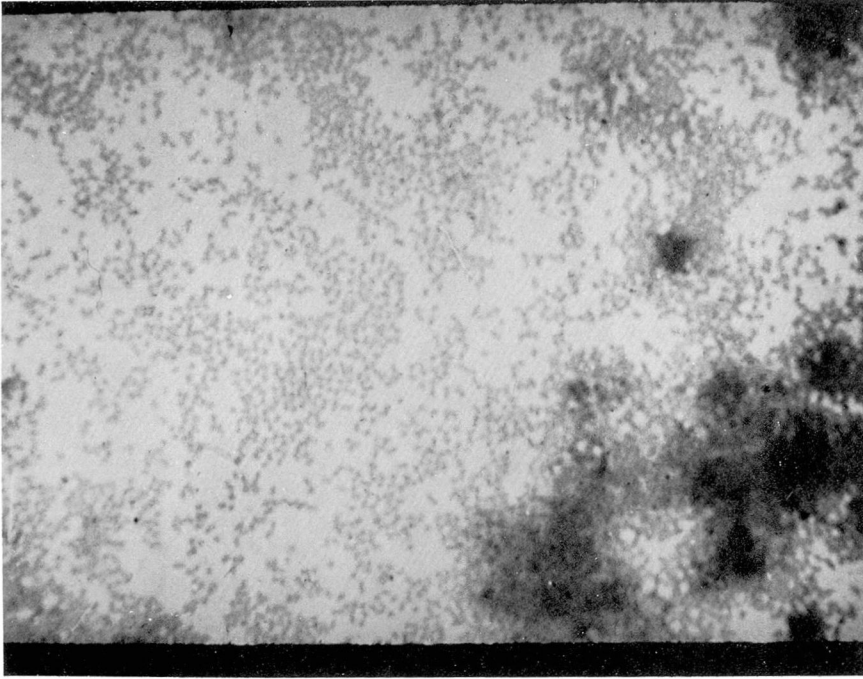


Fig. 7. Photomicrograph of Gram-stain smear of a pure culture of *B. melaninogenicus*.

Table 5. Anaerobic pleuropulmonary disease; clinical features (100 cases)

	Abscess without empyema	Necrotizing pneumonia and empyema	Empy- ema	Pneu- monitis only	Series
Cases (no.)	26	24	41	15	100
Duration of symptoms prior to therapy (wk)	4*	2	4	0.5	3.5
Duration of fever after therapy (wk)	1	1.8	4	0.3	2.5
Duration of infection after therapy (wk)	8	15	20	3	13
Mortality	1†	6	5	3	14

* Median duration in weeks.

† Total cases.

aerobic organisms exclusively; the remaining 62 cases (78%) yielded anaerobes, either with aerobes, 24 cases (30%), or without aerobes, 38 cases (48%).

We studied 70 patients with aspiration pneumonia, included only if they were observed either to aspirate or

have a predisposition to aspiration, and if a reliable pretreatment culture specimen was available (transtracheal aspirate, empyema fluid, or positive blood culture) in the presence of infection in a dependent pulmonary segment. Pneumonitis alone was present in 38 cases, whereas 20 had a definite

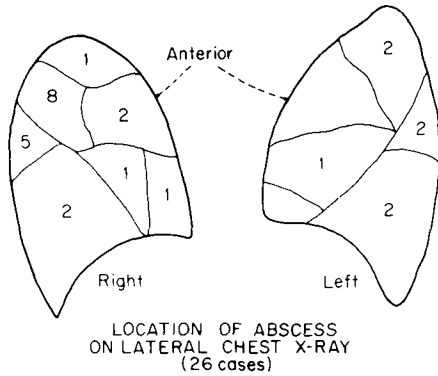


Fig. 8. Graphic representation of location of lung abscesses.

abscess and 12 had a necrotizing pneumonia. In these groups empyema was also present in five, two, and one patients, respectively. The major predisposing causes for aspiration were compromised consciousness in 67 cases (alcoholism, 23; cerebrovascular accident, 13; seizure disorder, 9; general anesthesia, 9; drug ingestion, 8; miscellaneous, 5) and dysphagia in nine cases (neurologic disorder, 7; esophageal stricture, 2). Transtracheal aspirates were the primary source for bacteriologic diagnoses (63 cases), although eight pleural fluids and four blood cultures yielded diagnostic results. The reasons that blood cultures are not often positive in patients with anaerobic pleuropulmonary disease are not clear. Only nine cases yielded aerobic pathogens only. Thirty-two of the 70 cases yielded anaerobes exclusively, whereas 29 patients had both groups of pathogens recovered. The specific bacteriologic findings are noted in Table 6. Anaerobic gram-negative bacilli and anaerobic cocci of various types again were the predominating organisms. Among the gram-negative anaerobic rods, once more *B. melaninogenicus* and *F. nucleatum* were the most com-

mon isolates. Anaerobic gram-positive bacilli were seen relatively uncommonly. A variety of aerobic or facultative bacteria was recovered as well. Of particular interest is the breakdown of cases noted in Table 7. Among the 38 patients whose aspiration pneumonia was acquired in the community, there were only three who yielded aerobes

Table 6. Aspiration pneumonia; bacteriology (70 cases)

	No. of cases
Anaerobic gram-negative bacilli	
<i>Bacteroides melaninogenicus</i>	27 (1)*
<i>B. fragilis</i>	10 (1)
<i>B. oralis</i>	9
<i>B. corrodens</i>	2
<i>B. pneumosintes</i>	1
<i>Fusobacterium nucleatum</i>	19
<i>F. necrophorum</i>	1
Unidentified	4 (1)
Anaerobic cocci	
Peptostreptococcus	23 (5)
Peptococcus	11 (1)
Microaerophilic streptococcus	9 (1)
Veillonella	4
Anaerobic gram-positive bacilli	
Eubacteria	6
Propionibacteria	6
Bifidobacteria	2
Clostridia	2
Aerobic gram-positive cocci	
<i>Streptococcus pneumoniae</i>	11 (2)
<i>Staphylococcus aureus</i>	11 (2)
Enterococcus	3
Group A beta-hemolytic streptococci	2
Aerobic gram-negative bacilli	
<i>Klebsiella</i> sp	8 (2)
<i>Pseudomonas aeruginosa</i>	7
<i>Escherichia coli</i>	6
<i>Enterobacter cloacae</i>	4
<i>Haemophilus influenzae</i>	2
<i>Citrobacter freundii</i>	1
<i>Pseudomonas maltophilia</i>	1

* Recovered in pure culture.

Table 7. Aspiration pneumonia; microbiology

	No. of cases	Anaerobes only	Aerobes only	Anaerobes and aerobes
Hospital acquired	32	7	6	19
Community acquired	38	25	3	10

alone, and 25 of the 38 had anaerobes to the exclusion of other types of organisms. The picture is distinctly different in hospital-acquired aspiration pneumonia. Among the 32 cases of this type in the study, there were six patients with aerobes alone and only seven with anaerobes alone, whereas 19 had mixtures of aerobes and anaerobes. This reflects the fact that hospitalized patients become colonized with certain opportunistic pathogens from the hospital environment, such as *S. aureus* and various facultative gram-negative bacilli. These organisms may then be aspirated, along with anaerobes, if aspiration occurs in the hospital setting. This is an important consideration in establishing appropriate treatment regimens.

One case further illustrates some of the points under discussion. A 53-year-old engineer with a history of diabetes mellitus and mild emphysema had what he thought was a chest cold. When this persisted for 3 weeks, he sought attention at our hospital. The admitting posteroanterior chest roentgenogram showed an infiltrate in the left mid-lung field (Fig. 9). This infiltrate was in the superior segment of the left lower lobe (Fig. 10). The house officer considered the possibility of an anaerobic infection in this patient on the basis of several kinds of evidence. First,

the man had diabetes, and diabetics are known to be more prone to anaerobic and certain other types of infection than the general population. Second, the infection was in a dependent seg-

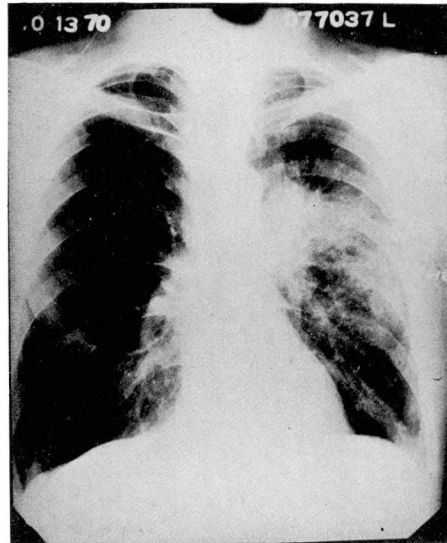


Fig. 9. Roentgenogram of the chest on admission showing infiltrate in left lung field.

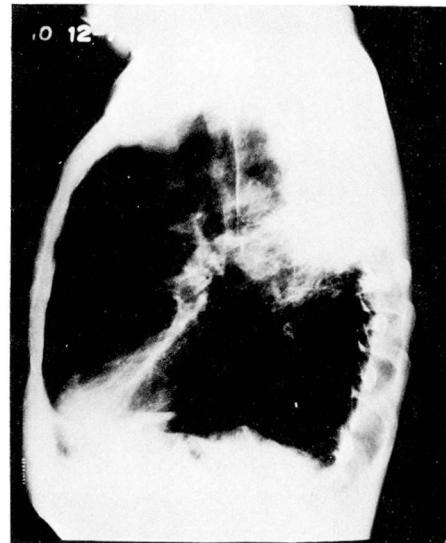


Fig. 10. Lateral roentgenogram of chest on day of admission revealing that infiltrate is in superior segment of left lower lobe.

ment suggesting the possibility of aspiration, although there was no history obtainable of a period of unconsciousness or frank aspiration. Third, the illness was of subacute onset which is one of the clues to anaerobic pulmonary infections cited previously. In addition, the patient was noted to have definite periodontal disease. Finally, he had a history of postnasal discharge which had a foul odor, presumably reflecting chronic sinusitis involving anaerobes. The house officer, being aware of the fact that conventional, coughed sputum culture would not be suitable to diagnose an anaerobic pulmonary infection, proceeded to do a transtracheal aspiration. Recognizing the need to place the specimen under anaerobic conditions promptly, he did this using a gassed-out tube. The specimen was

sent to the laboratory, and aerobic and anaerobic cultures were requested. The laboratory reported "no growth." The patient had not been treated in the interim, inasmuch as he was not particularly sick and the physician in charge of the case was anxious to establish the specific diagnosis. The case was then reviewed and the original posteroanterior chest roentgenogram was considered possibly to show a left hilar mass. Accordingly, a workup for possible carcinoma of the lung was undertaken. During the course of this workup, one day the patient manifested focal Jacksonian seizures on the left. Brain scan and arteriography demonstrated a cerebral mass lesion. At neurosurgical exploration, a large abscess containing 40 cc of foul-smelling pus was encountered and drained.

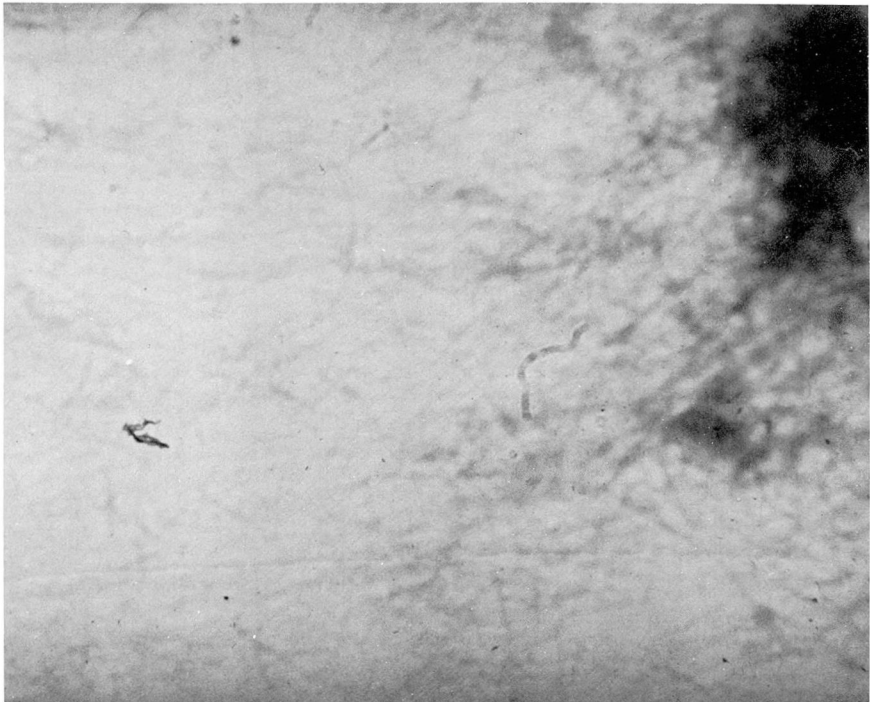


Fig. 11. Gram-stain smear of material from brain abscess.

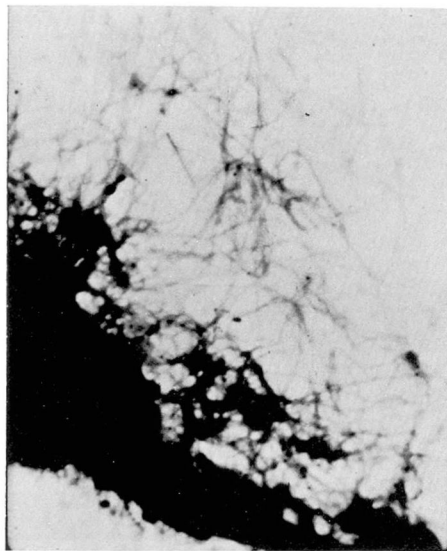


Fig. 12. Gram-stain smear of material obtained from repeat transtracheal aspiration.

Direct Gram stain of the material from this abscess showed thin, pale-staining filamentous rods which were gram-negative (*Fig. 11*). This was presumed to be *Fusobacterium* (and ultimately was grown out and confirmed as *F. nucleatum*). At this point, the transtracheal aspiration was repeated and similar organisms were noted on direct Gram stain of this material (*Fig. 12*). This case emphasizes the importance of the Gram stain. Had it been done originally it would have been apparent that the original culture report was in

error, and that the technique in the laboratory was inadequate for growth of anaerobes at that time.

Summary and conclusions

Anaerobic bacteria, alone or with aerobic organisms, are commonly involved in the pathogenesis of aspiration pneumonia, primary lung abscess, and pleural empyema. Failure to collect, transport, and culture infectious materials by appropriate anaerobic techniques may forfeit the diagnosis of anaerobic pleuropulmonary infection. Transtracheal aspiration of bronchial secretions circumvents contamination of bronchopulmonary exudates by members of the indigenous oropharyngeal flora. It is imperative that a Gram-stained smear of each specimen be obtained, so that the efficiency and accuracy of culture results can be compared with the microscopic examination, and so that the physician immediately has a preliminary idea of the nature of the pleuropulmonary pathogens.

References

1. Bartlett JG, Rosenblatt JE, Finegold SM: Percutaneous transtracheal aspiration in the diagnosis of anaerobic pulmonary infection. *Ann Intern Med* 79: 535-540, 1973.
2. Bartlett JG, Finegold SM: Anaerobic pleuropulmonary infections. *Medicine* 51: 413-450, 1972.