

Anaerobic infections of the abdomen and pelvis

Sydney M. Finegold, M.D.*

Recently, there has been an increased awareness of the role of anaerobes in clinical infections. The purpose of this paper is to emphasize the frequency with which anaerobes are involved in infections of the abdomen and pelvis, and to illustrate some of the clinical problems.

First, I would like to present data from an excellent study by Gorbach et al.¹ Forty-six cases were studied; predisposing conditions included abdominal trauma (22 patients), carcinoma (7 patients), postoperative infections (7 patients), perforated appendix (4 patients), hepatic cirrhosis (3 patients), and peritoneal dialysis (3 patients). Thirty-two patients had intraabdominal abscesses, 10 had generalized peritonitis, and four had miscellaneous conditions (retroperitoneal and prostatic abscesses, infected aortic graft). Of 43 specimens of purulent abdominal material studied, 33 yielded both anaerobes and aerobes, seven grew anaerobes alone and in three, only aerobes were isolated. There was an average of five organisms per specimen (range 1 to 13), with a ratio of three anaerobes to two aerobes. Each organism had to be obtained in pure culture in order to be accurately identified, a time-consuming process with anaerobes, which often grow slowly.

The specific organisms are listed in *Table 1*. Gram-negative nonsporeforming anaerobic rods predominated, reflecting the fact that *Bacteroides*

* *Department of Medicine, Wadsworth Veterans Administration Hospital and the University of California Medical Center, Los Angeles, California.*

Table 1. Anaerobic microorganisms isolated from 43 intra-abdominal wounds

Gram-negative nonsporing rods		
Bacteroides		36
<i>B. fragilis</i>	28	
<i>B. melaninogenicus</i>	4	
<i>B. clostridiiformis</i>	2	
<i>B. biacutus</i>	1	
<i>Bacteroides</i> species	1	
Fusobacterium		6
<i>F. varium</i>	1	
<i>F. necrophorum</i>	1	
<i>Fusobacterium</i> species	4	
Cocci		
Peptostreptococci		11
Peptococcus		3
<i>P. magnus</i>	2	
<i>P. prevotii</i>	1	
Veillonella		1
Gram-positive nonsporing rods		
Eubacterium		10
<i>E. lentum</i>	6	
<i>E. filamentosum</i>	2	
<i>E. multiforme</i>	1	
<i>E. limosum</i>	1	
Propionibacterium		2
<i>Lactobacillus catenaforme</i>		2
Bifidobacterium		1
Clostridia		31
<i>C. ramosum</i>	3	
<i>C. perfringens</i>	3	
<i>C. butyricum</i>	2	
<i>C. bif fermentans</i>	2	
<i>C. sporogenes</i>	2	
<i>C. innocuum</i>	2	
<i>C. sordellii</i>	1	
<i>C. fallax</i>	1	
<i>C. beijerinckii</i>	1	
<i>C. barati</i>	1	
<i>C. difficile</i>	1	
<i>C. ghoni</i>	1	
<i>C. sphenoides</i>	1	
<i>Clostridium</i> species	10	

fragilis is the most prevalent member of the normal flora of the bowel. This organism was isolated 28 times along with small numbers of other gram-negative nonsporeforming anaerobes of the genus *Bacteroides* and of the genus

Fusobacterium. Of special significance is the fact that *B. fragilis* is much more resistant to antimicrobial agents than other anaerobic bacteria. *Fusobacterium varium*, isolated only one time in this study, may also be resistant, although not typically to the extent that *B. fragilis* is. However, one third of strains of *F. varium* that we have studied have been resistant to clindamycin, an otherwise excellent agent for anaerobic infections. There were a smaller number of anaerobic cocci of various types and of gram-positive nonsporeforming anaerobic rods. Some members of the genus *Eubacterium* may also be resistant to clindamycin. There were a large number of clostridia, a total of 31 isolates. *Clostridium ramosum*, relatively commonly involved in anaerobic infections of all types, was seen here as frequently as *Clostridium perfringens*. *C. ramosum* is the third member of the anaerobic group which tends to be resistant to antimicrobial agents including, to some extent, clindamycin and even penicillin. Ten percent to 15% of strains of these other clostridia species may also be resistant to clindamycin as well. The aerobic and facultative forms isolated in this series are shown in *Table 2*. *Esche-*

Table 2. Aerobic and facultative microorganisms isolated from 46 intra-abdominal infections

<i>Escherichia coli</i>	28
<i>Staphylococcus epidermidis</i>	15
Proteus	10
Klebsiella	9
Pseudomonas	8
Enterobacter	8
Candida	4
Streptococcus	3
Enterococcus	2
<i>Staphylococcus aureus</i>	1

richia coli predominated as expected. A number of patients had organisms not commonly found in significant numbers among the normal bowel flora such as *Klebsiella*, *Pseudomonas*, and *Staphylococcus aureus*, reflecting, most likely, some prior antimicrobial therapy or hospital experience or both.

There were 13 instances in which bacteremia was present. In 11 of these, anaerobes were isolated in pure culture, and in the other two there was a mixture of anaerobes and aerobes. The specific organisms responsible for bacteremia in this series of intraabdominal infections are shown in *Table 3*. Again, *B. fragilis* predominated. Also present were *Bacteroides melaninogenicus*, several clostridia, a fusiform, and *Klebsiella* isolated in two cases in mixed culture along with anaerobes. Two clostridia were resistant to clindamycin, one of them *C. perfringens*, although *C. perfringens* is usually susceptible.

Other categories of intraabdominal infection

Figure 1 depicts a subdiaphragmatic abscess shown by a combined liver-lung scan; there is an abnormally large space between the liver and the lung. Most of these abscesses are secondary to pathology in the bowel, and therefore anaerobes are very commonly involved in subphrenic abscess. The complex bacteriology that may be encountered in this type of process and in intraabdominal infections in general is illustrated in *Table 4*. Four aerobic organisms were isolated (the diphtheroids probably representing a contaminant) together with a yeast and then a total of nine different anaerobic organisms. This type of specimen is a large project for the clinical laboratory.

Table 3. Microorganisms in 13 cases of septicemia associated with intra-abdominal infections*

<i>Bacteroides fragilis</i>	8
<i>B. melaninogenicus</i>	1
<i>Clostridium perfringens</i>	2
<i>C. tertium</i>	1
<i>C. difficile</i>	1
<i>Fusobacterium nucleatum</i>	1
<i>Klebsiella</i>	2

* Two patients had *B. fragilis* and *Klebsiella*; one patient had 2 strains of clostridia.

Treatment must be based on clinical acumen, with the information derived from a direct Gram stain, and with recognition that it will take time to get definitive bacteriologic results. *Figure 2* shows an appendiceal abscess indenting the cecum outlined by a barium enema. *Figure 3* represents a case of diverticulitis as shown by barium enema. Although some diverticula are filled, one had previously ruptured and barium extravasated into a large abscess adjacent to the colon. This process, as well as appendiceal infections, involves anaerobic bacteria essentially 100% of the time. Failure to recover anaerobes from this type of infection should prompt careful reevaluation of techniques. The laboratory may be at fault, but, more often, the specimen has not been transported properly (exposure to air during transport may kill anaerobes).

Figure 4 is an example of postoperative bacterial synergistic gangrene which occurs after various types of surgery, but is most common after abdominal surgery (particularly bowel surgery) especially when retention sutures are required, as in this case. The clinical picture is typical. Severe pain is associated with this process. In the classic case, there are three zones: a central ne-

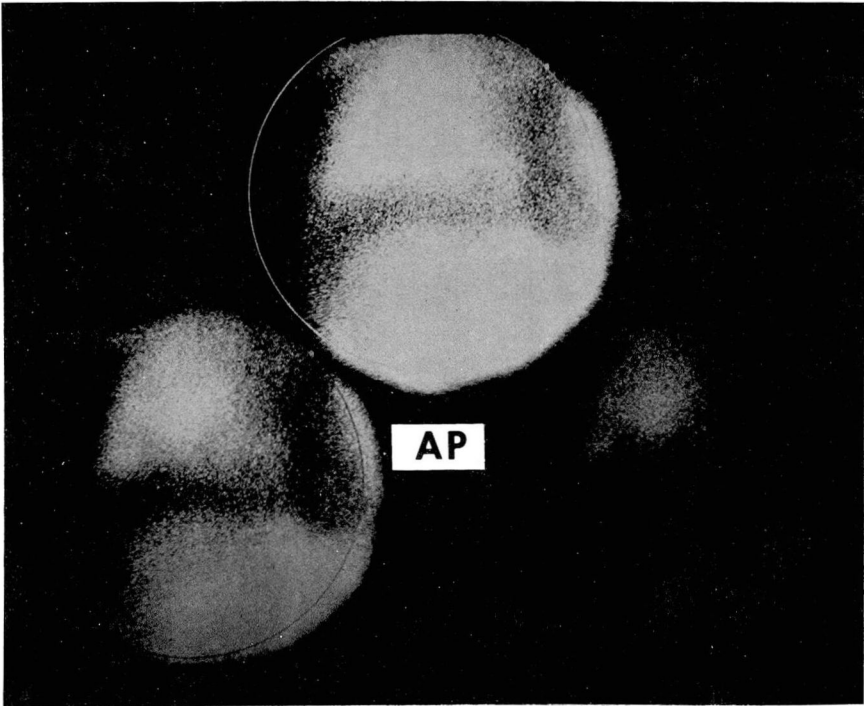


Fig. 1. Combined liver-lung scan showing an abnormally large area of decreased perfusion between the liver and the lung. This proved to be a subphrenic abscess.

Table 4. Subphrenic abscess; organisms isolated in one case*

Aerobes	
	<i>Escherichia coli</i>
	<i>Klebsiella</i> species
	<i>Proteus mirabilis</i>
	Diphtheroids
Anaerobes	
	<i>Bacteroides fragilis</i>
	Peptostreptococcus
	Peptococcus
	<i>Eubacterium multiforme</i>
	<i>E. lentum</i>
	<i>Clostridium bifermentans</i>
	<i>C. barati</i>
	<i>C. innocuum</i>
	Veillonella
Fungi	
	<i>Candida albicans</i>

* From case with lung-liver scan shown in Figure 1.

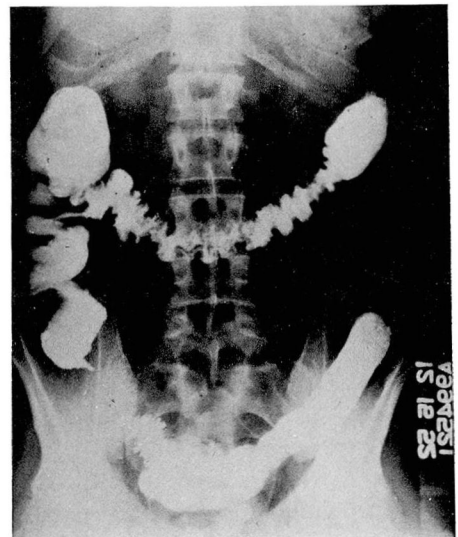


Fig. 2. Barium enema showing extrinsic compression of the cecum secondary to an appendiceal abscess.

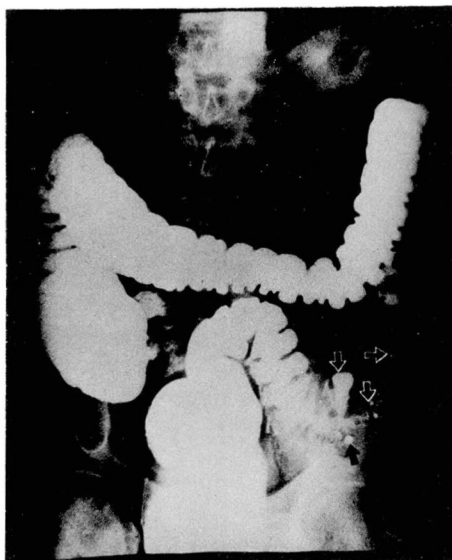


Fig. 3. Diverticulitis of the sigmoid colon with perforation. The small arrows point to diverticula. The large arrow points to barium extravasating through a perforated diverticulum into a large pericolic abscess.

crotic zone surrounded by a purplish zone of discoloration, and outside of that a lighter red zone of inflammation. If material is cultured from the central necrotic area, even where there is frank pus, recovery of *S. aureus* only is likely. However, if the active margin of the inflammatory area is cultured, microaerophilic streptococci in addition to *S. aureus* would be recovered. Those are the classic organisms that are recovered. On occasion, instead of *S. aureus*, a gram-negative rod such as *Proteus* or *Klebsiella* may be recovered, and in lieu of a microaerophilic streptococcus, an anaerobic streptococcus. This is a mixed infection and the synergism is significant. If this patient were treated with methicillin alone, on the assumption that the staphylococcus isolated from the center of the necrotic

lesion was the true infecting organism, chances are that the patient would not respond or would respond in suboptimal fashion. However, if therapy was extended to also cover the microaerophilic streptococcus (often resistant to an agent such as methicillin), the response would be good provided surgical drainage and excision of necrotic tissue were also carried out. These are virulent infections and too often go on, as this one did, to complete wound dehiscence (*Fig. 5*).²

Figure 6 depicts a lateral liver scan with a posterior defect due to a liver abscess in a 13-year-old girl who had a routine appendectomy 1 month earlier. One week postoperatively, low grade fever developed which persisted and became more pronounced. She had anorexia, lost weight and was finally readmitted to the hospital. Blood cultures yielded *B. fragilis* on two occa-

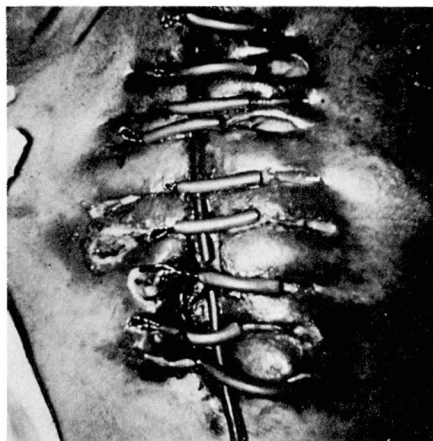


Fig. 4. Photograph of postoperative abdominal wound showing edema of the edges of the wound and gangrenous changes of the skin around stainless steel sutures. An irrigation catheter is in place. (Reproduced with permission of author. deJongh DS, Smith JP, Thoma GW: Postoperative synergistic gangrene. *JAMA* 200: 557-559, 1967.)

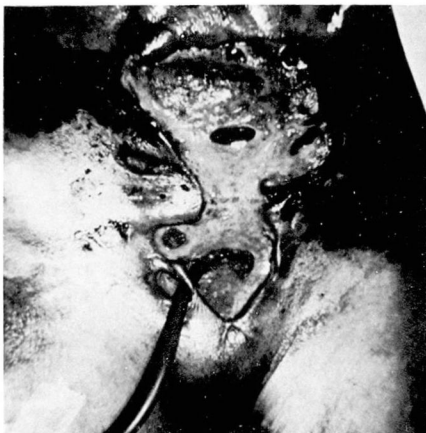

Fig. 5. Later photograph of abdominal wound showing dehiscence, four enterocutaneous fistulae, and a large vesicocutaneous fistula. (Reproduced with permission of author. de Jongh DS, Smith JP, Thoma GW: Postoperative synergistic gangrene. JAMA 200; 557-559, 1967.)

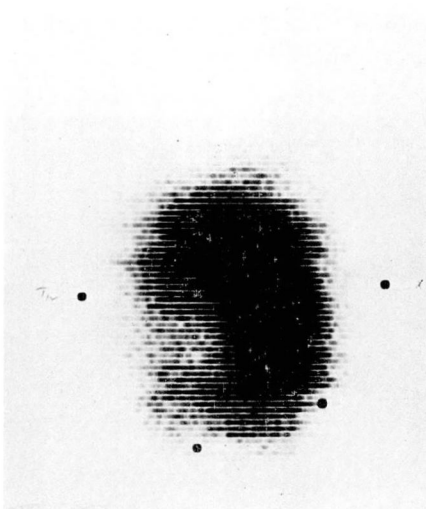

Fig. 6. Lateral liver scan showing a rather circumscribed, rounded area of decreased radiolucency in the posterior-inferior aspect of the right lobe of the liver. This was proved to be caused by a liver abscess.

sions. Her anteroposterior liver scan was entirely normal. The abscess was drained and *B. fragilis* was recovered in pure culture from the pus.

Our experiences with liver abscess at the Wadsworth Veterans Hospital and U.C.L.A. over a 10-year period include a total of 47 cases.³ In 19 cases, only aerobes were isolated, in six there were mixtures of aerobes and anaerobes, and in 15, only anaerobes were isolated (Table 5). Anaerobes were isolated from 21 of 45 cases from which data were available. If one subtracts the five cases which yielded no growth, at least two of which showed organisms on direct smear (and therefore were presumably anaerobic), this would mean that over half of our cases of pyogenic liver abscess involved anaerobes. Among the 19 cases which showed only aerobes, several grew only small numbers of organisms such as *Staphylococcus epidermidis*, *Micrococcus* or diphtheroids which undoubtedly represented contamination. This was a retrospective study and only a portion of the cultures were performed in our own laboratory. It is not known if all specimens actually were submitted for anaerobic culture or how effectively those that were submitted for anaerobic culture were studied. There was a significant problem with regard to recovering anaerobes in our clinical laboratory for

Table 5. Pyogenic liver abscess (Wadsworth Veterans Hospital, U.C.L.A., 1960-1970)

	No. of cases
Aerobes	19
Mixed aerobes and anaerobes	6 (2)
Anaerobes	15 (2)
No growth	5
No culture taken	1
Chart not located	1
Total	47 (4)

a period of time. If a prospective study were done with proper culture of all specimens, it is likely that at least two thirds of pyogenic liver abscesses would be shown to be due to anaerobic organisms.

In addition to the 21 cases of anaerobic pyogenic liver abscess noted above, there were four other cases from other hospitals that we had an opportunity to see and culture. Thus, a total of 25 cases of anaerobic liver abscess were analyzed. The clinical picture was not really different from pyogenic liver abscess in general. The predisposing conditions, such as underlying bowel or gall-bladder disease, were what one expects to see. The general and localizing symptomatology was not unique; neither were the physical nor laboratory findings. This coincides with the idea that pyogenic liver abscess is frequently an anaerobic process, and one should not expect a different clinical or laboratory picture from that described in the past for liver abscess, which has been thought to be mostly due to aerobes. General bacteriologic data for these 25 cases are noted in *Table 6*. Twelve cases yielded a single anaerobe while 13 had anaerobes in mixed culture. Five of the latter had only anaerobes (two or more), but no aerobes or facultatives; the other eight had mixtures of anaerobes and aerobes. The specific anaerobes recovered were predominantly cocci, either anaerobic cocci, streptococci, or microaerophilic streptococci. *B. fragilis*, the resistant form that has been discussed, was seen with a certain frequency. There were also other gram-negative anaerobic rods, including *Fusobacterium nucleatum* and one Actinomyces.

Table 6. Anaerobic pyogenic liver abscess; 25 cases (1960-1970)

Bacteriological data, general	Patients
Single anaerobe	12
Mixed culture	13
Mixed—anaerobes only	5
Mixed—anaerobes and aerobes	8

Table 7 is taken from a 1927 report⁴ and deals with puerperal infection of various types (e.g., endometritis, pelvic cellulitis, peritonitis, associated bacteremia). The third column shows the number of aerobic bacteria isolated from these various types of puerperal infection and column 4, the number of anaerobic streptococci. One can readily see that anaerobic streptococci outnumber the aerobic organisms in this series. With modern techniques we would expect to find, in addition, a certain number of anaerobic gram-negative bacilli and of clostridia. *Table 8* is a list of various female genital tract infections that may involve anaerobic bacteria. Anaerobes are very commonly involved, not only in puerperal infection, but also in postabortal sepsis, in postoperative obstetric and gynecologic infections, and in a variety of other infections. The specific organisms involved are listed in *Table 9*. In contrast to the intraabdominal infections in which gram-negative anaerobic bacilli were the dominant organisms and *B. fragilis* stood out particularly; in female genital tract infections the anaerobic cocci are much more common. This reflects the fact that in this site the anaerobic cocci are much more commonly found as indigenous flora, whereas in the bowel, the Bacteroides group, and *B. fragilis* in particular, is dominant. In female genital tract

Table 7. Types of puerperal infection*

No. of admissions 7-1-24 to 9-1-26	No. of deliveries		No. of cases of puerperal infection			No. of deaths
	2194	1913	45			10
Type of infection	No. of cases	Aerobic bacteria	Anaerobic streptococci	Mixed bacteria	Negative cultures	Mortality
Acute endometritis	42	11	27	3	1	0
Pelvic cellulitis	11	4	6	1	0	0
Peritonitis	7	1	4	2	0	6
Pelvic abscess	3	1	1	1	0	0
Pelvic thrombophlebitis	9	0	6	0	3	3
Bacteremia	15	4	10	1	0	1

* Data obtained from Schwarz OH, Dieckmann WJ: Puerperal infection due to anaerobic streptococci. Am J Obstet Gynecol 13: 467-485, 1927.

Table 8. Anaerobic infections of the female genital tract

Endometritis, pyometra
Myometritis
Parametritis
Pelvic cellulitis, abscess
Pelvic thrombophlebitis
Peritonitis, intraabdominal abscess
Bacteremia, with or without shock or intravascular hemolysis
Metastatic infection—particularly of lung, liver, brain, heart valves, kidney
Wound infection or abscess
Vulvar abscess
Bartholinitis, Bartholin abscess
Skenitis, Skene's abscess
Paraclitoroidal abscess
Vaginitis, abscess of vaginal wall, paravaginal abscess
Salpingitis, tubal abscess
Ovarian or tubo-ovarian abscess
Abscesses of adjacent parts—groin, perirectal or ischioanal areas, paraurethral, leg, abdominal wall
Chorioamnionitis
Fetal emphysema
Intrauterine or neonatal pneumonia, sepsis

infections, one encounters Peptostreptococcus, Peptococcus, microaerophilic cocci and some gram-negative cocci more commonly than other organisms.

However, *B. fragilis* and other gram-negative anaerobic rods are seen as well. Fortunately, *C. perfringens* is not commonly encountered as it may produce devastating infection. Occasion-

Table 9. Organisms involved in female genital tract infections

Anaerobes
Peptostreptococcus
Peptococcus
Microaerophilic gram-positive cocci
Veillonella
<i>Bacteroides fragilis</i>
<i>Bacteroides melaninogenicus</i>
Other Bacteroides species
<i>Fusobacterium necrophorum</i>
Other Fusobacterium species
<i>Clostridium perfringens</i>
<i>Actinomyces israelii</i>
Other organisms
<i>Escherichia coli</i>
Other Enterobacteriaceae
Group A beta-hemolytic streptococci
Enterococci
Other streptococci
<i>Staphylococcus aureus</i>
Gonococcus
<i>Haemophilus (Corynebacterium) vaginalis</i>
Proteus
Pseudomonas

ally, other clostridia and nonspore-forming gram-positive anaerobes may be recovered. Among the aerobic organisms, *E. coli* and group A streptococci dominate, but others may be seen in addition.

As stated before, anaerobic bacteria prevalent as indigenous flora on mucosal surfaces become involved in infections of the bowel and the female genital tract. This is true all through the body and the number of these organisms present as normal flora is quite impressive. In the bowel, anaerobes outnumber aerobic or facultative forms a thousand to one. *E. coli*, which we commonly think of in terms of bowel organisms, constitutes only one tenth of 1% of the total bowel flora. The same thing is true to a lesser extent in other areas. In the female genital tract, anaerobes outnumber facultative or aerobic forms ten to one; this is a common ratio in other sites in the body. So, if one is to obtain a specimen to document the bacteriology of an infectious process, particularly an anaerobic infection, one must avoid the

normal flora. In the case of intraabdominal infection, this is usually not too difficult a problem unless there is an open communication between the bowel and the peritoneal cavity or abscess. In the female genital tract, it may be much more of a problem. An interesting approach to this problem was reported by Guilbeau and Schaub⁵ (Fig. 7). It is important to position the patient carefully and get good exposure by proper use of a vaginal speculum. The vagina and cervical os are decontaminated with an iodophor. The authors used a sterile steel instrument over which was stretched a sterile rubber finger cot that was tied in place. The instrument was inserted into the endocervical canal; then a stylet was pushed forward to perforate the finger cot which would then retract. One could then utilize plastic tubing attached to a syringe or a swab to obtain contents from the endometrial cavity.

Another important consideration for the clinician, in order to obtain reliable bacteriologic results in anaerobic infections, is to transport the specimen

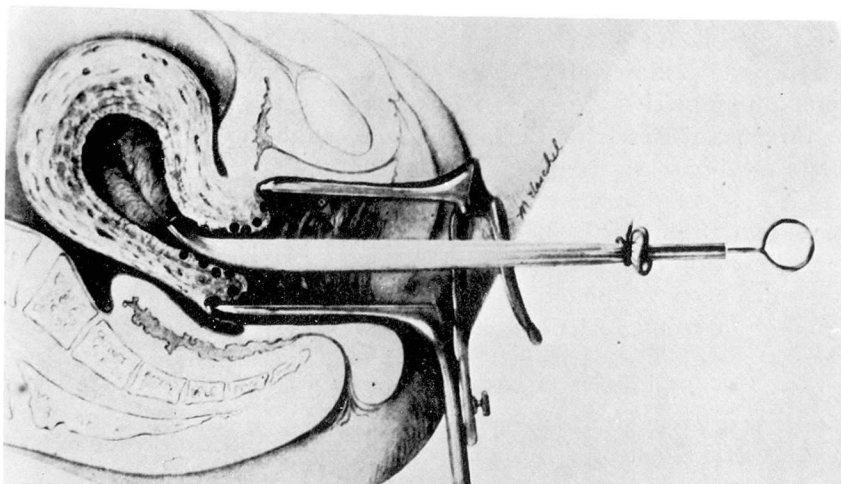


Fig. 7. Technique for obtaining endometrial culture relatively free of normal flora. See text for description. (From Guilbeau JA Jr, Schaub IG: Uterine culture technique. A simple method for avoiding contamination by cervical and vaginal flora. *Am J Obstet Gynecol* 58: 407-410, 1949.)

to the laboratory in such a way as to avoid loss of organisms. When anaerobes first leave the body in various discharges, they are quite sensitive to air exposure. It is therefore extremely important that the specimen be placed under anaerobic conditions as promptly as possible. One useful technique involves the use of a tube which has been gassed out with oxygen-free gas and stoppered with a butyl rubber stopper, butyl rubber being impervious to gas. The specimen is obtained by syringe, then all air is expelled from the syringe and needle and the contents of the syringe are discharged into the gassed-out tube. Another simpler and much less expensive approach is to transport the specimen directly to the laboratory in the syringe. The needle is capped with a rubber stopper. Specimens in syringes must be set up in anaerobic culture within 20 to 30 minutes. If it is absolutely necessary to use a swab, which it is on occasion, then it is best to use a swab which has been put up in an anaerobic atmosphere. The swab should be made as wet as possible with the specimen and then put into a tube of semi-solid Carey and Blair transport medium, also in an anaerobic atmosphere.

The two major aspects of therapy for these infections are medical and surgical. The latter is the more important of the two. Drainage of collections of pus and excision of necrotic tissue, both of which are very commonly encountered in anaerobic infections, are crucial to the patient's survival. The second aspect is antimicrobial therapy. There are five drugs or groups of drugs which are useful. Penicillin is active against most anaerobes with the exception of *B. fragilis*. However, *B. fra-*

gilis is the anaerobe most commonly encountered in clinical infections. Carbenicillin, by virtue of the fact that high blood levels may be achieved safely, may encompass in its spectrum most strains of *B. fragilis*. Tetracyclines are no longer satisfactory since a significant percentage of anaerobes of all types are now resistant. Doxycycline and minocycline are more active, but there are forms resistant to those agents. Chloramphenicol is active against all anaerobes and I would regard it as the single most dependable agent for treatment of anaerobic infections. Chloramphenicol is the drug of choice in a critically ill patient with an anaerobic infection wherein the bacteriologic data are not yet available. Clindamycin is an excellent drug, active against most anaerobes. One third of strains of *F. varium*, an uncommon pathogen, are resistant to clindamycin, as are 10% to 15% of strains of a number of species of *Clostridium* other than *C. perfringens*. Therefore, in serious intraabdominal and female genital infections, where clostridia are relatively commonly encountered, penicillin would be needed to supplement clindamycin to cover that group of organisms, or one should use another agent such as chloramphenicol. Metronidazole (Flagyl) is currently an experimental agent in anaerobic infection, but looks quite good in vitro. Preliminary clinical experiences are encouraging. It has the advantage of being remarkably bactericidal, much more so than even the penicillins.

Summary and conclusions

Proper collection and culture techniques reveal that anaerobes are the

most common pathogens associated with intraabdominal and pelvic infections, including peritonitis, subphrenic and other loculated abscesses, hepatic abscess, and most puerperal and gynecologic infections. Presumptive antibiotic therapy, based on clinical awareness and the Gram-stain, should include coverage for these anaerobes, as well as for the more easily recognized aerobic pathogens often present. Surgical therapy, including drainage of abscesses and excision of necrotic tissue, in addition to selection of proper antibiotics, is usually the key to successful therapy.

References

1. Gorbach SL, Thadepalli H, Norsen J: Anaerobic microorganisms in intraabdominal infections, *in* *Anaerobic Bacteria: Role in Disease*. Balows A, DeHaan RM, Dowell VR Jr, Guze LB, eds. Springfield, Illinois, Charles C Thomas, 1974, pp 399-407.
2. deJongh DS, Smith JP, Thoma GW: Post-operative synergistic gangrene. *JAMA* **200**: 557-559, 1967.
3. Sabbaj J, Sutter VL, Finegold SM: Anaerobic pyogenic liver abscess. *Ann Intern Med* **77**: 627-638, 1972.
4. Schwarz OH, Dieckmann WJ: Puerperal infection due to anaerobic streptococci. *Am J Obstet Gynecol* **13**: 467-485, 1927.
5. Guilbeau JA Jr, Schaub IG: Uterine culture technique. A simple method for avoiding contamination by cervical and vaginal flora. *Am J Obstet Gynecol* **58**: 407-410, 1949.