

# Primary lung abscess

## *Analysis of 66 cases*

K. V. Gopalakrishna, M.D.\*  
Phillip I. Lerner, M.D.\*

Resurgence of interest in defining the specific pathogens involved in anaerobic infections has prompted a reexamination of many previously accepted concepts. Primary lung abscess has long been recognized as a prime example of a mixed anaerobic infection, although little attention has been paid to the specific bacterial components of this syndrome. With modern techniques, investigators have now carefully identified the specific anaerobic pathogens most often associated with primary lung abscess.<sup>1</sup> Not surprisingly, the role of these pathogens, and indeed the need for identifying them, has caused some confusion and disagreement. We reviewed a series of cases managed for the most part without benefit of specific anaerobic pathogen identification, but managed nonetheless according to established principles of dealing with anaerobic infections.

### **Materials and methods**

The charts of all patients with a final diagnosis of lung abscess seen at the Veterans Administration Hospital in Cleveland from January 1966 through June 1974 were reviewed. With few exceptions, all patients were actively evaluated by members of the Infectious Disease Section. Patients with tuberculous and mycotic cavities, infected pleural cysts, cavitating tumors, septic or bland pulmonary infarcts, or specific cavitating

\* *Infectious Disease Section, Veterans Administration Hospital, Cleveland, Ohio.*

pneumonias (e.g., staphylococcal and Friedlander's) were excluded. Patients with putrid or anaerobic empyemas, most often secondary to underlying or previous lung abscess, were also excluded because surgical drainage of the chest is mandatory and the most important aspect of therapy when that complication is present. The diagnosis of primary lung abscess was established on the basis of (1) an appropriate clinical history including circumstances favoring pulmonary aspiration, (2) symptoms of acute or chronic pulmonary infection, (3) roentgenographic evidence of a parenchymal lesion with an air-fluid level, and (4) characteristic Gram's stain and culture from expectorated sputum. A few patients also had sputum samples obtained by transtracheal aspiration, and occasionally the diagnosis was based on surgical or autopsy findings. There were 66 episodes among 64 patients, two patients experiencing two separate and distinct episodes of lung abscess. All patients were treated to insure adequate hydration. Pulmonary

toilet (tracheal suctioning, intermittent positive pressure breathing, postural positioning with clapping, and other appropriate measures) was given high priority in each case. Bronchoscopy was performed at the discretion of the attending physician. Chest roentgenograms were obtained at frequent intervals to evaluate results of therapy. Roentgenographic improvement included disappearance of associated pneumonic infiltrates in addition to reduction in the size of the cavity and the level of the contained fluid. Clinical improvement was assessed by decreased production of or a favorable change in the abnormal sputum, increased appetite and sense of well-being, weight gain, defervescence, correction of anemia and, in certain cases, return of the white blood cell count to normal.

All the patients were men, as might be expected among a veterans' population. Ages ranged from 20 to 80 years; 56 of the 64 patients were in their fifth and sixth decades. *Table 1* lists the incidence of recognized pathogenetic factors in the group. Aspiration of oral contents during periods of altered consciousness was suspected in most patients. Forty-eight (75%) admitted to a history of an excessive intake of alcohol. Nine of 15 patients with a history of seizures experienced an attack from 1 week to 3 months prior to the onset of respiratory symptoms. Forty-three patients (67%) had severe periodontitis or gingivitis. Three patients had had recent dental extractions, but 10 were edentulous. The records failed to indicate how many of these 10 patients used dentures. In three patients, lung abscess occurred in the postoperative period, following general anesthesia. Other underlying

**Table 1.** Predisposing factors in 64 patients with primary lung abscess

	No. of patients	%
Alcoholism	48	75
Poor oral hygiene	43	67
Seizures*	15	23
Edentulous	10	15
Chronic obstructive pulmonary disease	10	15
Recent dental extraction	3	5
Anesthesia	3	5
"Stroke"	1	1.5
Carcinoma of larynx	1	1.5
No known factors	4	6

\* Nine of 15 within 1 week to 3 months prior to symptoms.

**Table 2.** Signs and symptoms in 66 episodes of primary lung abscess

	No. of patients	%
Cough, productive of purulent sputum	48	73
Foul-smelling sputum	29	42
Chest pain	37	56
Febrile on admission	51	77
Weight loss	25	38
Hemoptysis	17	26
Leukocytosis ( $> 12,000/\text{mm}^3$ )	40	60
Anemia (hematocrit $< 35\%$ )	25	38
Abnormal liver function tests*	37	56
Pleural fluid	4	6

\* Bilirubin, SGOT, alkaline phosphatase.

conditions included chronic obstructive lung disease in 10 patients, and an acute cerebrovascular accident and carcinoma of the larynx in one patient each.

Productive cough was noted in 48 patients (73%) and foul-smelling sputum was present in 29 (42%) of these (Table 2). Thirty-one patients had a history of chills and fever, and in an additional 20 patients, fever was also present on admission to the hospital. The duration of symptoms ranged from less than 2 weeks to 2 months.

Physical findings on examination of the chest in most instances suggested only a diagnosis of pneumonia. In 27 patients, there were no significant auscultatory findings. Pleural fluid was detected in only 4 patients. Leukocytosis was present in 40 patients (60%) and in 37 (56%) the results of liver function tests were abnormal, compatible with and typical of alcoholic hepatitis.

Two thirds of all abscesses were found in the right lung (Table 3). All patients had a single abscess cavity except for one man with two contiguous lesions. Most commonly involved was the posterior segment of the upper lobes (33 cases, or 50%), and the superior segment of the lower lobes (27 cases, or 41%), together accounting for 60 cases (91%).

Aerobic and anaerobic cultures of expectorated sputum were made in all cases, but the specimens were neither transported in an anaerobic environment nor promptly cultured in an anaerobic atmosphere. Normal flora, consisting primarily of *Neisseria* species and streptococci, were reported in 42 cases. The remaining cultures

**Table 3.** Pulmonary distribution of 66 cases of primary lung abscess

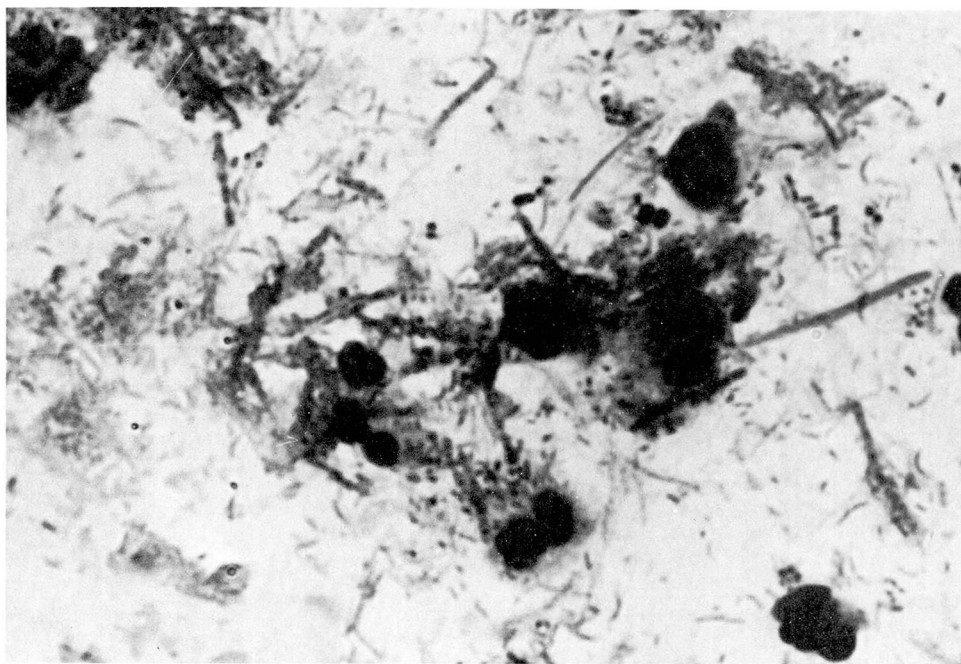
Lobe	Segment	Right		Left	
		No.	%	No.	%
Upper	Posterior	27	41.0	6	9.0
	Apical	1	1.5		
	Anterior	1	1.5	1	1.5
	Subtotal	29	44.0	7	10.5
Middle		2	3.0	1*	1.5
Lower†		13	20.0	14	21.0
	Total	44	67.0	22	33.0

\* Lingula.

† All in superior segment.

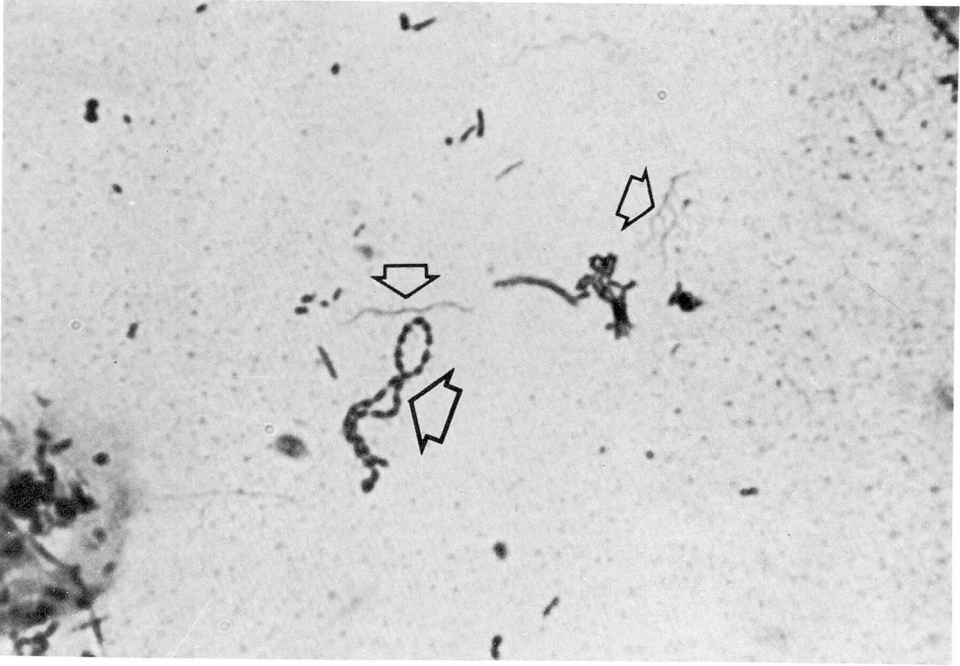
generally grew normal flora mixed with aerobic pathogens, such as staphylococci, *Haemophilus influenzae*, or enterobacteriaceae. Only in a few patients, usually those treated with antibiotics prior to the initial culture, were normal flora not recovered. Bacteroides and fusiform species, not further identified, were commonly isolated from anaerobic cultures along with anaerobic and microaerophilic streptococci, but were considered normal flora unless present in pure culture, an infrequent event. Specific identification and antibiotic susceptibility of anaerobic pathogens were not pursued, since heavy reliance was placed on the diagnostic value of Gram's stain of expectorated or bronchoscopy sputum. The typical sputum Gram's stain demonstrated abundant polymorphonuclear leukocytes or necrotic debris, and a profusion of bac-

teria (Fig. 1) including streptococci (Fig. 2), gram-negative rods resembling Bacteroides, and a variety of pleomorphic gram-negative or pale gram-positive fusiform bacilli of varying lengths, characteristically beaded (Fig. 3), either narrowly tapered (Fig. 4) or cigar-shaped (Fig. 5) at their ends. Spirochetes (Fig. 2), considered absolutely diagnostic of anaerobic infection were noted in about 50% of smears which were carefully examined, but never if the patient had already received antibiotics. Characteristically, the companion aerobic sputum cultures from these specimens were reported as "normal flora." Even in expectorated sputum specimens partially or completely overgrown with enterobacteria, Gram's stain usually remained representative of the increased numbers of normal anaerobic respiratory flora as described above.

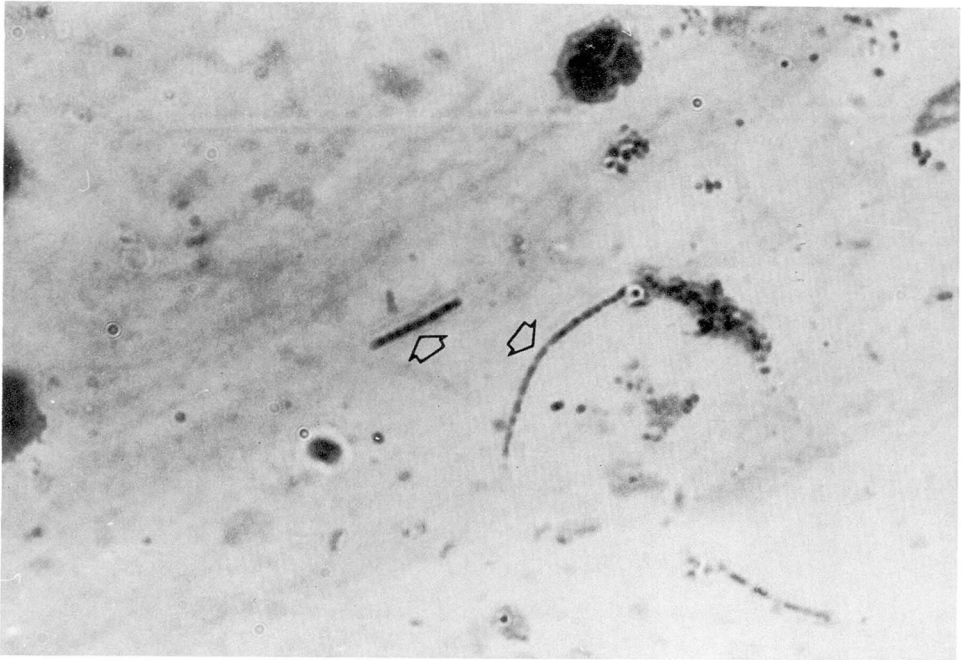


**Fig. 1.** Profusion of mixed bacteria typically seen in sputum of patients with lung abscess.

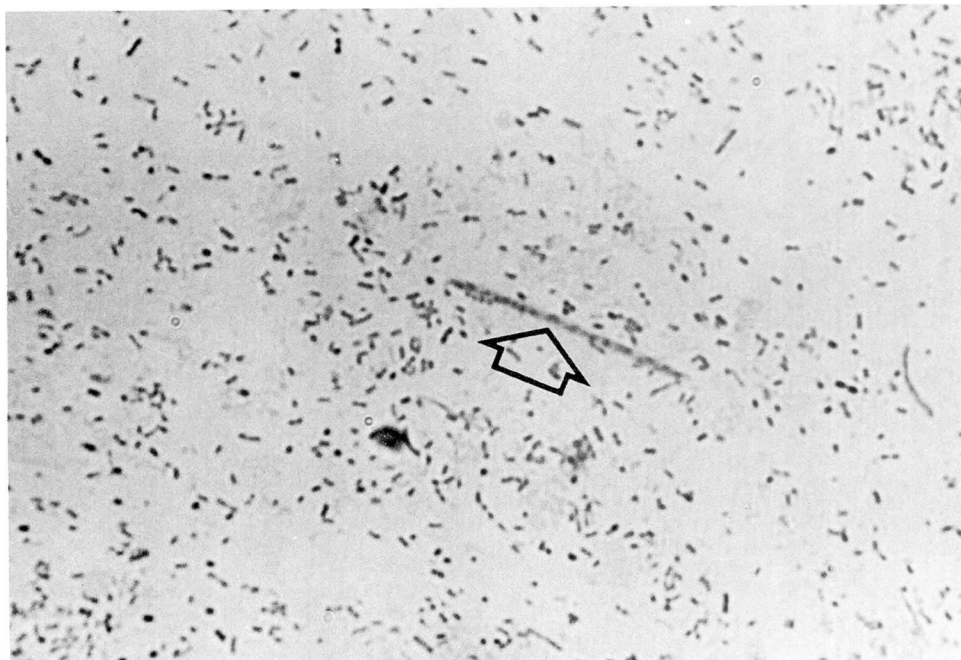




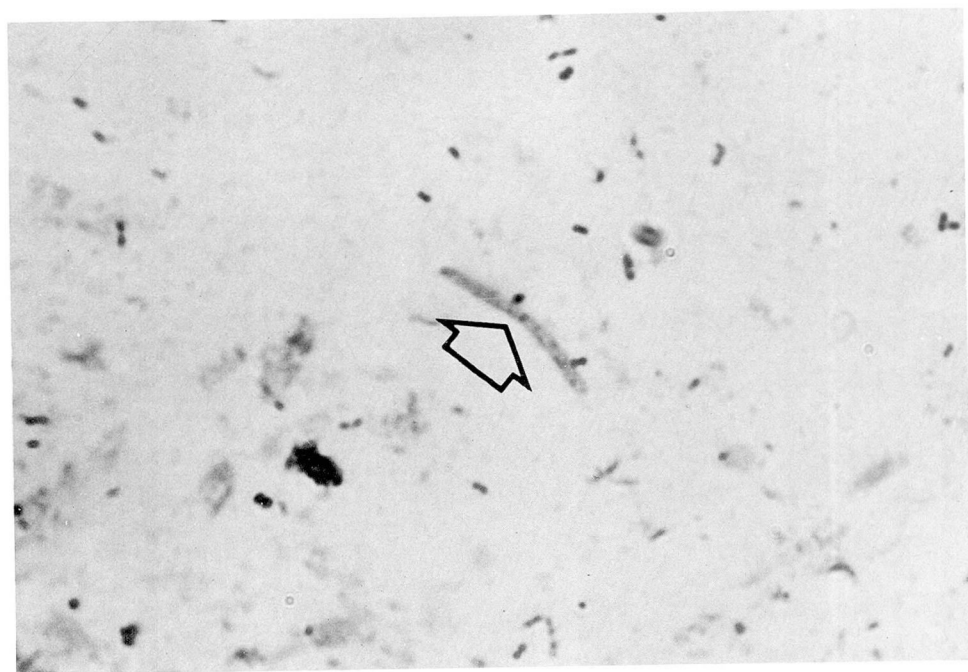
**Fig. 2.** Streptococci (large arrow) and spirochetes (small arrows) characteristically seen in sputum of patients with lung abscess.



**Fig. 3.** Beaded fusiform bacilli (arrows) characteristic of anaerobic organisms in sputum of patients with lung abscess.



**Fig. 4.** Pale, slender, beaded fusiform bacillus (arrow) with tapered ends.



**Fig. 5.** Pale, thick, faintly beaded fusiform bacillus with blunted ends.

### Therapy and outcome

Penicillin alone was used in 51 episodes; two thirds of the patients received 2 weeks of parenteral and 4 weeks of oral medication. In 17 patients, penicillin was given either parenterally (7 patients) or orally (10 patients) for 4 weeks. Doses were 2 to 4 million units of aqueous crystalline penicillin G given intravenously every 6 hours, or 500 to 750 mg phenoxymethyl penicillin orally 4 times a day. Ten patients were treated with another antibiotic (cephalothin, erythromycin, lincomycin, or clindamycin) because of penicillin allergy.

The average duration of antibiotic therapy for the entire group ranged from 4 to 7 weeks, depending on the clinical course and the roentgenographic response. Among 50 patients who were treated only medically, six were lost to follow-up for a variety of reasons and will be excluded from further consideration. Of the remaining 44 medically treated cases with adequate follow-up, in 26 the cavity closed within 6 weeks, and in 18 closure of the cavity required as long as 4 months. However, all of these patients except one had become afebrile and responded clinically within the first 2 weeks. Follow-up sputum cultures were of little or no value in assessing response or in managing the patients and characteristically, but not invariably, the cultures showed overgrowth colonization with resistant enterobacteriaceae, pseudomonas or candida species, irrespective of the clinical course. Only one patient failed to show significant improvement after 10 days of adequate penicillin therapy, although the abscess cavity appeared to be draining adequately. He re-

sponded promptly following the institution of clindamycin therapy. His original sputum culture grew "normal flora" and the Gram's stain smear was compatible with mixed respiratory anaerobes. Subsequent sputa cultures grew only a *Bacteroides* species, not further identified. This may be the only instance in which specific pathogen identification might have influenced the patient's course earlier, but nonetheless he responded promptly to an empiric antibiotic change. Two patients died in the first 48 to 72 hours because of seizures and massive pulmonary aspiration before appropriate antibiotic therapy was begun. Two other patients died as a result of other conditions (terminal pharyngeal carcinoma and massive retroperitoneal hemorrhage from a ruptured colonic diverticulum) before the pulmonary infection could be controlled.

Twelve patients underwent surgery. In five, indications for surgery were either inadequate drainage of the abscess following 3 to 4 weeks of intensive medical therapy or persistent atelectasis. One patient with a presumptive diagnosis of carcinoma of the lung was operated on at the end of the first week of hospitalization. Primary lung abscess discovered at surgery had not been seriously considered preoperatively. However, in six patients there was no indication for surgery other than persistence of a cavity, despite the fact that all six had responded clinically to medical treatment alone. The timing of surgery in these six was from 5 to 12 weeks following admission to the hospital. In none was there evidence of malignancy, and pathologic findings generally showed organizing pneumonia with a chronic abscess cavity.



Six patients were lost to follow-up; two died before appropriate antibiotic therapy was begun; two died of unrelated causes; and one patient was taken to surgery with an incorrect diagnosis. Therefore, 55 cases can be analyzed in terms of success or failure of empiric antibiotic selection. Only one medically treated patient required a change to clindamycin following failure of penicillin therapy. Five of the remaining 11 patients who were taken to surgery had failed to respond to medical therapy; the other six had responded, and except for a persistent cavity surgery was not indicated. Thus in 49 of 55 cases (89%), empiric selection of penicillin (or an appropriate substitute in the presence of penicillin allergy) resulted in successful control of the bacteriologic aspects of this infection.

Bronchoscopy is often considered a routine adjunct in the management of patients with primary lung abscess. In this series, 12 patients were bronchoscoped twice, and an additional 31 patients were bronchoscoped once during their hospitalization. There was no evidence that routine bronchoscopy offered any diagnostic or therapeutic advantage and, particularly when performed in the first 7 to 10 days, usually revealed only hyperemia and purulent drainage from the involved segment. Even in the presence of specific indications (16 of the 43 patients) including persistently elevated temperature or inadequate drainage of the abscess despite aggressive pulmonary toilet, a definite therapeutic benefit consisting of defervescence, increased sputum production, or a rapid decrease in cavity size or fluid level by roentgenography was apparent in only 50% of cases.

## Discussion

Recent advances in the taxonomic classification of anaerobic bacteria and the current availability of relatively simple anaerobic culture techniques have prompted a long overdue reexamination of the bacteriology of primary lung abscess. The bacteriology was defined originally by Smith<sup>2</sup> and Neuhoﬀ and Wessler.<sup>3</sup> Recently other investigators have utilized sophisticated anaerobic techniques to clearly define the complex anaerobic bacteriology of primary lung abscess.<sup>1, 4</sup> These investigators have stressed the need for percutaneous transtracheal aspiration to obtain sputum directly from the lower respiratory tract, thereby avoiding oral contamination. The anaerobes most commonly recovered are *Fusobacterium nucleatum*, *Bacteroides melaninogenicus*, peptostreptococcus, peptococcus, and Eubacteria.<sup>1</sup> *Bacteroides fragilis* is recovered in a small percentage of cases, and aerobic organisms are also occasional participants in this polymicrobial infection. However, these investigators emphasize or strongly imply that it is necessary to delineate all the pathogens participating in a lung abscess, since selection of the antibiotic can be optimal only with knowledge of the specific offending pathogens, particularly in view of variable antimicrobial susceptibility patterns.<sup>1</sup> Additionally, bacteriologic findings based upon cultures of expectorated sputum are condemned out of hand. Both the increased risk of transtracheal aspiration and the expense and time required to enumerate the polymicrobial nature of lung abscess flora must be considered. It has yet to be shown whether this unquestionably proper approach in a research



situation must be applied routinely in less sophisticated laboratories, in order to manage patients whose course, dictated by empiric antibiotic selection on the basis of expectorated sputum studies, does not appear to suffer.

The clinical and laboratory features of primary lung abscess in this series of 66 cases differ little from those cited in many other reports.<sup>1, 5-7</sup> Brock<sup>8</sup> pointed out that a bronchial "embolus," and vascular compromise of the affected pulmonary segment, permit the normally nonpathogenic, predominantly anaerobic flora of the oral cavity to initiate a necrotizing gangrene of the lung. Aspiration of oral contents during altered states of consciousness played an important role in producing lung abscess in our patients and has been demonstrated in many other series. A history of significant alcoholism was present in 75% of our patients. Other causes of aspiration included seizure disorders, anesthesia, cerebrovascular accident, and laryngoesophageal problems.

Traditionally, severe gingival and dental infection have been considered important pathogenetic factors in patients with primary lung abscess. In 67% of our cases, this condition was recorded by the house officer. Although a few reports<sup>9, 10</sup> indicate that lung abscess is rare in edentulous individuals, this dictum is not absolute. Other reports<sup>7, 11</sup> confirm our finding that the edentulous state does not preclude the development of a primary lung abscess.

The most common site of involvement is the posterior segment of the upper lobe or the superior segment of the lower lobe, the right side being involved more commonly than the left. Brock<sup>8</sup> demonstrated that these

segments are most dependent when the patient is recumbent, and consequently are most likely to be filled by gravitational flow during aspiration. Only seven (9%) of our cases involved a different pulmonary segment.

The diagnosis of primary aspiration lung abscess can be made readily on the basis of an appropriate history suggesting a predisposition to aspiration, foul odor of the expectorated sputum (when present), a characteristic Gram's stain of the sputum, growth of normal oral flora in cultures from these same expectorated samples, and roentgenographic evidence of involvement of the posterior dependent segments of the pulmonary tree. Cavitating pneumonias due to specific primary bacterial pathogens, such as *Staphylococcus aureus*, and Friedlander's bacillus are readily distinguished from primary aspiration lung abscesses because the preceding diagnostic constellation is absent. Rather, the pneumonia clinically overshadows the cavity; the sputum Gram's stain and culture reveal a single predominant pathogen. Blood cultures or pleural fluid cultures or both may be positive, and there is no particular predilection for involvement of the posterior dependent segments of the pulmonary tree. Other than in alcoholics with Friedlander's pneumonia, patients with primary cavitating pneumonias seldom have the obvious predisposing background for pulmonary aspiration (Table 1).

Antibiotics have dramatically altered the mortality and necessity for surgical intervention in primary lung abscess. Penicillin alone appears to be the antibiotic most frequently used, although others, such as tetracycline, chloramphenicol, and erythromycin have been used alone or occasionally

in combination with good results.<sup>12, 13</sup> The suggestion that clindamycin should be considered initially in the treatment of primary lung abscess, because of the recovery of *B. fragilis* in approximately 15% of such patients<sup>1</sup> has been evaluated in a more recent study.<sup>14</sup> There was no significant difference in outcome when the two antibiotics, penicillin and clindamycin, were compared in anaerobic pulmonary infection. Patients treated with penicillin for mixed infections, which included *B. fragilis*, responded favorably. Clindamycin is another effective alternative agent when penicillin cannot be employed. Relatively modest doses of penicillin, 2 to 4 million units given orally or parenterally each day for 4 to 6 weeks appears to be adequate therapy for most patients when it is combined with appropriately aggressive postural drainage and pulmonary toilet. Larger doses of penicillin given intravenously, similar to those employed in this series, are usually initiated when the patient is toxic on admission; data to support this approach are lacking, and results of at least one study indicate it is unnecessary.<sup>15</sup>

Few patients require surgical intervention in the presence of a resolving abscess, regardless of the tempo of resolution. In this series, six patients were operated on solely because of a persistent cavity after 5 to 12 weeks of medical treatment. Since 18 of 44 medically-treated cavities required more than 6 weeks for complete resolution, it is apparent that delay in the disappearance of the cavity alone is not an indication for surgery. Delayed closure of the cavity in primary lung abscess has been documented in other studies.<sup>16, 17</sup> Residual cystic or bron-

chiectatic changes, seen in tomograms or bronchograms during long-term follow-up studies, are not associated with recurrent or chronic respiratory symptoms, and are therefore by themselves not an indication for operation.<sup>18</sup> Surgery should be reserved for patients with nonemptying cavities or extensive pleural involvement, or for those in whom both the clinical condition and roentgenograms show deterioration, despite vigorous postural drainage and appropriate antibiotic therapy.

We specifically examined both the diagnostic and therapeutic role of bronchoscopy. When performed early in the hospital course, especially in the first week, simply as a diagnostic exercise, pus from and erythema and edema of the involved bronchus usually preclude obtaining any valuable information other than a direct sample of pus for bacteriologic studies. Bronchoscopy is indicated when there is inadequate drainage of the lung abscess; this is manifested by persistently high fever, decreased sputum production, and failure of cavity emptying as shown by roentgenography. Bronchoscopy at a later date should be considered for a patient without or with unusually slow cavity resolution to rule out the possibility of an indolent carcinoma.

## References

1. Bartlett JG, Gorbach SL, Tally FP, et al: Bacteriology and treatment of primary lung abscess. *Am Rev Respir Dis* 109: 510-518, 1974.
2. Smith DT: Experimental aspiratory abscess. *Arch Surg* 14: 231-239, 1927.
3. Neuhof H, Wessler H: Putrid lung abscess; its etiology, pathology, clinical manifestations, diagnosis and treatment. *J Thorac Surg* 1: 637-649, 1932.

4. Bartlett JG, Gorbach SL, Finegold SM: The bacteriology of aspiration pneumonia. *Am J Med* 56: 202-207, 1974.
5. Bernhard WF, Malcolm JA, Wylie RH: Lung abscess; a study of 148 cases due to aspiration. *Dis Chest* 43: 620-630, 1963.
6. Shafron RD, Tate CF Jr: Lung abscesses; a five-year evaluation. *Dis Chest* 53: 12-18, 1968.
7. Perlman LV, Lerner E, D'Esopo N: Clinical classification and analysis of 97 cases of lung abscess. *Am Rev Respir Dis* 99: 390-398, 1969.
8. Brock RC: *Lung Abscess*. Oxford, Blackwell, 1952.
9. Petty TL, Mitchell RS: Suppurative lung diseases. *Med Clin North Am* 51: 529-540, 1967.
10. Schweppe HI, Knowles JH, Kane L: Lung abscess; an analysis of the Massachusetts General Hospital cases from 1943 through 1956. *N Engl J Med* 265: 1039-1043, 1961.
11. Andersen MN, McDonald KE: Prognostic factors and results of treatment in pyogenic pulmonary abscess. *J Thorac Cardiovasc Surg* 39: 573-578, 1960.
12. Abernathy RS: Antibiotic therapy of lung abscess; effectiveness of penicillin. *Dis Chest* 53: 592-598, 1968.
13. Weiss W, Flippin HF: Treatment of acute nonspecific primary lung abscess; use of orally administered penicillin G. *Arch Intern Med* 120: 8-11, 1967.
14. Bartlett JG, Gorbach SL: Comparison of clindamycin and penicillin in anaerobic pulmonary infections. (Abstr) 14th Interscience Conference on Antimicrobial Agents and Chemotherapy. September, 1974.
15. Weiss WW, Cherniack NS: Acute nonspecific lung abscess; a controlled study comparing orally and parenterally administered penicillin G. *Chest* 66: 348-351, 1974.
16. Block AJ, Wagley PF, Fisher AM: Delayed closure in lung abscess; a re-evaluation of the indications for surgery. *Johns Hopkins Med J* 125: 19-24, 1969.
17. Weiss W: Cavity behavior in acute, primary, nonspecific lung abscess. *Am Rev Respir Dis* 108: 1273-1275, 1973.
18. Barnett TB, Herring CL: Lung abscess; initial and late results of medical therapy. *Arch Intern Med* 127: 217-227, 1971.