

The clinical spectrum of toxoplasmosis in the adult

Edward L. Quinn, M.D.*
Evelyn J. Fisher, M.D.*
Frank Cox, Jr., M.D.*
T. Madhavan, M.D.*

Only in recent years has the complete clinical spectrum of illness caused by toxoplasmosis been defined. This is a condition which may cause difficulties in diagnosis and therapy in medical, surgical, pediatric, and ophthalmologic patients. In recent years members of our group have encountered patients with varied manifestations of toxoplasmosis. This report is concerned with a review of some of our challenging cases.

Toxoplasmosis is caused by *Toxoplasma gondii*, a crescent-shaped protozoan. This organism multiplies intracellularly, and after a few days to weeks forms cysts containing from 50 to 3,000 organisms. *T. gondii* produces infection in many animals, and causes both congenital and acquired infections in man. The congenital form may be subclinical or may be manifest by destructive lesions of the brain, eyes, and viscera. The acquired form is much more common than is usually believed. Available data now reveal that as much as one third of the adult population in the United States have specific antibodies to this organism, most often as a result of a previous subclinical infection. Occasionally, acquired toxoplasmosis is a symptomatic illness similar to

* Division of Infectious Diseases, Department of Medicine, Henry Ford Hospital, Detroit, Michigan.

infectious mononucleosis, with fever and lymphadenopathy. Rarely the acquired form may produce a severe, disseminated illness characterized by myocarditis, pneumonia, or meningoencephalitis. Finally, acquired ocular disease caused by *T. gondii* may occur either alone, in a chronic form, or as a complication of systemic disease.

Historical development

According to Frenkel,¹ toxoplasmosis was first discovered in 1908 in a small rodent, the gondi, maintained in the Pasteur Institute of Tunis. Nicolle and Manceaux² recognized in the gondi a fatal disease that was caused by a new organism which they named *Toxoplasma* (toxon for bow or arc and plasma for form). For the next 3 decades toxoplasmosis remained an obscure disease of laboratory rodents studied at the Pasteur Institute of Paris and the Rockefeller Institute in New York City. It was not until Wolf and Cowen,³ in 1937, and Wolf et al,⁴ in 1939, identified the *Toxoplasma* organism as a cause of congenital meningoencephalitis that this organism was recognized as a cause of human disease.

Between 1940 and 1948 Dr. Albert Sabin⁵ described in detail this disease in children and developed methods of diagnosis and treatment. One phase of this work by Sabin and Feldman⁶ resulted in the development of the so-called "dye test," a new test which provided a method for the diagnosis of this illness. In brief, serum to be tested is mixed with live *Toxoplasma* organisms from the peritoneal exudate of an infected mouse. When serum contains *Toxoplasma* antibody, the surface of these organisms disintegrates

or becomes irregular; serum which does not contain antibody does not affect the organism. The addition of methylene blue to the test facilitates the observation of the intact live organism. The results of this test can be correlated quantitatively with animal protection tests by antibody-containing serum.

In 1940 Pinkerton and Weinman,⁷ and in 1952 Kass et al⁸ described disseminated adult toxoplasmosis. That same year Wilder⁹ found *Toxoplasma* in chronic chorioretinitis of human eyes. Frenkel and Jacobs¹⁰ noted a high incidence of *Toxoplasma* antibodies in adults with this eye lesion, renamed it retinochoroiditis, and advanced the concept that the level of antibody was not important, but rather that the presence of any antibody (detected either by serologic test or skin test) could indicate chronic persistent infection.

During the next few years information was obtained on the methods of transmission of this disease by other than the congenital route. It was recognized that congenital transmission could explain the acute disease in the newborn. However, population surveys revealed an increasing incidence of *Toxoplasma* antibodies with increasing age. This finding cannot be explained by congenital transmission. Furthermore, congenital transmission does not reveal the manner in which mothers of affected babies become infected. An insect vector was sought but none was found. In 1954 the possibility of transmission by carnivorous animals was advanced at Yale by Weinman and Chandler,¹¹ who were able to transmit toxoplasmosis from infected rats to pigs by oral ingestion. These investigators speculated that

man might acquire this disease by eating pork.

In 1956 Jacobs et al¹² studied *Toxoplasma* cysts in the muscles of sheep, pigs, cattle, and horses and compared the biology of the cyst to that of the active organism. They showed that the cysts resisted gastric digestion and were readily infective when administered orally to an experimental animal, but the active forms that were nonencysted were not so readily infective. Finally, results of the studies of Desmonts et al,¹³ in Paris, indicated that eating uncooked meat was important in the transmission of toxoplasmosis. In 1965 he reported that in a tuberculosis hospital for children, raw meat was given for the treatment of tuberculosis. Prior to admission a low incidence of antibodies was found in the children, but within a year 50% to 100% of these patients had acquired antibodies, depending on the type of raw meat consumed. Seven years later Kean et al¹⁴ reported an epidemic of toxoplasmosis among New York medical students after they had eaten undercooked hamburgers.

These and other experiments and observations explained (1) the occurrence of toxoplasmosis in carnivorous animals, and (2) the occurrence of toxoplasmosis in people who often eat raw meat, such as steak tartare or kibbie, or poorly cooked meat such as steak and kabob. However, not explained is the high incidence of antibody in herbivorous animals such as sheep, rabbits, and pigeons, or in human vegetarians.

About this time the possibility of the fecal-oral transmission of the disease was advanced. A Scottish parasitologist, W. M. Hutchison,¹⁵ fed infected mice to a cat and noted that the cat

feces became infectious. Frenkel¹ reported that cat feces infectivity and excretion of *Toxoplasma* oocysts appeared simultaneously 3 to 4 days after the cat ingested an infected mouse, and that oocyst excretion would persist for at least 2 weeks. He also demonstrated the sexual stages of *Toxoplasma* in the intestinal epithelium of cats; this made possible the classification of *Toxoplasma* as a coccidian sporozoan distinct from other coccidia. If one feeds oocysts to mice and animals other than cats, they develop tissue cysts and positive antibody but do not develop an enteroepithelial infection or excrete oocyst. Laboratory workers who test positive cat feces often have seroconversion without becoming ill. Wallace¹⁶ studied antibodies in persons on three Pacific atolls. On two of the atolls, cats, rats, dogs, and pigs were present. Forty-three percent and 56% respectively of the people had positive antibodies for *Toxoplasma*; but on the one atoll with no cats or rats, only 7% of the inhabitants had positive antibody.

Clinical cases

There are four main clinical forms of toxoplasmosis: congenital, ocular, lymphatic, and generalized. The clinical findings in this disease and six cases are reported.

Case reports

Case 1. A 28-year-old resident in pediatrics regularly ate raw ground beef ("steak tartare"); fatigue and cervical adenopathy without fever developed in May 1971. Heterophile tests were negative. In August her symptoms persisted and a *Toxoplasma* IgM indirect fluorescent antibody test (IgM-IFA) was positive in a high titer of 1:1048. This was diagnostic of an early, acute stage of infection. She treated

herself with sulfa drugs for a month, but did not want to use pyrimethamine. Her condition improved. In November she consulted us about any possible effects on future pregnancies. At that time results of her examination were normal, except for a retinal scar.

Case 2. A 25-year-old white man, a circuit court clerk, had fatigue and enlarged cervical nodes for 6 weeks. He was given penicillin, but received no relief. He was examined by the surgical service at Henry Ford Hospital; routine diagnostic studies were negative. A biopsy of a cervical node revealed nonspecific granulomatous lymphadenitis. The pathologist suggested the possibility of toxoplasmosis. At this point we obtained a history of ingestion of raw kibbie (lamb). He was improving and the only physical finding was a minor degree of residual lymphadenopathy. The *Toxoplasma* indirect fluorescent antibody (IFA) titer was

1:2048. (IgM-IFA test was not available when this patient was seen.) The heterophile agglutination test was negative. Histologically, the lymph node showed reactive follicular hyperplasia and irregular clusters of epithelioid histiocytes which encroached upon and blurred the margins of the germinal centers (*Figs. 1 and 2*). If touch preparation of such a node is done, organisms can sometimes be demonstrated. Because of the benign course, treatment was not recommended.

Toxoplasma lymphadenitis is reported to be the most common manifestation of this disease in adults. It is almost always benign and frequently asymptomatic. It may persist for weeks or months with variable fever, occasionally with a rash, and rarely may be a severe illness. Fatigue and asthenia may be somewhat prolonged in these patients. Atypical lymphocytes in

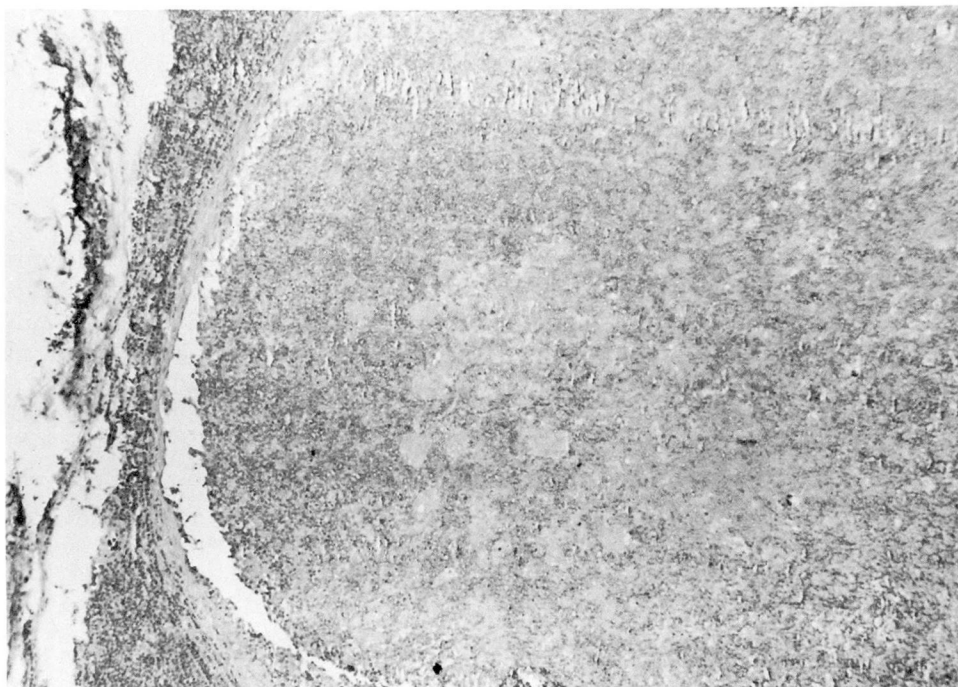


Fig. 1. Irregular clusters of epithelioid histiocytes in the biopsy specimen of the lymph node (case 2) (hematoxylin and eosin stain, $\times 70$). (Courtesy of John W. Rebuck, Ph.D., M.D.)

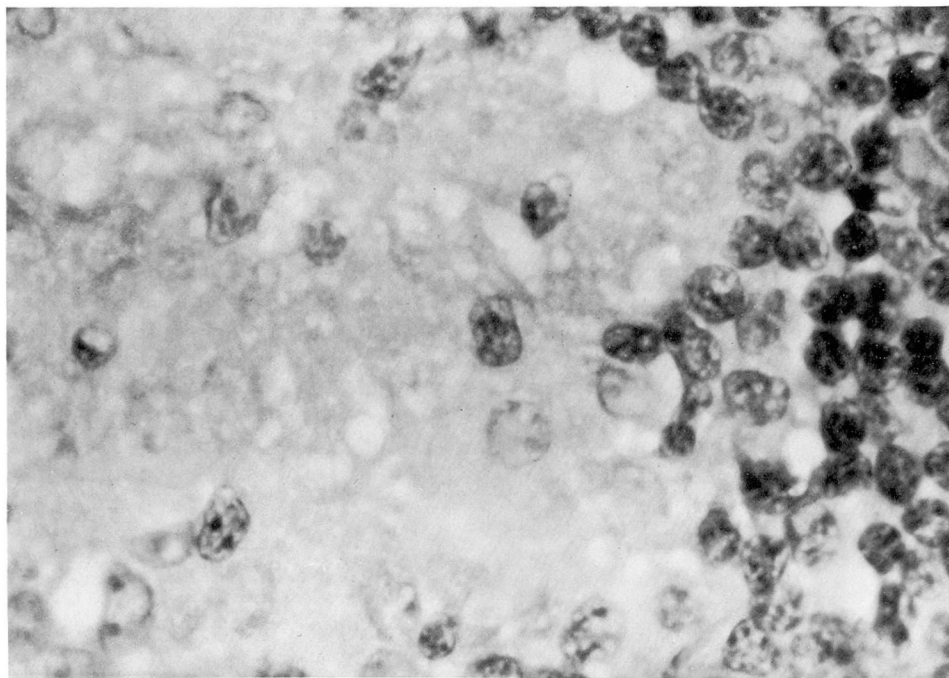


Fig. 2. High power view of epithelioid histiocytes in the lymph node (case 2) ($\times 1100$). (Courtesy of John W. Rebuck, Ph.D., M.D.)

small number may be present. The pathologic findings, as we have indicated, may be diagnostic. Dorfman and Remington¹⁷ recently concluded that a typical lymph node histology plus a positive IgM-IFA test were diagnostic. This was based on a study of patients in whom biopsies established the diagnosis of lymphadenopathy. Of 31 patients who had a Sabin-Feldman dye test with a titer of 1:1024 to 1:30,768, 97% had a positive IgM-IFA test and the typical histopathology noted above. In contrast, of 114 patients who had malignant lymphoma, only two had dye test *Toxoplasma* titers exceeding 1:256, and only one patient had a positive IgM-IFA titer. In a third group of 87 surgical patients who underwent procedures other than lymph node biopsy, only five had

Toxoplasma titers over 1:256, and only one patient showed a positive IgM-IFA test.

Case 3. A 31-year-old man, a butcher who ate raw beef, had a productive cough, pleural pain, dyspnea, fatigue, and fever. The diagnosis was idiopathic myocarditis. An episode of possible pulmonary emboli and a serosanguinous pericardial effusion was treated with steroids with only slight improvement. The severity of myocardopathy was evident by an ECG showing pulsus alternans. Because of his occupation and a history of raw meat ingestion, several *Toxoplasma* antibody titers were done (Table). A course of sulfadiazine-pyrimethamine was given based on the changing *Toxoplasma* serology titers. Figure 3 shows the patient's roentgenogram when he was first seen, and the marked improvement a year later following a course of *Toxoplasma* chemotherapy. Clinically, the patient improved.

Table. Serial *Toxoplasma* antibody titers in a patient with myocardiopathy (case 3)

Date	Sabin-Feldman dye test	Indirect fluorescent antibody test
7-10-71	1:256	1:128
10-5-71	1:512	1:512
11-12-71	1:32	1:32

Generalized adult toxoplasmosis may mimic other diseases and may be a diagnostic problem particularly in the immunosuppressed patient. In the latter instance, diagnosis is difficult, and other similar illnesses may coexist. Myocarditis and pericarditis with a sanguinous type of fluid, as demonstrated in our patient, meningoencephalitis, pneumonia, and even hepatitis have been described.

Case 4. Another patient, a 19-year-old truck driver at age 16, without any associated illness, developed temporal lobe seizures which progressed, despite medical management. All studies were negative except a localization on the EEG. A temporal lobe tumor was resected. Our neuropathologist, Dr. Jose Bebin, diagnosed a granuloma (*Fig. 4*) and pursued this further to show typical *Toxoplasma* organisms (*Fig. 5*).

It was at that time that we saw the patient. The *Toxoplasma* IFA titer was 1:256. He was given a 1-month course of chemotherapy with sulfadiazine and pyrimethamine. His *Toxoplasma* titer subsequently dropped, and the seizures ceased completely without anticonvulsant medication.

In this patient the *Toxoplasma* titer is not a high titer diagnostic of an acute illness, but as indicated, it is compatible with a chronic persistent infection similar to that described for ocular toxoplasmosis.

Case 5. A 52-year-old man had a history of decreased vision for 3 weeks and then sudden deterioration of his focal vision down to 20/400 in the right eye. Clinical findings were normal except for a positive *Toxoplasma* dye test of 1:512. This titer level, although it may be present in asymptomatic persons, nevertheless indicated the patient was infected. He was given a course of pyrimethamine-sulfadiazine and prednisone. His symptoms and eye lesion improved (OD vision 20/70), but 15 months later he had a relapse and a new eye lesion appeared. He was again given prednisone, but not antiparasitic medication, and again he improved.

It is controversial whether one should treat patients with suspected ocular toxoplasmosis with both chemotherapy and prednisone. Some hold that this is a hypersensitivity reaction and that the main thrust of treatment should be with corticosteroids alone. A few cases have been treated with laser, which can be very specifically directed at the site of the infection.

Case 6. A 26-year-old pregnant patient developed fatigue, fever, and lymphadenopathy during the 4th month of pregnancy. She had read an article about toxoplasmosis and requested her physician to do a *Toxoplasma* antibody test which was positive. We were consulted when she was 6½ months pregnant, and we sent her sera to Dr. Jack Remington of Stanford University. The IgM-IFA antibody titer was positive, 1:1024. We treated her for 1 month with sulfadiazine and pyrimethamine. She subsequently delivered a normal infant with no evidence of infection by the IgM-IFA test.

The pregnant patient with possible toxoplasmosis is of major concern. In some states there is new legislation pending or enacted requiring routine

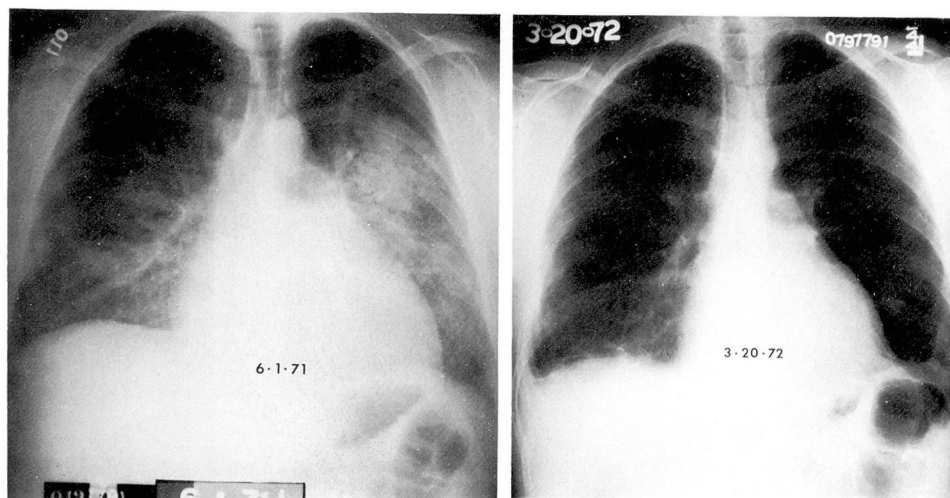


Fig. 3. The chest roentgenogram of a 31-year-old butcher showing marked cardiac enlargement and congestive changes (6-1-71), and resolution of these findings after treatment with sulfadiazine-pyrimethamine (3-20-72) (case 2). (Courtesy of Wolf F. C. Duvernoy, M.D.; to be published as a case report.)

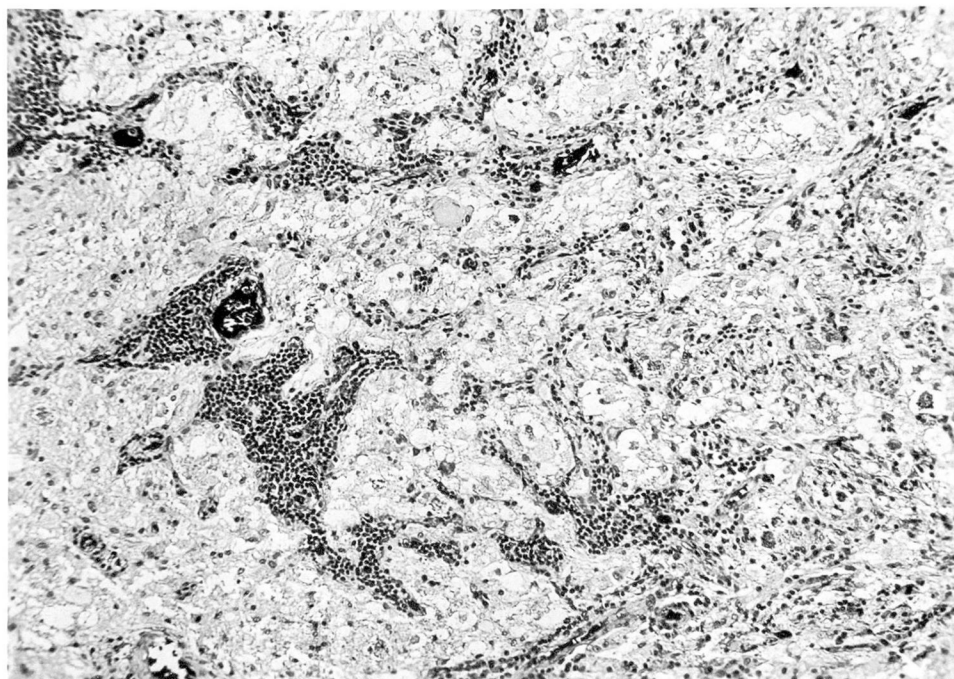


Fig. 4. Cerebral cortical granuloma showing calcific deposits, perivascular plasma cell, lymphocyte and large mononuclear cell infiltrates (case 4) ($\times 175$). (Courtesy of Robert Knighton, M.D. and Jose Bebin, Ph.D.)

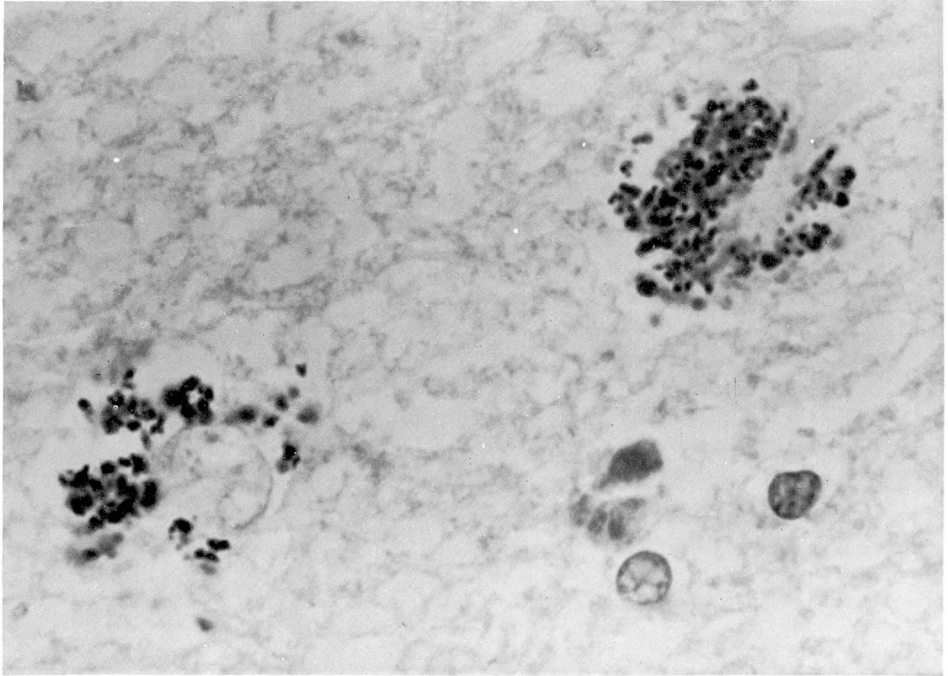


Fig. 5. Silver preparation of cerebral granuloma reveals innumerable small structures largely within the cytoplasm of mononuclear cells, each 5 microns and occurring in cystic-like clusters. Many have a crescent or sickle shaped cell body suggesting *Toxoplasma gondii* (case 4) (Grocott stain, $\times 1065$). (Courtesy of Robert Knighton, M.D. and Jose Bebin, Ph.D.)

Toxoplasma testing of pregnant women. This seems quite premature, because an accurate test adequate to meet this demand is not generally available, and it is not yet possible to interpret the results in all cases. In suspected cases we send the patient's serum to the state laboratory that can provide reliable results.

As in the first patient (case 1) and this patient, we must answer questions such as these: What is the incidence of congenital toxoplasmosis? The answer is something like 1 in every 2,000 to 5,000 births. What are the chances of the infant having toxoplasmosis if the mother has an infection during pregnancy? A recent report by Desmonts and Couvreur¹⁸ indicates an incidence lower than that previously reported.

They examined serum specimens before or early and late in pregnancy to determine the number of pregnant women who had acquired *Toxoplasma* infections. They also determined the number of infants who had acquired the disease. They concluded that the majority of infants born of mothers who had the infection during pregnancy are not affected; and when they are, the infection is usually subclinical. About one third of infants had positive antibody titers. If infection occurred in the first two trimesters, 10% of the infants had clinical infections, and in 5% the infection was severe.

Another important question is how long can the mother be infected with regard to subsequent pregnancies? There is one report of parasitemia

persisting in one patient for 14 months,¹⁹ but in most cases the disease is of short duration and subsequent pregnancies are not affected.

When is a therapeutic abortion advisable? It is recommended when toxoplasmosis is contracted early in pregnancy, and there is definite evidence of clinical infection. Toxoplasmosis does not cause habitual abortion. Of course, there is concern about treating the illness during pregnancy, since pyrimethamine is teratogenic. It was for this reason that Desmonts and Couvreur¹⁸ used spiramycin, an erythromycin-like drug that affected the mother's organism and the placental organism, but did not cross over into the fetus.

Prevention and treatment

How do we apply current knowledge of toxoplasmosis to the prevention and treatment of this infection? There are three common methods of transmission of this illness and rarely some unusual ways of transmission: (1) Transplacental or congenital transmission occurs in many animals including man. Prior infection protects subsequent pregnancy. (2) Carnivorous transmission is dependent on the persistence of an asexual cycle of tissue cysts which resist the digestive juices. In man this mode of transmission usually occurs by eating raw or undercooked meat. One can become infected by handling raw meat. The tissue cyst is killed by thorough cooking or ordinary freezing. (3) The exact role of fecal-oral transmission of *Toxoplasma* in man is unknown. The enteric cycle of this disease occurs only in the cat family (Felidae). If a cat eats a mouse infected with tissue trophozoites or cysts, the cat will develop the intestinal sexual phase and excrete eggs which

initially are shed unsporulated and become infective only when sporulated. The rate of sporulation, depending on the temperature of the soil, occurs in about 3 days at ambient temperatures and longer when it is cold. These oocysts resist many environmental factors. Only a small percentage of cats are infectious at any given time and the duration of infectiousness is usually only several weeks. However, immunity is not absolute and they may become infectious again. It is difficult to diagnose infectious toxoplasmosis in a cat. The presence of antibody titers is not an indication, and it is difficult to distinguish the oocysts in the stool from other common cat parasites. Therefore, it is not possible to take the family pet to the veterinarian to find out if the animal is infectious. Domestic cats as well as other members of the cat family (ocelot, puma, jaguar, Asian leopard, bobcat) can have the enteric phase. Dubey²⁰ found that 57.9% of adult stray cats from Iowa and Missouri have *Toxoplasma* antibodies.

Knowing this about the epidemiology of this disease, how do we advise our patients concerning prevention? A patient who is actively infected should not become pregnant. If she is pregnant, she should strictly adhere to preventive measures, not eat any raw or poorly cooked meat, and take special precautions about cats. Finally, probably patients with active infections during the last half of pregnancy should be treated medically; in the first half, abortion should be considered. The infections that occur in the early part of pregnancy are much more likely to cause severe, congenital defects.

Avoidance of this illness by carni-

vorous transmission obviously depends on not eating raw meat (unless previously frozen for 24 hours) and washing one's hands thoroughly after handling raw meat.

To prevent this disease in domestic cats, the only practical method is to feed the cat a controlled diet of canned or boiled food which has been sterilized, to keep the cat in the house, and not allow it to hunt. However, if the cat is an outdoor cat, it may become infected. To avoid acquiring infection from such an animal, a litter pan should be used and feces should be flushed down the toilet daily because oocysts are not infective until sporulated after a day or two. The litter pan should be incinerated if disposable or sterilized with scalding water or 10% ammonia (other disinfectants are not effective). Children's sandboxes where cats frequent should be covered and gloves should be worn when one works in contaminated soil. Pregnant women should avoid cats with uncertain habits.

What is the current method of active treatment of this infection?²¹ There is good evidence from animal experiments that the combination of sulfonamide with pyrimethamine is effective. There are no controlled studies in man, but combined therapy seems reasonable. Sulfadiazine or triple sulfonamides should be used; other types of sulfa drugs such as sulfisoxazole, should not be used because they are not effective, at least in the animal models. We use sulfadiazine, usually a dose of 4 g daily. Pyrimethamine is given orally in a dose of 25 mg twice a day, and after a week or two when improvement occurs, the dose is given once a day. Both agents are given for about 1 month. We give citrovorum factor, 6 mg/day,

intramuscularly, to prevent the antifolic acid effect of pyrimethamine. Since these drugs can have serious side effects, close monitoring of the patient is desirable.

Most patients with acute Toxoplasma lymphadenitis should not be treated. The patient should be carefully examined, however, to exclude the presence of dissemination or ocular involvement. In more severe forms of adult toxoplasmosis or if the patient is immunologically deficient, treatment is recommended. For ocular infections, the use of a pyrimethamine-sulfonamide-corticosteroid combination is advocated by most experienced clinicians.²²

References

1. Frenkel JK: Pursuing Toxoplasma. *J Infect Dis* 122: 553-559, 1970.
2. Nicolle C, Manceaux L: Sur un protozoaire nouveau du Gondi. *Compt rend Acad de Sci, Paris* 148: 369-372, 1909.
3. Wolf A, Cowen D: Granulomatous encephalomyelitis due to an Encephalitozoon (encephalitozoic encephalomyelitis). A new protozoan disease of man. *Bull Neurol Inst NY* 6: 306-371, 1937.
4. Wolf A, Cowen D, Paige BH: Human toxoplasmosis; occurrence in infants as encephalomyelitis; verification by transmission to animals. *Science* 89: 226-227, 1939.
5. Sabin AB: Toxoplasmosis, a recently recognized disease of human beings. *Adv Pediatr* 1: 1-60, 1942.
6. Sabin AB, Feldman HA: Dyes as microchemical indicators of a new immunity phenomenon affecting a protozoan parasite (Toxoplasma). *Science* 108: 660-663, 1948.
7. Pinkerton H, Weinman D: Toxoplasma infection in man. *Arch Pathol* 30: 374-392, 1940.
8. Kass EH, Andrus SB, Adams RD, et al: Toxoplasmosis in the human adult. *Arch Intern Med* 89: 759-782, 1952.
9. Wilder HC: Toxoplasma chorioretinitis in adults. *Arch Ophthalmol* 48: 127-136, 1952.

10. Frenkel JK, Jacobs L: Ocular toxoplasmosis; pathogenesis, diagnosis, and treatment. *Arch Ophthalmol* 59: 260-279, 1958.
11. Weinman D, Chandler AH: Toxoplasmosis in man and swine; an investigation of the possible relationship. *JAMA* 161: 229-232, 1956.
12. Jacobs L, Remington JS, Melton ML: The resistance of the encysted form of *Toxoplasma gondii*. *J Parasitol* 46: 11-21, 1960.
13. Desmonts G, Couvreur J, Alison F, et al: Étude épidémiologique sur la toxoplasmosé; de l'influence de la cuisson des viandes de boucherie sur la fréquence de l'infection humaine. *Rev Franc Etud Clin Biol*. 10: 952-958, 1965.
14. Kean BH, Kimball AC, Christenson WN: An epidemic of acute toxoplasmosis. *JAMA* 208: 1002-1004, 1969.
15. Hutchison WM: Experimental transmission of *Toxoplasma gondii*. *Nature* 206: 961-962, 1965.
16. Wallace GD: Observations of filth flies as vectors of *Toxoplasma gondii*. *J Parasitol* 56 (4, Section II, Part I): 360, 1970.
17. Dorfman RF, Remington JS: Value of lymph-node biopsy in the diagnosis of acute acquired toxoplasmosis. *N Engl J Med* 289: 878-881, 1973.
18. Desmonts G, Couvreur J: Congenital toxoplasmosis; a prospective study of 378 pregnancies. *N Engl J Med* 290: 1110-1116, 1974.
19. Miller MJ, Aronson WJ, Remington JS: Late parasitemia in asymptomatic acquired toxoplasmosis. *Ann Intern Med* 71: 139-145, 1969.
20. Dubey JP: Feline toxoplasmosis and coccidiosis; a survey of domiciled and stray cats. *J Am Vet Med Assoc* 162: 873-877, 1973.
21. Feldman HA: Human toxoplasmosis; a review. *J Chronic Dis* 10: 488-499, 1959.
22. Toxoplasmosis. *Med Lett Drugs Ther* 10: 107-108, 1968.