

Aspiration and cytology in the evaluation of renal mass lesions

Bruce H. Stewart, M.D.

John K. Pasalis, M.D.

Department of Urology

Differentiation between a renal cyst and solid tumor has long been a vexing problem to the urologist. The intravenous urogram, if of good quality, can readily demonstrate a mass lesion within the kidney, but cannot accurately differentiate between cyst and tumor. Laminography or retrograde pyelography or both may be useful if the intravenous pyelogram is of poor quality. A renal scan is of little diagnostic value, since both cyst and neoplasm fail to concentrate the radioactive material to a significant degree.¹ Nephrotomography has been of additional value in some cases, and selective renal angiography, even with the addition of epinephrine intra-arterially, continues to be only 95% effective in making a definitive diagnosis.^{2, 3} Open exploration of renal mass lesions is not without complications; a mortality rate of 1% to 2% and morbidity of 20% to 30% can be expected following this type of surgery.⁴

In an effort to develop a reliable and nontoxic diagnostic protocol and therefore eliminate the need for unnecessary surgery in patients with a presumptive diagnosis of renal cyst, we have evaluated the results of aspiration and cytology of cyst fluid in 84 consecutive operated cases.

Methods

Eighty-four patients were operated on for renal

cysts at the Cleveland Clinic Hospital from January 1966 through December 1969. All patients were evaluated with respect to age, complaint on primary examination, color, and cytology of cyst aspirate, type of surgery, and morbidity following operation. All but four patients underwent selective renal angiography, and the angiogram in every case demonstrated an avascular mass. Although all roentgenographic criteria for the diagnosis of a typical renal cyst were not met in all cases, in none of the patients could a diagnosis of carcinoma be unequivocally made.

Results

The ages ranged from 3 months to 80 years, with 80% of patients being between 36 and 70 years old. Presenting symptoms in 73% of cases were either referable to the urinary tract or were secondary to hypertension. Location of the cyst was bilateral in 11%, on the right in 49%, and on the left in 40% of patients.

Cyst aspiration was carried out by percutaneous technique prior to surgery in 18 patients. Cytologic findings were normal in all cases. In 13 cases the cyst aspirate was clear in color, and injection of contrast material demonstrated a typical smooth-walled renal cyst completely filling the mass seen on prior intravenous pyelography (*Fig. 1*). In this group of 13 cases, two small benign tumors were found at operation. One was a small tubular adenoma located in the wall of the cyst and was completely resected when the cyst was unroofed. The other was a cystic renal cell adenoma; frozen section of the cyst wall at operation failed to show any abnormal cells, but permanent sections showed a few islands of benign epithelial cells. Since the entire base of the cyst wall had been fulgurated

at the time of operation, no further surgery was advised. The patient remains well at this time, 6 years after the initial operation.

In five patients in whom the percutaneous cyst aspirate was bloody, there was no evidence of tumor on exploration and biopsy of the cyst wall in three. In the fourth patient, a 19-year-old girl, the fluid was turbid, and cyst injection revealed a shaggy appearance thought to represent neoplasm (*Fig. 2*). Right radical nephrectomy was performed, removing a necrotic renal cell carcinoma. The patient is alive and well 5 years following operation. In the fifth patient, the mass appeared grossly neoplastic when exposed surgically, and was removed without biopsy. The final pathology report confirmed the presence of a noninvasive hypernephroma. Cytologic findings from the cyst aspirate in all of these five cases were normal.

In 67 patients, the cysts were aspirated at the time of renal exploration. The fluid was clear in 64 patients, and murky brown in three. Cytologic examination was normal in 50, and not performed in 17. In this group of 67 patients, only one hypernephroma was found. This patient had an avascular lesion on renal angiography, although the angiographic pattern was not classic for benign cyst. At operation, the mass was aspirated through Gerota's fascia with a large caliber needle. No fluid was obtained, but the aspirate contained clotted blood and necrotic debris. The needle puncture was closed and radical nephrectomy performed immediately without opening Gerota's fascia. The character of the aspirate was thus much different in this patient than in the cases of true renal cyst.

A summary of the data in all cases is presented in the *Table*. Cyst aspiration in 86 patients resulted in clear fluid in 77,

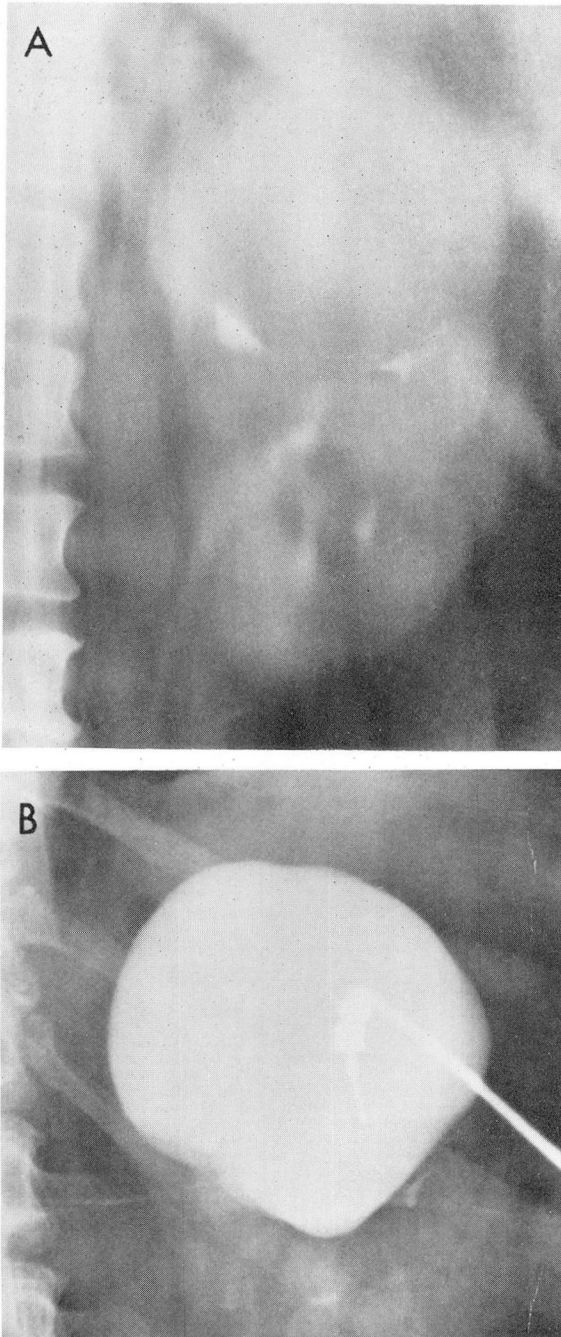


Fig. 1. A, Intravenous pyelogram revealing mass lesion involving upper pole of left kidney. **B,** Injection of contrast medium into the mass after aspiration of clear fluid from the cyst cavity. Note the smooth walls of the cyst, and the fact that the entire renal mass is occupied by the cyst, thus ruling out the possibility of coexisting neoplasm.

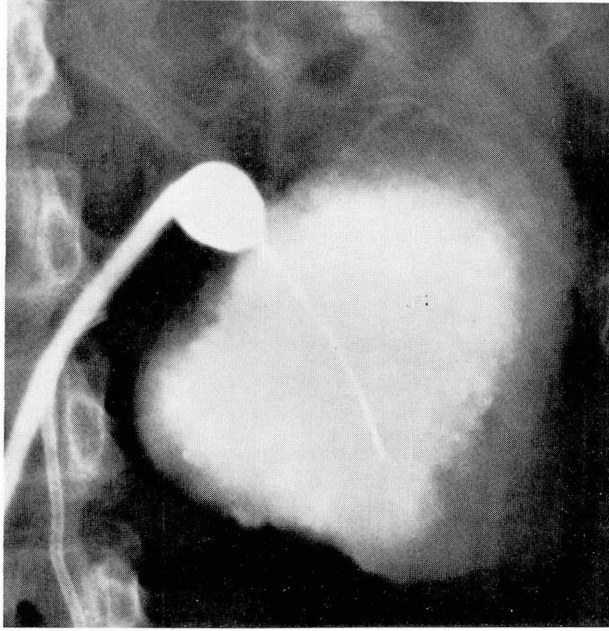


Fig. 2. Injection of contrast medium into cystic mass involving lower pole of left kidney in a 19-year-old girl. Roentgenographic appearance of an irregular, shaggy, and relatively thick wall in this lesion strongly suggests the possibility of neoplasm. Radical nephrectomy was subsequently performed with removal of a necrotic renal cell carcinoma. There has been no evidence of seeding of tumor along the needle tract, and the patient is alive and well more than 4 years after operation.

Table. Cyst aspiration in 86 operated cases

Clear fluid, normal cytologic findings	77
Benign cyst	75
Tubular adenoma	1
Cystadenoma	1
	(3%)
Bloody fluid, normal cytologic findings	8
Benign cyst	6
Hypernephroma	2 (25%)
Necrotic, clotted debris	1
Hypernephroma	1 (100%)

with benign renal tumors found in two of these. The fluid was bloody in eight, and only two of these cases were associated with tumor. There was no evidence of

malignancy on cytologic examination in 83 patients, regardless of fluid color. Both benign tumors and one carcinoma were present in the face of negative cytologic findings.

The operative approach was either via a standard flank or an anterior subcostal incision. Postoperative morbidity was about 20% with either approach, consisting primarily of atelectasis, pneumonia, urinary retention, and other minor wound complications. There was one death: the patient died from a myocardial infarction associated with uncontrollable malignant hypertension on the 5th day following a flank approach to the left kidney. The kidney was explored primarily for renal biopsy, and the cyst was unroofed in conjunction with the biopsy.

Under normal circumstances, were the problem only that of a renal cyst, a patient of this type would certainly not have been operated on.

Discussion

What does this mean in terms of practical management of a given patient? In the elderly or poor-risk patient in whom operation or even renal angiography should be avoided if possible, simple aspiration of the renal mass lesion is enough for a definitive diagnosis.⁵ If the fluid is clear and the results of the cytologic examination are normal, and if contrast medium is injected into the cyst cavity and there is no roentgenographic evidence of tumor, then nothing further should be done. In fact, if the fluid is clear, cytologic examination is probably unnecessary. The entire diagnostic study can be done on an out-patient basis. If the fluid is bloody, the case merits further study including renal angiography. Although in our small series of eight patients only two malignant neoplasms were found, DeWeerd⁶ has reported eight tumors in 17 cases with bloody cyst aspirate, and others have had similar experience. The final decision to operate in patients of this type depends upon the roentgenographic findings and the relative operative risk.⁷

In asymptomatic good risk patients who have normal urinalysis and in whom a mass lesion has been incidentally found on routine intravenous pyelography, a satisfactory diagnostic evaluation can probably be accomplished on an out-patient basis. If laminographic or ultrasound studies or both reveal an avascular lesion characteristic of a cyst, then needle aspiration may be carried out under local anesthesia. If the fluid aspirate is clear, and if the injected cyst cavity

fills completely and shows no evidence of filling defects, then the patient can be safely discharged without further study. Levine et al,⁸ in a review of 438 operated cysts, found no cases of malignancy in the cyst if the aspirated fluid was clear. Our data have shown similar results. Only 2.3% of the cases of Levine et al had cyst associated with carcinoma; in all but one of these patients, the carcinoma arose in a different area of the kidney, and the presenting symptom was a separate mass lesion. Presumably, aspiration of the second mass or renal angiography would give a correct diagnosis in cases of this type.

The incidence of neoplasm in patients with clear fluid and negative roentgenographic studies is probably lower than the potential mortality associated with operative exploration of an otherwise asymptomatic cyst.⁹ Therefore, operative exploration of renal cysts should be considered only when roentgenographic or clinical studies indicate a distinct possibility of neoplasm, or if the cyst is causing significant obstruction of the collecting system. Routine nephrectomy should not be done in most patients with bloody cyst aspirate, since the incidence of carcinoma in these cases is relatively low. In such cases, the cyst should first be exposed, and if there is no gross evidence of carcinoma, the cyst should be opened and biopsy performed before nephrectomy is contemplated.

Proper utilization of the technique of cyst aspiration and cystography can result in an accurate diagnosis without surgical intervention in many patients. Conservative management can significantly reduce the expense and morbidity of surgical exploration in properly selected cases. Those patients in whom appropriate diagnostic studies do not absolutely confirm

the presence of a benign cyst can then be operated on with a greater chance of detecting and correcting potentially lethal renal lesions.

Summary

(1) Cyst aspiration is particularly helpful in evaluating renal mass lesions in otherwise asymptomatic patients. If the cyst fluid is clear and roentgenographic studies indicate a typical cyst, operation can be avoided in the majority of cases.

(2) Aspiration of thin, yet bloody fluid from a renal cyst does not necessarily mean the cyst is associated with neoplasm. If roentgenographic studies indicate cyst in this situation, the cyst should be explored and a biopsy should be done before nephrectomy is summarily performed.

(3) If aspiration of a cystic mass lesion results in thick necrotic material or associated roentgenographic studies indicate neoplasm, then radical nephrectomy

should be done without further exposure of the lesion.

References

1. Stewart BH, Haynie TP, Nofal MM, et al: The role of scintillation scanning on the diagnosis of renal tumors. *J Urol* **87**: 782-789, 1962.
2. Chynn KY, Evans JA: Nephrotomography in the differentiation of renal cyst from neoplasm; a review of 500 cases. *J Urol* **83**: 21-24, 1960.
3. Meaney TF, Stewart BH: Selective renal angiography; an integral part of management of renal mass lesions. *J Urol* **96**: 644-650, 1966.
4. Kropp KA, Grayhack JT, Wendel RM, et al: Morbidity and mortality in renal exploration for cyst. *Surg Gynecol Obstet* **125**: 803-806, 1967.
5. Lalli AF: Percutaneous aspiration of renal masses. *Am J Roentgenol Radium Ther Nucl Med* **101**: 700-704, 1967.
6. DeWeerd JH: Percutaneous aspiration of selected expanding renal lesions. *J Urol* **87**: 303-308, 1962.
7. Plaine LI, Hinman F Jr: Malignancy in asymptomatic renal masses. *J Urol* **94**: 342-347, 1965.
8. Levine SR, Emmett JL, Woolner WB: Cyst and tumor occurring in the same kidney. *J Urol* **91**: 8-9, 1964.
9. Zelch J, Lalli A, Stewart BH, et al: Renal cyst aspiration; a safe and accurate procedure. *Urology* 1976. In press.