Echocardiographic findings in false aneurysm of the left ventricle

Fernando P. Morcerf, M.D.
Enio P. Duarte, M.D.
Ernesto E. Salcedo, M.D.
Wayne Siegel, M.D.

Department of Cardiology

An aneurysm of the left ventricle after myocardial infarction may be either a true or false aneurysm. A false aneurysm of the left ventricle is a rare form of myocardial rupture, which restricts its expansion in the pericardial sac because of pericardial adhesions.[1] Its early appearance resembles that of a localized hematoma. The intraventricular pressure seems to be one of the reasons that this hematoma expands into a saccular shape with communication with the left ventricular cavity by a small channel or neck.[2] The mouth or neck of the false aneurysm is relatively small, compared with the diameter of the fundus of the aneurysm; and its wall consists of fibrous tissue (pericardial and fibrotic tissue from the resolving hematoma).[2]

The echocardiographic findings are described in two patients with false aneurysm involving the posterolateral wall of the left ventricle. The diagnosis in both cases was confirmed by surgery.

Case reports

Case 1. A 54-year-old white man had severe chest pain on January 12, 1975, while at work. He was admitted to a hospital where an electrocardiogram (ECG) showed findings compatible with an acute anterior wall myocardial infarction. Anticoagulant therapy was begun on the 2nd day of admission but

Downloaded from www.ccjm.org on April 25, 2024. For personal use only. All other uses require permission.

was discontinued on the 3rd day because of the appearance of a pericardial rub. During that admission, he had recurrent anterior chest pain which was thought to be due to pericarditis. He was discharged after 25 days, and he felt well until the day of his second admission, when taking a deep breath, he felt mild chest discomfort, weakness, and dyspnea. On admission, a continuous ECG tracing revealed episodes of paroxysmal ventricular tachycardia. He appeared pale and dyspneic. Cardiac catheterization showed a dominant left coronary circulation with a large circumflex artery in its proximal third and a saccular structure localized at the posterolateral wall of the left ventricle. Mild mitral regurgitation was also present. Left ventricular end diastolic pressure was 30 mm Hg and the ascending aortic pressure was 90/60 mm Hg. He was transferred to the Cleveland Clinic on February 22, 1975. Physical examination revealed a blood pressure of 86/58 mm Hg, the pulse rate was 116 beats per minute and regular, and the temperature was 100.3 F. He was pale but in no acute distress. There was mild jugular vein distention, and no thyroid enlargement. Dullness was noted at the bases of both lungs and there were late inspiratory rales. The point of maximal cardiac impulse was in the sixth left intercostal space in the anterior axillary line. There were no thrills, heaves, or paradoxical impulse. The intensity of the first heart sound was decreased and there was a Grade III/VI soft holosystolic murmur heard at the apex. The second heart sound was normal. A soft S3 gallop was heard. The remainder of the physical examination was unremarkable. The chest roentgenogram revealed engorgement of the pulmonary vessels and mild enlargement of the heart. His hemoglobin value was 10 g/dl and the white blood cell count and differential count were within normal limits. An echocardiogram was done on the 2nd hospital day *(Fig. 1)*. Excision of a fibrous saccular structure adjoining the left ventricle and patching of the myocardial rupture were performed on March 2. The patient was discharged 10 days later without complications.

Case 2. A 36-year-old white man was in good health until January 13, 1975, when he was awakened by severe retrosternal pain. An ECG revealed an acute anterolateral myocardial infarction. The patient was discharged after 16 days of hospitalization without complications. On February 3, 1975, he suddenly felt hot and lost consciousness. The blood pressure and pulse were not obtainable upon admission, and cardiac resuscitation was required. He was then transferred to the Cleveland Clinic. Physical examination revealed a blood pressure of 130/80 mm Hg, and the pulse rate was 70 beats per minute; a pulsus alternans was noted. The temperature was 98.6 F. No jugular engorgement was detected. The lungs were clear. The apical impulse was diffuse in the fifth and sixth left intercostal space. There was a systolic expansion in the third and fourth intercostal spaces in the midclavicular line. A palpable S4 was also present. There was a summation gallop. Hepatojugular reflux was noted. The remainder of the examination was unremarkable. Cardiac catheterization performed on February 27, 1975, revealed a dominant right coronary artery with minimal irregularities. The left anterior descending coronary artery showed minor irregularities in its mid-third, and the circumflex artery showed a total obstruction after the first lateral branch. A left ventriculogram demonstrated a saccular structure localized in the posterolateral wall of the left ventricle. The left ventricular end diastolic pressure was 17 mm Hg, and the ascending aorta pressure was 100/68 mm Hg. A chest roentgenogram revealed cardiomegaly and the left cardiac contour showed a configuration suggestive of left ventricular aneurysm. The ECG showed a remote anterolateral myocardial infarction with involvement of the posterior wall. An echocardiogram was done on March 4, 1975 *(Fig. 2)*. Surgical removal of the saccular

Downloaded from www.ccjm.org on April 25, 2024. For personal use only. All other uses require permission.

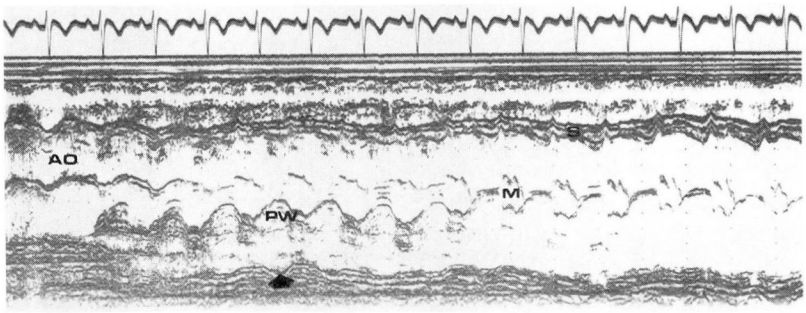

Fig. 1. Echocardiogram of patient 1. M Mode scan from the base of the heart (left) toward the apex (right). Ao = aorta, PW = posterior wall of the left ventricle, M = mitral valve. Arrow points at the systolic expansion of the wall of the false aneurysm.

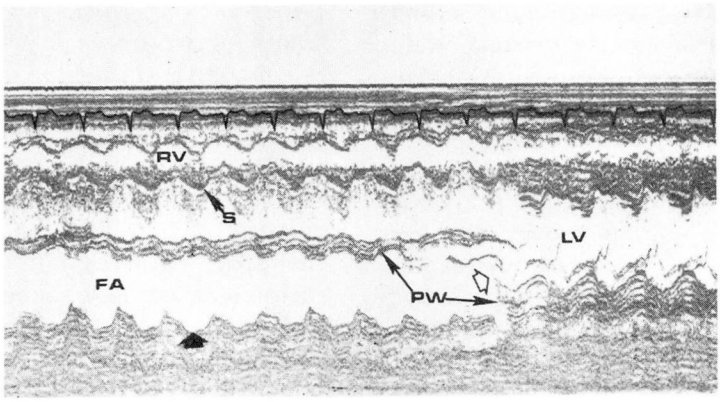

Fig. 2. Echocardiogram of patient 2. M Mode scan transversally in an area near the mitral valve. RV = right ventricle, S = septum, FA = false aneurysm, PW = posterior wall, LV = left ventricular cavity. Closed arrow shows the systolic expansion of the false aneurysm. Open arrow shows the communication between the false aneurysm and the left ventricular cavity. Part of the posterior wall of the left ventricle is displaced anteriorly.

structure was performed on March 5, 1975. He was discharged on April 12, 1975.

Methods

The echocardiographic studies were performed with the patient in the left lateral decubitus with 30% elevation of the thorax. A commercially available ultrasonoscope (Unirad Corporation, Denver, Colorado) and a ½-inch transducer focused at 7.5 cm with a repetition rate of 1,000 impulses per second and an ultrasound frequency of 2.25 Hz was used. The echocardiogram was recorded on a strip-chart recorder (VR-6, Electronics for Medicine, White Plains, New York).

Results

Figure 1 shows the echocardiographic scan from the base of the heart toward the apex from patient 1. An echo-free space is shown posterior to the posterior left ventricular wall. This space is limited anteriorly by the posterior ventricular wall and posteriorly by a structure producing a dense line of echoes which shows

Downloaded from www.ccjm.org on April 25, 2024. For personal use only. All other uses require permission.

systolic expansion (posterior motion). Scanning toward the mitral valve, the posterior left ventricular wall shows a sudden discontinuity; the echo-free space behind the posterior wall is continuous with the left ventricular cavity which is now limited by the interventricular septum anteriorly and by these dense lines of echoes posteriorly.

Figure 2 shows the echocardiogram of patient 2. It represents a transverse scan through the left ventricle in an area near the mitral valve. A large echo-free space is found behind the posterior left ventricular wall. The structure posterior to this echo-free space shows systolic expansion. Its wall is composed of multiple lines of echoes. As one scans medially toward the mitral valve, the echo-free space is in continuity with the left ventricular cavity. There is discontinuity of the posterior wall which seems to be initially displaced anteriorly.

Figure 3 shows the postoperative echocardiogram from patient 2. In both patients, the discontinuity of the posterior ventricular wall and the echo-free space behind were absent in the postoperative echocardiogram.

Discussion

Echocardiographic findings of two patients with false aneurysm involving the posterolateral wall of the left ventricle are reported. Echocardiographic diagnosis depends on the demonstration of the aneurysm sac as an echo-free space behind the posterior left ventricular wall and a demonstration of a discontinuity of the posterior ventricular wall as one scans toward the neck or mouth of the aneurysm *(Fig. 4)*.

The echo-free space behind the posterior ventricular wall may be mistaken for that seen in pericardial effusion;[3–4] however, systolic expansion and the discontinuity of this echo-free space with the left ventricular cavity seen in false aneurysm differentiates these two entities. The sudden discontinuity of the posterior ventricular wall as one scans toward the mouth of the false aneurysm seems to be characteristic of this con-

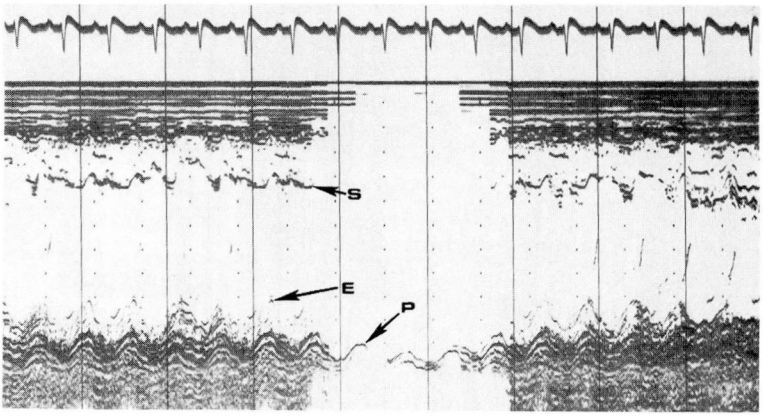

Fig. 3. Postoperative echocardiogram of patient 2. Left ventricular view. S = septum, E = endocardium, P = pericardium. Note the absence of the echo-free space behind the posterior wall of the left ventricle.

Downloaded from www.ccjm.org on April 25, 2024. For personal use only. All other uses require permission.

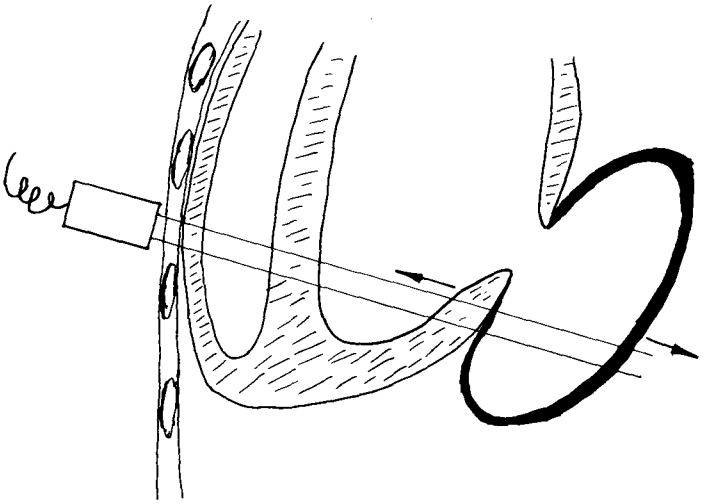

Fig. 4. Diagram. The posterior wall of the left ventricle is depicted moving anteriorly during systole while the wall of the false aneurysm moves posteriorly.

dition. It is not found in cases of true aneurysm where the posterior wall becomes the wall of the aneurysm.[5]

In both patients, the false aneurysms were located in the posterolateral wall of the left ventricle, an area easily accessible for echocardiographic study. It is possible that a false aneurysm located in the anterolateral or apical wall of the left ventricle may be more difficult to recognize echocardiographically.

The increased incidence of rupture of false aneurysm of the left ventricle compared with true aneurysm[6] makes differentiation between these two pathologic conditions of more than academic interest. Echocardiography may be a useful noninvasive method of making this differentiation.

Summary

The echocardiographic findings of two patients with false aneurysm of the left ventricle are reported. In both patients, an echo-free space behind the posterior wall of the left ventricle showed systolic expansion. Continuity of this echo-free space with the left ventricular cavity due to sudden discontinuity of the posterior left ventricular wall was present. This echocardiographic finding may be mistaken for pericardial effusion. Echocardiography may be a useful noninvasive method for the diagnosis of false aneurysm of the left ventricle.

References

1. Chesler E, Korns ME, Semba T, et al: False aneurysm of the left ventricle following myocardial infarction. Am J Cardiol **23:** 76–82, 1969.
2. Roberts WC, Morrow AG: Pseudoaneurysm of the left ventricle; an unusual sequel of myocardial infarction and rupture of the heart. Am J Med **43:** 639–644, 1967.
3. Horowitz MS, Schultz CS, Stinson EB, et al: Sensitivity and specificity of echocardiographic diagnosis of pericardial effusion. Circulation **50:** 239–247, 1974.
4. Figenbaum H, Zaky A, Waldenhausen JA:

Downloaded from www.ccjm.org on April 25, 2024. For personal use only. All other uses require permission.

Use of ultrasound in the diagnosis of pericardial effusion. Ann Intern Med **65:** 443–452, 1966.

5. Petersen JL, Johnston W, Hessel EA, et al: Echocardiographic recognition of left ventricular aneurysm. Am Heart J **83:** 244–250, 1972.
6. Van Tassel RA, Edwards JE: Rupture of heart complicating myocardial infarction; analysis of 40 cases including nine examples of left ventricular false aneurysm. Chest **61:** 104–116, 1972.

Downloaded from www.ccjm.org on April 25, 2024. For personal use only. All other uses require permission.