

# Echocardiographic determination of the etiology of severe mitral regurgitation

Fernando Morcerf, M.D.

Ernesto E. Salcedo, M.D.

Wayne Siegel, M.D.

*Department of Cardiology*

Diseases affecting one or more of the components of the mitral apparatus (papillary muscles, chordae tendineae, mitral valve leaflets, and annulus) often cause mitral regurgitation.<sup>1</sup> The natural history, surgical therapy, and prognosis may vary with etiology.<sup>2</sup> A noninvasive diagnostic method for distinguishing different types of mitral insufficiency is needed.

Recent studies have emphasized the echocardiographic findings of diverse causes of mitral regurgitation.<sup>3-15</sup> In cases of rheumatic mitral regurgitation, the mitral valve has been found to be thickened, with increased echo amplitude and with an EF slope which may be decreased, normal, or increased.<sup>3, 9, 13, 15</sup> Prolapsing mitral valve is associated with a pansystolic or late systolic posterior motion of one or both leaflets.<sup>3, 4, 7, 11, 12</sup> The echocardiographic findings in ruptured posterior leaflet chordae tendineae include systolic separation of the mitral leaflets,<sup>3-14</sup> paradoxical early diastolic anterior motion of the posterior leaflets,<sup>3</sup> demonstration of a posterior leaflet which, after moving anteriorly during early diastole, remains in this abnormal position throughout diastole.<sup>16</sup> In ruptured chordae of the anterior leaflet, a diastolic, coarse, chaotic fluttering of the anterior leaflet may be noted.<sup>14</sup>

This study reports the echocardiographic findings in 21 patients with severe mitral regurgitation secondary to rheumatic mitral valvular disease, prolapsing mitral valve leaflets, and patients with ruptured chordae tendineae. All diagnoses were corroborated by cardiac catheterization and direct surgical visualization of the mitral apparatus.

### Materials and methods

Twenty-one patients who had surgical reconstruction or replacement of the mitral valve were selected for this study. The criteria for selection of patients were the presence of mitral valve regurgitation as the predominant hemodynamic impairment as assessed by cardiac catheterization and the availability of technically satisfactory preoperative echocardiograms. The surgeons' operative description of the mitral valve and the cardiac catheterization data were used to separate the patients into four groups:

Group I—Five patients with rheumatic mitral regurgitation. During cardiac catheterization all patients had little or no diastolic gradient across the mitral valve ( $<5$  mm Hg). The surgeon's description of the mitral valve in these patients was "thickened, retracted leaflets with thickened, fused, and foreshortened chordae tendineae."

Group II—Four patients with prolapsed mitral valve shown by cardiac catheterization. Intact chordae tendineae were found during surgery.

Group III—Two patients with mitral regurgitation. The etiology could not be determined, despite cardiac catheterization and surgical inspection of the mitral apparatus. No ruptured chordae tendineae were found

in these patients. One patient had myxomatous degeneration of the mitral valve and the other had retraction of the leaflets secondary to fibrosis.

Group IV—Ten patients with surgically proven ruptured chordae tendineae. There were seven patients with ruptured chordae tendineae of the posterior leaflet and three had ruptured chordae of the anterior and posterior leaflets. In this group, the ruptured chordae were probably caused by subacute bacterial endocarditis in two cases, the remaining patients had an apparently normal valve or myxoid degeneration prior to rupture.

### Normal subjects

The echocardiograms of 20 patients who had had cardiac catheterization with coronary angiograms for the diagnosis of atypical chest pain, and were found to have normal hearts, were used to establish normal values for echocardiograms obtained for this study.

All echocardiographic studies were performed with the patients in the left lateral decubitus with a  $30^\circ$  elevation of the thorax. A commercially available ultrasonoscope (Unirad Corporation, Denver, Colorado) with  $\frac{1}{2}$  inch diameter transducer focused at 7.5 cm was used. A photographic strip chart recorder was employed. (VR6 Electronics for Medicine, White Plains, N.Y.). The transducer employed has ultrasonic frequency of 2.25 MHz at a repetition rate of 1000/sec. The transducer was applied with water soluble gel in the third or fourth left intercostal space, about 2 or 3 cm from the left sternal margin. It was then tilted medially and inferiorly until satisfactory echoes from

the mitral valve were obtained. An attempt was always made to demonstrate both the anterior and posterior leaflet of the mitral valve. From this position, by angling the transducer medially and superiorly, the aortic root, aortic valve, and left atrium were demonstrated. The echoes from the endocardial surface of the posterior wall of the left ventricle and the interventricular septum were obtained by tilting the transducer to a position slightly inferior and lateral to the one from the mitral valve. Mitral valve echoes or most commonly chordae tendineae were present at this level, assuring a standardized site for comparison of dimensional measurements from the left ventricular cavity.

### Measurements

End diastolic left ventricular minor axis diameter (D) = distance between the endocardial surface of the posterior left ventricular wall to the endocardium of the interventricular septum at the left ventricular side during the R wave of the electrocardiogram.

End systolic diameter (S) = distance between the endocardial surface of the posterior left ventricular wall to the endocardial surface of the interventricular septum at the left ventricular side, measured at the time of maximal systolic anterior excursion of the posterior ventricular wall.

End systolic volume (ESV) =  $S^3$

End diastolic volume (EDV) =  $D^3$

Stroke volume (SV) = EDV - ESV

Ejection fraction (EF) =  $\frac{SV}{EDV}$

Septal amplitude ( $\Delta$ Sep) = amplitude of maximal systolic excursion of the endocardial surface of the inter-

ventricular septum at the left ventricular side.

Left atrial size (LA) = distance from the inner side of the posterior aortic wall to the posterior wall of the left atrium as measured during the end of the ejection period.

Aortic size (Ao) = distance from the outer side of the posterior aortic wall to the inner side of the anterior aortic wall measured before the beginning of ejection.

$\frac{LA}{Ao}$  = relationship between the left atrial size and the aortic size.

Amplitude of motion of the anterior mitral leaflet (CE amp) = vertical distance between point C and point E.

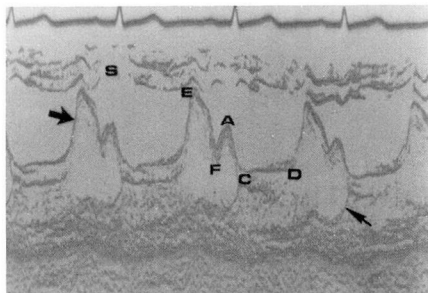
DE slope (DE) = rate of initial diastolic anterior movement of the anterior leaflet from point D to point E measured in millimeters per second.

EF slope (EF) = rate of initial diastolic down slope of the anterior leaflet of the mitral valve measured in millimeters per second.

All the measurements were compared and correlated using the Student *t* test of statistical analysis for significance.

### Results

**Normals.** *Figure 1* shows the echocardiogram of the mitral valve from a representative patient of this group. During systole, the anterior and posterior leaflets are close together and have a slight anterior motion reflecting the anterior movement of the mitral ring as the left ventricle empties (CD segment). At the beginning of diastole, the anterior leaflet has a rapid anterior movement limited at point E. After point E, the anterior

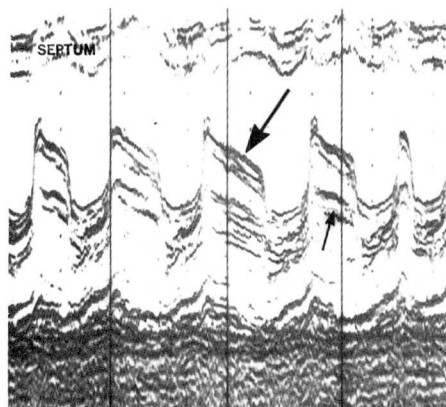


**Fig. 1.** Normal mitral valve recording. The anterior leaflet (large arrow) and the posterior leaflet (small arrow) have similar diastolic movement but in opposite direction. S = septum.

leaflet moves posteriorly (EF slope). The rate of this slope is related to the mitral valve flow during the rapid ventricular filling period.<sup>17</sup> The anterior leaflet remains in a semi-closed position until the atrial contraction reopens it and the leaflet again moves anteriorly to point A. With the beginning of ventricular contraction the leaflet moves posteriorly to point C where it meets the posterior leaflet. The posterior leaflet has a similar but opposite diastolic movement as the anterior leaflet.

The anterior leaflet touched the interventricular septum in 14% of the normals. Frequently, more than two echoes were recorded from the mitral valve during systole. No cases of systolic expansion of the posterior left atrial wall were noted in this group. The values for all measurements made in this group are found in *Table 1*.

**Group I—Rheumatic mitral regurgitation.** *Figure 2* is a representative echocardiogram from one of the five patients in this group. The mitral valve was broader than normal in all cases. Its brightness as compared with that of the posterior left ventricular wall and interventricular septum



**Fig. 2.** Echocardiogram from a patient with severe rheumatic mitral regurgitation. The leaflets are broader than normal. The anterior leaflet (large arrow) shows the initial part of the EF slope with a faster rate of descent than the latter portion. The posterior leaflet (small arrow) moves anteriorly during diastole.

was increased. The posterior leaflet had a diastolic anterior motion, synchronous with the anterior leaflet in four cases. In the remaining patient, it had a normal posterior movement. In general, the echocardiogram in this group resembled that of mild mitral stenosis with decreased EF slope, but not to the degree seen in tight mitral stenosis. In four patients, the EF slope had an initial rapid posterior movement in early diastole followed by a plateau or a deceleration of the closing rate. The initial slope varied from 20 to 150 mm/sec (mean 56 sec).

The severity of the mitral regurgitation was reflected in this group by higher EDV, ESV, SV, LA, and LA/Ao as compared with normals (*Table 1*).

The amplitude of systolic motion of the IV septum ( $\Delta$ sep), although higher than the normals, did not reach statistical significance. The ejection fraction in this group was

decreased as compared with normals ( $p < 0.02$ ).

The CE amplitude of the anterior leaflet ranged from normal to increased (CE amplitude = 20 to 35 mm). The rate of early diastolic opening (DE slope) was normal to increased (DE slope = 240 to 960 mm/sec) (Table 1).

Multiple echoes from the CD segment of the mitral valve were noted in all patients.

**Group II—Mitral valve prolapse with intact chordae tendineae.** Figure 3 shows two echocardiograms of the mitral valve from two patients in this group. All had thin valves with

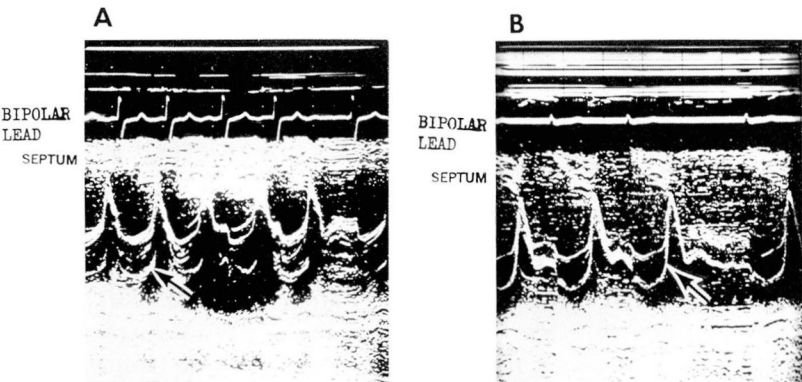
normal brightness. All patients had hammock-like CD segments with multiple echoes. These multiple echoes may be returning from both leaflets or from only a redundant anterior leaflet. No late systolic prolapse was found in this group. Three patients had what has been described as an early diastolic paradoxical anterior motion of the posterior leaflet (“diastolic overshoot”). This is considered by some investigators to be indicative of ruptured chordae of the posterior leaflet.<sup>3</sup>

The anterior mitral leaflet touched the interventricular septum in all cases.

**Table 1.** Echocardiographic measurements obtained including statistical comparisons with normal subjects

	EDV (cm <sup>3</sup> )	ESV (cm <sup>3</sup> )	SV (cm <sup>3</sup> )	F Fr	ΔSep (cm)	LA (cm)	LA/Ao	CE ampli- tude (mm)	DE slope (mm/ sec)	EF slope (mm/ sec)
Normal	110	33	78	0.72	0.6	3.1	1.02	22	308	107
20 patients	(±44)	(±22)	(±25)	(±0.10)	(±0.2)	(±0.4)	(±0.15)	(±3)	(±75)	(±36)
Rheumatic	241	99	141	0.58	0.8	5.7	2.21	27	520	56
5 patients	(±103)	(±44)	(±67)	(±0.09)	(±0.3)	(±0.4)	(±0.61)	(±5)	(±289)	(±53)
	$p < 0.001$	$p < 0.001$	$p < 0.005$	$p < 0.02$	NS	$p < 0.001$	$p < 0.001$	$p < 0.02$	$p < 0.01$	$p < 0.02$
Ruptured	266	70	196	0.74	1.1	5.0*	1.70*	27	484	102
chordae	(±92)	(±44)	(±63)	(±0.09)	(±0.5)	(±0.5)	(±0.27)	(±5)	(±186)	(±40)
10 patients	$p < 0.001$	$p < 0.005$	$p < 0.001$	NS	$p < 0.001$	$p < 0.001$	$p < 0.001$	$p < 0.005$	$p < 0.001$	NS
Prolapse	447	151	296	0.69	1.5	5.7	1.59	37	665	225
4 patients	(±218)	(±134)	(±109)	(±0.16)	(±0.2)	(±0.8)	(±0.35)	(±6)	(±278)	(±44)
	$p < 0.001$	$p < 0.001$	$p < 0.001$	NS	$p < 0.001$	$p < 0.001$	$p < 0.001$	$p < 0.001$	$p < 0.001$	$p < 0.001$

\* Nine patients.  
Mean ± standard deviation; NS = not significant.



**Fig. 3.** A and B. Echocardiograms from two patients with mitral valve prolapse but without ruptured chordae. Both show paradoxical anterior motion of the posterior leaflet in early diastole (arrows). Note the increase CE-amplitude and DE slope.



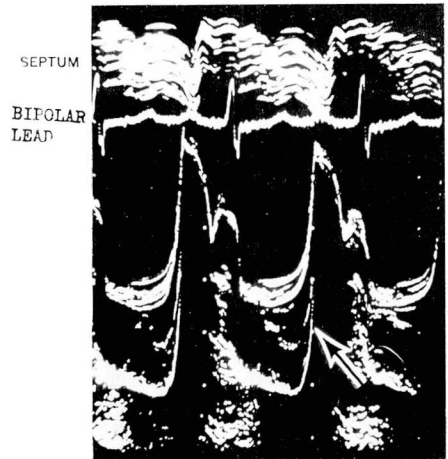The EDV in this group was considerably increased, an indication of the severity of the mitral regurgitation (Table 1). The ESV varied from normal to greatly increased (27 to 343 cm<sup>3</sup>). The SV was increased in all cases (165 to 387 cm<sup>3</sup>, mean 297 cm<sup>3</sup>). All patients had  $\Delta$ Sep >1.3 cm (mean 1.5 cm), significantly more than normals ( $p < 0.001$ ). The LA was increased in all patients (4.5 to 6.5 cm, mean 5.7 cm), although the LA/Ao relation varied from normal to increased (1.18 to 1.93, mean 1.59).

The CE amplitude of the anterior leaflet was increased in all cases (32 to 45 mm, mean 37 mm). The DE slope ranged from normal to considerably increased (320 to 1000 mm/sec, mean 665 mm/sec). The EF slope also ranged from normal to increased (160 to 260 mm/sec, mean 225 mm/sec).

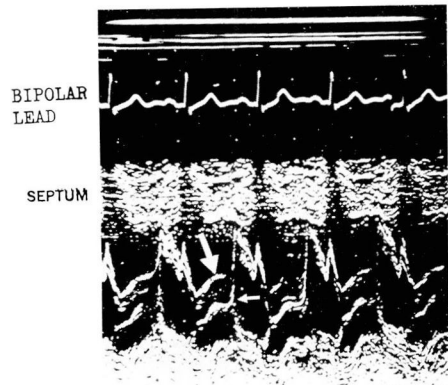
No patients in this group had more than 2 mm systolic posterior expansion of the posterior left atrial wall.

**Group III—Mitral regurgitation of questionable cause.** Figure 4 shows the mitral valve echogram from one of these two patients. Despite intact chordae tendineae, this patient had an early diastolic paradoxical anterior motion of the posterior leaflet. The second patient had an apparently normal mitral valve echogram except for greatly increased DE slope (960 mm/sec).

**Group IV—Ruptured chordae tendineae.** All patients in this group had thin leaflets with normal brightness. Paradoxical diastolic anterior motion of the posterior leaflet was seen in five cases. In Figure 5, the first CD segment shows what seems to be paradoxical anterior motion of the posterior leaflet. In the next three CD segments, the echo-labeled ante-



**Fig. 4.** Echocardiogram from a patient with severe mitral regurgitation of unknown origin. Arrow points to the paradoxical anterior motion of the posterior leaflet in early diastole. This patient had all chordae tendineae intact.



**Fig. 5.** Echocardiogram from a patient with ruptured chordae tendineae to the posterior leaflet. The second CD segment shows an interruption in the final part of the anterior leaflet (large arrow). The posterior leaflet (small arrow) is seen then reaching as far as the E point.

rior leaflet is not seen in early diastole. The echo-labeled posterior leaflet is then seen on its total amplitude reaching as far as the E point. This echo clearly comes from the anterior and not the posterior leaflet. This exemplifies the problem of recognition of the posterior leaflet during

systole, in cases of prolapse with or without ruptured chordae tendineae.

Multiple echoes were seen during the CD segment in all patients. Five had a hammock-like posterior displacement of the CD segment, three had only late systolic prolapse, and two had no abnormal posterior systolic movement and a straight CD segment.

Two different types of abnormal diastolic motion of the posterior leaflet noted in this group were not present in those with intact chordae tendineae.

The first one, seen in two patients (Fig. 6), has been described by Feigenbaum.<sup>16</sup> The posterior leaflet was quite posterior during systole. In early diastole it moved rapidly anteriorly. This rate of anterior movement was greater than the DE slope

of the anterior leaflet. In these two patients the anterior movement of the posterior leaflet did not exceed half of the CE excursion of the anterior leaflet. When an A wave was noted in the anterior leaflet in late diastole, a similar but posterior movement was seen in this abnormal posterior leaflet. The posterior leaflet remained stationary in this anterior position during diastole to move posteriorly with beginning of systole.

A second type of movement of the posterior leaflet, not previously reported, was seen in four patients. In this type, the posterior leaflet was not situated as far posteriorly during the CD segment as in the first type. During early diastole it opened normally with a posterior movement. In mid to late diastole, it slowly drifted excessively anteriorly, sometimes touching the anterior leaflet. This type of excessive diastolic anterior motion has not been observed in normal subjects. The demonstration of this phenomenon is clearly related to the duration of diastole. Figure 7 depicts an echocardiogram of a patient with this type of posterior leaflet diastolic movement and with frequent premature atrial contractions. The abnormal motion is seen only with a long diastole. In short diastolic periods, as with those associated with premature contractions, it is not recorded. The extreme diastolic anterior motion of the posterior mitral leaflet may be specific for ruptured chordae tendineae of the posterior mitral leaflet.

Three patients had ruptured chordae tendineae for both anterior and posterior leaflets. The findings of a coarse diastolic flutter of the anterior leaflets as described by others<sup>14</sup> was seen in only one patient. We did not find isolated ruptured chordae to the anterior leaflet in our series.

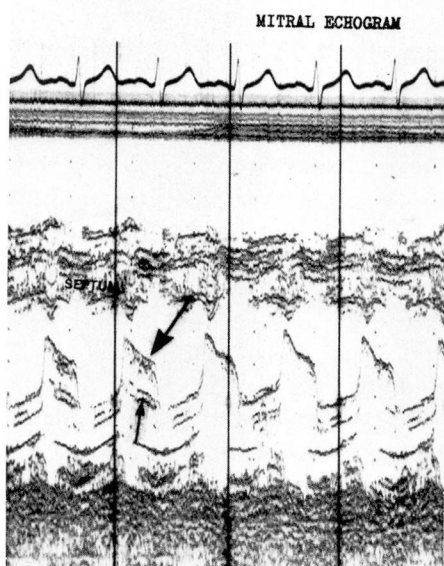
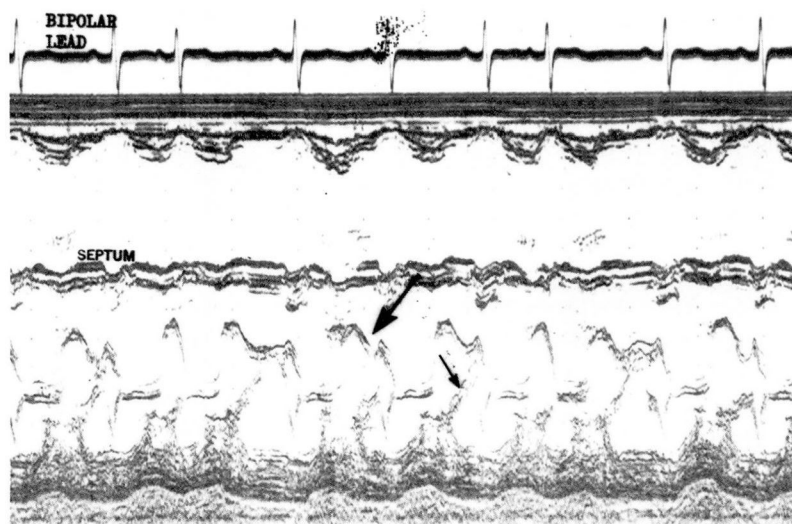


Fig. 6. Echocardiogram from a patient with ruptured chordae to the posterior leaflet. The anterior (large arrow) and posterior (small arrow) leaflets are shown. Note the fast anterior movement of the posterior leaflet in early diastole seen in the first two diastolic periods.



**Fig. 7.** Echocardiogram from a patient with ruptured chordae to the posterior leaflet. Note the excessive diastolic anterior movement of the posterior leaflet (small arrow) occasionally reaching the anterior leaflet (large arrow). This movement is not seen with short diastolic interval as those preceding a premature atrial beat.

The posterior left atrial wall had more than 2 mm of systolic posterior expansion in four patients in this group. Disclosure of a flail posterior leaflet within the left atrium was found in only one case. The EDV, ESV, SV, EF, and  $\Delta$ Sep varied from normal to increased (*Table 1*). The LA size was larger than normal in all patients (4.2 to 6.0 cm, mean 5 cm). The LA/Ao relation was increased (1.31 to 2.17, mean 1.70).

The CE amplitude of the anterior mitral leaflet ranged from normal to slightly increased (17 to 32 mm, mean 27 mm). The DE slope varied from normal to greatly increased (280 to 880 mm/sec, mean 484 mm/sec). The EF slope was normal in all cases except one where it was mildly decreased (60 to 200 mm/sec, mean 102 mm/sec). The anterior leaflet touched the interventricular septum in only two cases.

## Discussion

The diagnosis of mitral regurgitation is frequently made clinically. However, the etiologic diagnosis may be difficult. Pathologic disturbances of the papillary muscles, chordae tendineae, mitral leaflets, and annulus may cause mitral regurgitation.<sup>1, 2</sup> The natural history and prognosis vary in patients with different causes of mitral regurgitation.<sup>2</sup>

Patients with ruptured chordae tendineae are more suitable for valvuloplasty instead of valve replacement.<sup>2, 18, 19</sup> The preoperative diagnosis of this problem may permit conservative surgical treatment, since only a small percentage of these patients will need valve replacement.<sup>2, 18</sup>

Several reports have dealt with echocardiographic differential diagnosis of mitral insufficiency with various abnormalities of the mitral



valve.<sup>5-15</sup> Our study concerns certain echocardiographic findings in patients with these different forms of mitral regurgitation, and a characteristic diastolic movement of the posterior mitral leaflet is described in cases of ruptured chordae tendineae of this leaflet.

Rheumatic and nonrheumatic forms of mitral regurgitation are easily differentiated. The mitral leaflet echogram in rheumatic mitral disease is broad and bright, and it is thin in nonrheumatic mitral disorders. Echocardiograms in rheumatic mitral regurgitation resemble those obtained in mild mitral stenosis. The posterior leaflet generally moves anteriorly during diastole, synchronous with the anterior leaflet. The EF segment has characteristically two different slopes, an initially faster one followed by a plateau or a slower slope. The EF slope was usually faster than that described in tight mitral stenosis.<sup>16</sup> In fact, the slowest EF slope in our series (20 mm/sec) was encountered in a patient with no gradient across the mitral valve.

The echocardiographic differentiation of intact versus ruptured chordae tendineae in cases of nonrheumatic mitral regurgitation is more difficult. A paradoxical, early diastolic anterior motion of the posterior leaflet has been reported to be a reliable sign for ruptured chordae to this leaflet.<sup>3</sup> In our series, this sign was not helpful for establishing the diagnosis of ruptured chordae tendineae to the posterior leaflet, since it was present in four of ten of those patients with ruptured chordae tendineae and in four of six patients with intact chordae tendineae.

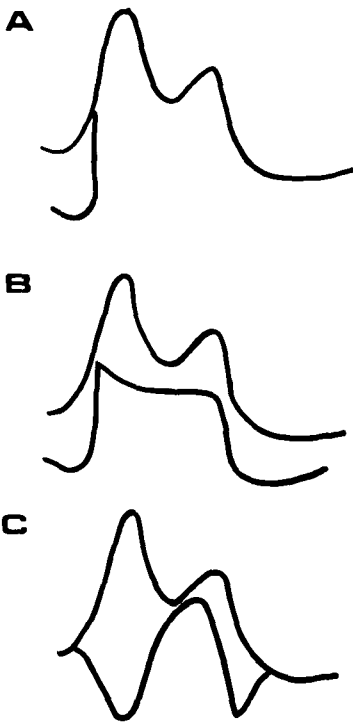
In cases of mitral valve prolapse, the echo beam may transect the leaf-

lets in several places, producing multiple echoes from one single leaflet. In certain cases where the posterior leaflet seems to have an early diastolic paradoxical anterior motion, one may be actually recording the anterior leaflet with its normal anterior movement and increased excursion. The posterior mitral displacement during systole may be caused by the lack of support from the prolapsing posterior leaflet.

*Figure 5* shows echoes which might be mistaken as the posterior mitral leaflet with a paradoxical anterior motion. This was in reality the anterior mitral leaflet. The disappearance of the anterior echoes from the second to fourth CD segment makes it possible to note that the posterior echo is continuous with the E point and is a part of the anterior and not the posterior leaflet. One would not expect the position of the posterior leaflet to be located far anteriorly.

We found two types of diastolic movements of the posterior leaflet that seem to be specific for ruptured chordae of this leaflet and these were not found in cases where the chordae were intact (*Fig. 8*).

The first type, described by Feigenbaum,<sup>16</sup> was seen in two patients (*Fig. 6*). The posterior leaflet had a rapid early diastolic anterior movement and remained in an anterior position throughout diastole with extreme posterior motion during systole (*Fig. 8 B*). It is possible that some cases of paradoxical early diastolic motion of the posterior leaflet may be part of this type of movement seen only in early diastole (*Fig. 8 A*). In this kind of movement, the posterior leaflet, or part of it, is probably in the left atrium during systole. In early diastole, it moves anteriorly and infe-



**Fig. 8.** Mitral valve movements in case of ruptured chordae to the posterior leaflet. **A**, Paradoxical early diastolic anterior motion of the posterior leaflet. **B**, Early diastolic anterior motion of the posterior leaflet. **C**, Late diastolic excessive anterior motion of the posterior leaflet.

riorly in the direction of the left ventricle. Its diastolic anterior movement could be differentiated from that seen in mitral stenosis because of its faster velocity, which is even faster than the DE slope of the anterior leaflet.

In four patients; the posterior leaflet had a normal posterior movement during early diastole followed by a slow and excessive anterior movement, sometimes reaching the anterior leaflet (*Fig. 7*). This anterior movement is slow and may be excessively anterior only by mid to late diastole (*Fig. 8C*). With short diastolic periods, as with tachycardia, this movement may not be recorded. In

patients with this kind of posterior leaflet motion, the CD segment may not show the large separation of the leaflets as described by other investigators in cases of ruptured posterior leaflets.<sup>14</sup> This kind of posterior leaflet movement probably represents the flail part of the leaflet with excessive diastolic anterior motion. This motion is due to lack of support from the chordae tendineae during left ventricular filling allowing flail diastolic movement.

Depending on the number and location of the ruptured chordae tendineae, part of the leaflet may be flail, while other locations may be relatively secure on the same valve leaflet. The echocardiographic features depend upon the ultrasonic beam location on the leaflet. Hence, one may have a variety of echocardiographic appearances simulating a normal to a deformed valve in a single patient. The demonstration of a flail posterior leaflet within the left atrium was seen in only one patient. The sensitivity of this sign is therefore poor.

In three cases there were ruptured chordae tendineae to both anterior and posterior leaflets. Only one showed a characteristic coarse fluttering of the anterior leaflet during diastole. Patients with prolapse of the mitral leaflets had greater CE amplitude ( $p < 0.01$ ) and EF slope ( $p < 0.001$ ) as compared with ruptured chordae.

Roentgenographically, the left atrium has been found to be normal or slightly enlarged in acute mitral regurgitation and significantly enlarged in long-standing regurgitation.<sup>20-21</sup> Echocardiographic measurements did not show any statistically significant difference in the left atrial size in patients who had symptoms (dyspnea on exertion, paroxys-

**Table 2.** Comparison of left atrial size (LA) and LA/Ao ratio in all patients studied with mitral regurgitation with symptoms (dyspnea on exertion, orthopnea, paroxysmal nocturnal dyspnea) for less or more than 6 months

	>6 months 11 patients	<6 months 8 patients	Significance
LA (mean ± SD)	5.6 ± 0.63 cm	5.1 ± 0.66 cm	0
LA/Ao (mean ± SD)	1.99 ± 0.51	1.64 ± 0.32	0

mal nocturnal dyspnea, orthopnea) for less than 6 months as compared with those with symptoms for more than 6 months irrespective of the etiology (*Table 2*). In addition, there was no significant difference in these two groups when EDV, ESV, and ΔSep were compared.

It is our experience that a systolic expansion of the posterior left atrial wall may be seen in normal subjects or in patients with hyperdynamic states, and is not a reliable sign of acute mitral regurgitation.

Echocardiography is a reliable noninvasive technique for the diagnosis of mitral regurgitation. Those patients with rheumatic mitral regurgitation can be easily differentiated from those with a nonrheumatic etiology. The diagnosis of ruptured chordae tendineae to the posterior leaflet can be made when the abnormal anterior motion of this leaflet is noted beyond mid-diastole. The presence of an early diastolic anterior motion of the mitral valve is not a reliable sign of ruptured chordae tendineae to the leaflet, since it is seen in 66% of patients with non-rheumatic severe mitral regurgitation with intact chordae tendineae.

Summary

The echocardiographic findings in 21 patients with severe mitral regur-

gitation secondary to rheumatic mitral valvular disease, prolapsing mitral valve leaflets, ruptured chordae tendineae, and unknown etiology are described. The diagnoses were corroborated by cardiac catheterization and surgical visualization of the mitral apparatus. Patients with rheumatic mitral regurgitation had broad echoes from the mitral valve. The EF slope varied from slow to normal (20 to 150 mm/sec). The DE slope varied from normal to increased (240 to 960 mm/sec). Patients with mitral valve prolapse with intact chordae had a hammock-like CD segment with multiple echoes. The interventricular septum had an amplitude greater than 1.3 cm, the DE slope ranged from normal to significantly increased (320 to 1000 mm/sec), and the EF slope ranged also from normal to increased (160 to 260 mm/sec). Patients with ruptured chordae to the posterior leaflet may have one of two characteristically different types of diastolic motion of this leaflet: a rapid anterior motion was noted in early diastole with the posterior leaflet remaining in an abnormal anterior position during the remaining diastolic period, or the posterior leaflet had a normal posterior movement during early diastole followed by a slow excessive anterior motion during the remaining diastolic period.

Paradoxical early diastolic anterior motion of the posterior leaflet was not a reliable sign for ruptured chordae. Only one patient with ruptured chordae to the anterior leaflet had coarse diastolic flutter of this leaflet. The left atrial size was increased in all. The CE amplitude and the DE slope varied from normal to increased (CE = 17 to 32 mm, DE = 280 to 880 mm/sec). The EF slope was normal.

Echocardiography is a reliable method for the differential diagnosis of the various etiologies of mitral regurgitation.

## References

1. Roberts WC, Perloff JK: Mitral valvular disease; a clinicopathologic survey of the conditions causing the mitral valve to function abnormally. *Ann Intern Med* **77**: 939-975, 1972.
2. Selzer A, Katayama F: Mitral regurgitation; clinical patterns, pathophysiology and natural history. *Medicine* **51**: 337-366, 1972.
3. Burgess J, Clark R, Kamigaki M, et al: Echocardiographic findings in different types of mitral regurgitation. *Circulation* **48**: 97-106, 1973.
4. DeMaria AN, King JF, Bogren HG, et al: The variable spectrum of echocardiographic manifestations of the mitral valve prolapse syndrome. *Circulation* **50**: 33-41, 1974.
5. Sweatman T, Selzer A, Kamagaki M, et al: Echocardiographic diagnosis of mitral regurgitation due to ruptured chordae tendineae. *Circulation* **46**: 580-586, 1972.
6. Giles TD, Burch GE, Martinez EC: Value of exploratory "scanning" in the echocardiographic diagnosis of ruptured chordae tendineae. *Circulation* **49**: 678-681, 1974.
7. Popp RL, Brown OR, Silverman JF, et al: Echocardiographic abnormalities in the mitral valve prolapse syndrome. *Circulation* **49**: 428-433, 1974.
8. Millward DK, McLaurin LP, Craige E: Echocardiographic studies of the mitral valve in patients with congestive cardiomyopathy and mitral regurgitation. *Am Heart J* **85**: 413-421, 1973.
9. Winters WL Jr, Hafer J Jr, Soloff LA: Abnormal mitral valve motion as demonstrated by the ultrasound technique in apparent pure mitral insufficiency. *Am Heart J* **77**: 196-205, 1969.
10. Sweatman TW, Selzer A, Cohn KE: Echocardiographic diagnosis of ruptured chordae tendineae. *Am J Cardiol* **26**: 661-662, 1970.
11. Dillon JC, Haine CL, Chang S, et al: Use of echocardiography in patients with prolapsed mitral valve. *Circulation* **43**: 503-507, 1971.
12. Kerber RE, Isaef DM, Hancock EW: Echocardiographic patterns in patients with the syndrome of systolic click and late systolic murmur. *N Engl J Med* **284**: 691-693, 1971.
13. Segal BL, Likoff W, Kingsley B: Echocardiography; clinical application in combined mitral stenosis and mitral regurgitation. *Am J Cardiol* **19**: 42-49, 1967.
14. Duchak JM Jr, Chang S, Feigenbaum H: Echocardiographic features of torn chordae tendineae. *Am J Cardiol* **29**: 260, 1972.
15. Segal LB, Likoff W, Kingsley B: Echocardiography; clinical application in mitral regurgitation. *Am J Cardiol* **19**: 50-58, 1967.
16. Feigenbaum H: Echocardiography. Philadelphia, Lea and Febiger, 1972.
17. Laniado S, Yellin E, Kotler M, et al: A study of the dynamic relations between the mitral valve echogram and phasic mitral flow. *Circulation* **51**: 104-113, 1975.
18. Gerbode F, Hill JD, Kelly JJ Jr, et al: Surgical correction of mitral insufficiency due to ruptured chordae tendineae. *Circulation* **37**: Suppl II: 119-123, 1968.
19. McGoon DC: Repair of mitral insufficiency due to ruptured chordae tendineae. *J Thorac Cardiovasc Surg* **39**: 357-362, 1960.
20. Selzer A, Kelly JJ Jr, Vannitambay M, et al: The syndrome of mitral insufficiency due to isolated rupture of the chordae tendineae. *Am J Med* **43**: 822-836, 1967.
21. Ronan JA Jr, Steelman RB, DeLeon AC Jr, et al: The clinical diagnosis of acute severe mitral insufficiency. *Am J Cardiol* **27**: 284-290, 1971.