

Percutaneous retrieval of retained common bile duct stones

Richard G. Pepe, D.O.
Thomas R. Havrilla, M.D.
Thomas F. Meaney, M.D.

Department of Diagnostic Radiology

Retained bile duct stones are still a problem in approximately 5% of postcholecystectomy patients.¹ Routine operative cholangiograms have not eliminated this problem completely, due to poor technical quality or inaccurate interpretation. Because of the morbidity and mortality of reoperation, development of low-risk procedures was encouraged for the removal of retained stones. This has been recognized since 1891, when Walker² first instilled ether into the common bile duct to dissolve stones. Since that time, other agents (chloroform,³ heparin,⁴ cholecystokinin,⁵ sodium cholate⁶) have been used in various methods with only partial success. Mondet⁷ extracted stones through a fibrous tract as early as 1962 with a specially designed forceps. However, with the availability of a steerable catheter (Medi-Tech, Inc., Watertown, Massachusetts) and a Dormia type ureteral stone basket via the T-tube tract, the non-operative removal of retained stones has become the procedure of choice. Small and moderate sized calculi up to 1 cm can be removed easily; larger stones are usually crushed and then removed. The procedure described here has been utilized on 35 patients at the Cleveland Clinic for the past 3 years with a very low inci-

dence of complication or failures. The purpose of this paper is to discuss our experience with percutaneous retrieval of retained common duct stones with modifications to handle variations in size and location.

Subjects

Between November 1972 and July 1976, 35 patients were referred to the Department of Radiology for evaluation of retained hepatic or common bile duct stones. Of these patients, at T-tube cholangiography 30 had retained stones, and five did not have retained stones (*Table 1*). In one patient, a biopsy of a filling defect in the distal common bile duct was done which later proved to be ampullary carcinoma. Another patient had decompression of the biliary tree before surgery; a third patient had a stricture in the ductal system, and removal of the stone was not technically feasible. Nine patients had multiple stones; of these, eight patients had all stones removed. One patient with two retained stones in the common bile duct had only one removed.

Technique

If retained stones are found on the postoperative T-tube cholangiogram, then percutaneous extraction should be delayed 4 to 6 weeks postoperatively so that a firm fibrous tract will

form around the T-tube. The patient with a T-tube in place is then seen in the Department of Radiology, and a T-tube cholangiogram is performed. This procedure confirms existence of retained stones and helps to define the biliary anatomy. If a stone is found, the patient is then prepared, put on the fluoroscopy table and draped. A modified sterile technique is utilized throughout the procedure. The T-tube is removed, and the polyethylene steerable catheter is then inserted through the T-tube tract. Since the steerable catheter allows remote control of the tip, passage through the tract is easily facilitated, and the tip can be directed into the region of the retained stone (*Fig. 1*). The No. 13 French catheter is 25 cm in length and has an external diameter of 4.3 mm and an internal diameter of 2.7 mm. A side port is present in the manipulator for contrast injection. The tip of the catheter is placed slightly beyond the calculus, and the Dormia type basket is then advanced through the end of the catheter and opened distal to the stone. Withdrawal of the catheter allows the stone to be engaged in the open basket (*Fig. 2*). The basket with the enclosed stone and the steerable catheter are then removed from the T-tube tract as one unit. Standard roentgenograms are then taken in the anteroposterior and both oblique positions to confirm the removal of all stones. A dressing is then placed on the patient's abdomen over the sinus tract for collection of any residual drainage.

Results

In all but two patients, retained stones were successfully removed (*Table 2*). The first failure was due to

Table 1. Hepatic or common bile duct stones found at T-tube cholangiography

No. of stones	No. of patients
0	5
1	22
2	3
3	4
4	1
	—
Total	35

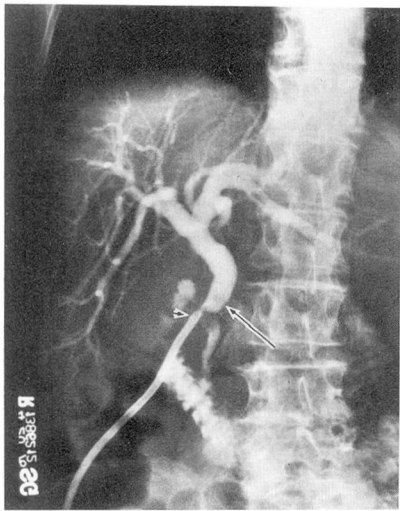


Fig. 1. Cholangiogram showing a large retained calculus in the common bile duct (long arrow). The tip of the steerable catheter is just proximal to the stone (arrow head).

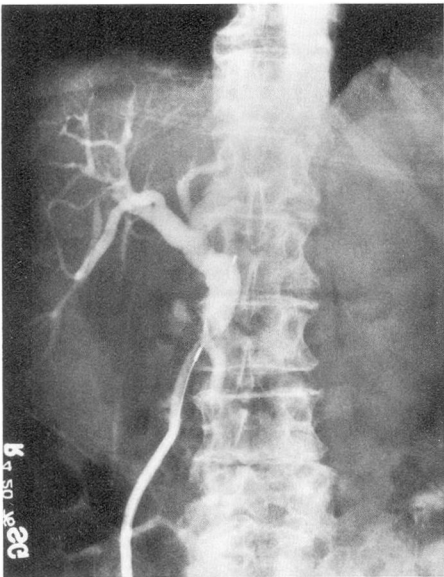


Fig. 2. The Dormia type wire basket has been advanced through the end of the catheter. The large common duct stone is snared in the loop of the basket just prior to extraction.

a stricture which prohibited passage of the catheter. The procedure was attempted a second time in the same patient without success. In the sec-

ond patient, the stone was too large to be engaged in the basket, and reoperation was necessary. The average time of the procedure was 1 hour. All patients were 6 weeks or more postoperative with some patients as long as 6 months postcholecystectomy. One patient had suspected carcinoma of the ampulla, and transcatheter biopsy of the suspected lesion was performed.

Complications

The only major complication in our series was a patient with a misplaced T-tube, and there was perforation of a false tract into the peritoneal cavity during catheter manipulation. In this patient, a cholangiogram was done immediately before the extraction procedure, but only an anteroposterior view was taken. On this view, the distal limb of the T-tube appeared to be within the common bile duct. The steerable catheter was manipulated within the sinus tract and passed through the false channel. The procedure was immediately terminated, and careful follow-up re-

Table 2. Results in 30 patients with retained bile duct stones

Location of stones	No. of patients	Removed or fragmented	Not removed
CBD	18	16	2*
CHD	3	3	
LHD	3	3	
RHD	1	1	
RHD, LHD, CBD	1	1	
LHD, CHD, CBD	1	1	
RHD, LHD	1	1	
CBD, LHD	1	1	
LHD	1	1	
Total	30	28	2

* False sinus passage with stricture; one not removed from patient with two stones.
CBD = common bile duct; CHD = common hepatic duct; LHD = left hepatic duct; RHD = right hepatic duct.
Success rate = 28/30 = 93%.

vealed no ill effects or evidence of peritonitis. In retrospect, it is advised that anteroposterior and both oblique views of the cholangiogram be obtained prior to the procedure. The oblique views most likely would have shown the distal limb of the T-tube to be outside the biliary tree (Fig. 3).

Mild pain can occur in up to 25% of the patients but usually is not a significant problem. In a personal communication in 1975 Burhenne stated that in a collective study of 612 patients there were no fatalities. A total of 33 (5%) of the 612 patients had some complication. Side effects were usually minor and disappeared within 48 hours. The reported complications were sinus tract perforations with extravasation of contrast in seven patients, subhepatic bile collections, and postextraction fever. The fever usually subsided within 48 hours after adequate antibiotic therapy. A few patients had sepsis and pancreatitis. Reoperation was required in 9% of the patients after failure of stone extraction. One patient required reoperation because a large stone was trapped in the basket and could not be extracted through the sinus tract.⁸

Discussion

The morbidity and mortality of percutaneous stone removal is much less than that encountered from reoperation of postcholecystectomy patients. A mortality rate between 2% and 4% has been reported with reoperation.^{9, 10} However, with percutaneous common bile duct stone removal, we have had a success rate of 93%. A great advantage and major reason for the reduced morbidity in these patients is related to the use of fluoroscopy for guiding the steerable

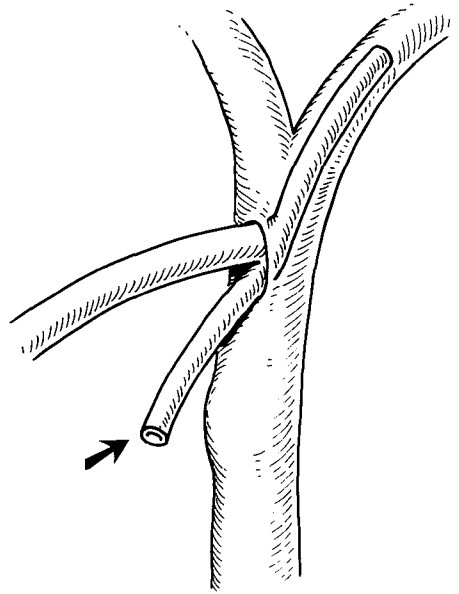


Fig. 3. Drawing of an oblique view of the common duct at its junction with the major right and left hepatic radicles showing the distal limb of the T-tube outside the biliary tract (arrow).

catheter and wire Dormia type basket. Technical problems which can occur involve the use of too small a T-tube after the initial surgical procedure with difficulty in inserting the steerable catheter. Because of this, a No. 14 French catheter or catheter of larger bore should be left in the common bile duct when there is a possibility of retained stones. Anatomic variations in the biliary tree are possible, such as accessory right hepatic ducts which occur in approximately 6% of the population.¹¹ Variations in the length and course of the cystic duct can also occur. The cystic duct can have a low union with the common bile duct or a high union inserting into a right hepatic duct or else have a very tortuous course before entering the common bile duct.

For easiest removal, it is preferable for the T-tube to be placed at a 90-

degree angle to the bile duct system and in a straight line to the lateral stab wound of the abdomen.¹² Ideally, the T-tube should be no smaller than the diameter of the No. 14 French catheter to facilitate the use of the steerable catheter. When smaller T-tubes are used, large stones may have to be fragmented during extraction through the small cutaneous tract. The steerable French catheter is available in Nos. 8, 10, and 13.

The problem of impaction of a stone in the distal duct can be solved in several ways. A guide wire and a small catheter can be inserted distal to the stone into the duodenum and the basket then fed through the small catheter. An alternate method is the use of a small Fogarty catheter, again slipping the Fogarty past the impacted stone and expanding the balloon (*Fig. 4A and B*). The stone can then be drawn out proximally.

Another effective method is the use of magnesium sulfate which has a marked dilatory effect on the ampulla almost immediately after the injection of a dilute solution. Usually, one to two ampules are diluted to a 50% solution and injected directly into the common bile duct. Dilatation of the ampulla of Vater is then noted under fluoroscopy, and usually the impacted stone can be dislodged. Often, it is difficult to distinguish air bubbles from stones or fragments. An L-shaped tube is then left in the common bile duct for several days, and the cholangiogram is repeated.

Finally, when large stones have been fractured by several manipulative techniques, the use of a "Water Pik" (Teledyne Aqua Tech, Fort Collins, Colorado) and a No. 5 French catheter greatly facilitates the flush-

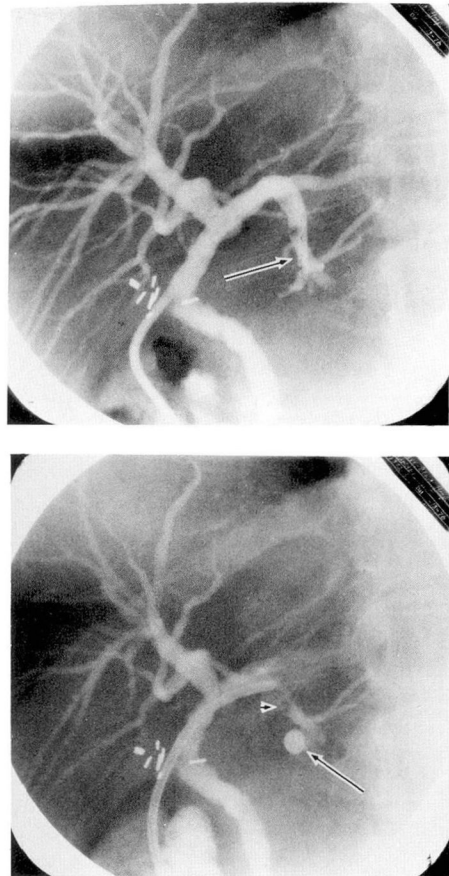


Fig. 4. **A,** With the biliary tree outlined with contrast, the tip of the steerable catheter is placed in a distal position (arrow) beyond the radiolucent stone. A small Fogarty catheter can then be advanced through the steerable catheter and, with the balloon inflated, the stone can be pulled into a more proximal position. **B,** The Fogarty balloon (arrow) is positioned beyond the stone in the left hepatic radicle. The stone (arrow head) can then be drawn proximally into the common bile duct.

ing of the small fragments retrograde through the cutaneous tract. Problems may arise in patients with very large stones which cannot be crushed, stones in small intrahepatic radicles or cystic duct remnants, and stones distal to a surgical bile duct stricture.

Summary

At the Cleveland Clinic Hospital retained bile duct stones were successfully removed percutaneously as an outpatient procedure with the steerable Medi-Tech catheter and the Dormia type wire basket. No significant morbidity or mortality was noted. When one considers the reduction of hospital costs and patient discomfort coupled with the elimination of reoperation and risks of anesthesia, the advantages of nonsurgical removal of stones are obvious.

References

1. Burhenne HJ: Nonoperative retained biliary tract stone extraction. *Am J Roentgenol Radium Ther Nucl Med* **117**: 388-399, 1973.
2. Walker JW: The removal of gallstones by ether solution. *Lancet* **1**: 874-875, 1891.
3. Semb BKH, Nordervahl Y, Halvorsen JF: Non-operative removal of retained common duct stones after biliary surgery. *Acta Chir Scand* **140**: 469-474, 1974.
4. Van Aman M, Molnar W: Nonsurgical removal of retained common bile duct stones in outpatients. *Ohio State Med J* **71**: 765-768, 1975.
5. Rosenquist H: Cited by Semb BKH, Nordervahl Y, Halvorsen JF: Non-operative removal of retained common duct stones after biliary surgery. *Acta Chir Scand* **140**: 469-474, 1974.
6. Britton DC, Gill BS, Taylor RMR, et al: The removal of retained gallstones from the common bile duct; experience with sodium cholate infusion and the Burhenne catheter. *Br J Surg* **62**: 520-523, 1975.
7. Mondet AF: Technic of blood extraction of calculi in residual lithiasis of the choledochus. *Bol Soc Cir B Air* **46**: 278-290, 1962.
8. Burhenne HJ: The technique of biliary duct stone extraction; experience with 126 cases. *Radiology* **113**: 567-572, 1974.
9. Way LW, Admirand WH, Dunphy JE: Management of choledocholithiasis. *Ann Surg* **176**: 347-359, 1972.
10. Larson RE, Hodgson JR, Priestly JT: The early and long term results of 500 consecutive explorations of the common duct. *Surg Gynecol Obstet* **122**: 744-750, 1966.
11. Grant JC: *An Atlas of Anatomy*, ed. 6, Baltimore, Williams and Wilkins Co, 1972.
12. Burhenne HJ: Nonoperative roentgenologic instrumentation technics of the post-operative biliary tract. *Am J Surg* **128**: 111-117, 1974.