

# Benign hepatic tumors and cysts in women using oral contraceptive agents

## *Computed tomography as a diagnostic aid*

Thomas R. Havrilla, M.D.  
Richard G. Pepe, D.O.  
Ralph J. Alfidi, M.D.  
John R. Haaga, M.D.

*Department of Diagnostic Radiology*

Benign hepatic tumors in women taking oral contraceptive agents have been reported in increasing numbers. Considering the number of women taking contraceptive agents, the incidence of these tumors is low. Previously, a definitive diagnosis of a benign hepatic tumor or cyst could be made only by laparotomy and open biopsy. However, with the advent of whole body computed tomography (CT) an earlier diagnosis may be possible and laparotomy for diagnostic purposes may be unnecessary. Two cases are reported and a review of the literature is included.

### **Method and equipment**

The CT scanner used in the study was the whole body Delta unit (Delta 50, Ohio Nuclear Corporation, Solon, Ohio). This scanner obtains two simultaneous 13-mm transverse slices in approximately 2½ minutes and scans in air through an arc of 180 degrees. CRT and digital display are shown on a 256-square matrix. The Delta scanner is also equipped with a color display. Other technical features have previously been described.<sup>1</sup> Respiratory motion was not limited. The patients were examined in the supine and right lateral decubitus positions follow-

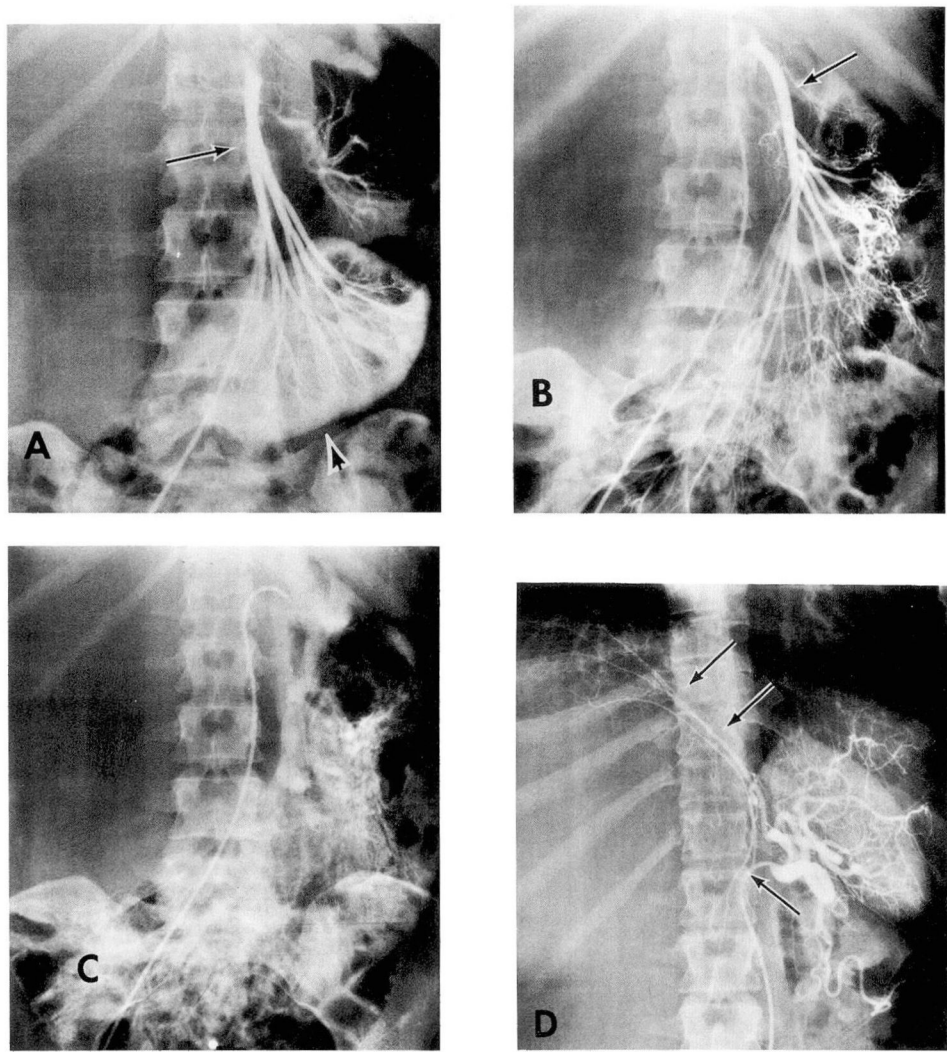
ing the intravenous administration of 100 cc Renografin 60. Early experience with contrast injection has confirmed the enhancement of the differential attenuation coefficients of normal and abnormal tissues in certain patients. In addition, a "cursor circle" can measure Delta attenuation numbers of any specific area on the CRT display. In this way, the mean density of the contents of the circle can be obtained. This is valuable in discriminating between solid and cystic components of lesions under evaluation.

### Case reports

**Case 1.** A 28-year-old woman was referred to the Cleveland Clinic because of a large liver mass found 2 months prior to admission. The patient was asymptomatic except for an increase in girth and weight. On physical examination, a large nontender mass was noted in the upper right quadrant extending to the iliac crest. The remainder of the physical examination was unremarkable and the results of laboratory studies including liver function tests were normal. The history was noncontributory except for the intake of Ovulen-21 for 21 months. B-mode ultrasound examination of the abdomen at another hospital revealed a large, echo-free volume even at high gain compatible with a liver cyst. Liver scan revealed a large filling defect in the right lobe. After admission to the Cleveland Clinic Hospital, abdominal angiography was performed and a  $35 \times 22$ -cm avascular mass was observed in the upper right quadrant displacing the right kidney to the left of midline (*Fig. 1A-D*). A CT scan of the abdomen depicted a huge mass in the upper right quadrant replacing the right lobe of the liver (*Fig. 2*). The specific density of this mass measured 0 Delta units, equivalent to water density and consistent with a fluid-filled cyst. At laparotomy, a cyst involving the entire right lobe of the

liver was found and contained 3000 cc of clear fluid. A portion of the cyst wall was left attached to the liver and opened to the peritoneal cavity for drainage. Pathologic examination revealed several focal nodules in the cyst wall. On section, these nodules contained thin-walled cysts with clear, yellow fluid. The diagnosis was cystadenoma of the liver (hepatic cyst) arising from bile ducts.

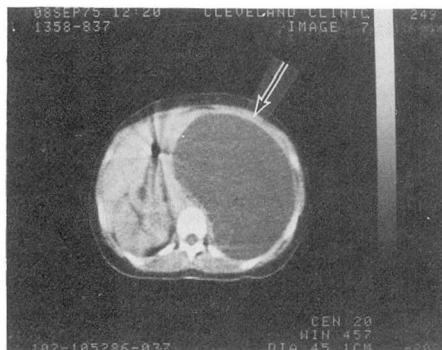
**Case 2.** A 27-year-old woman was admitted with a history of hepatomegaly and chronic cholecystitis. Pertinent drug history included the intake of Ovulen-21 for 7 years. Prior to admission, signs and symptoms of acute cholecystitis developed. Results of physical examination were normal except for a palpable liver 7 cm below the right costal margin. Laboratory findings were normal except for elevated liver enzyme levels. Plain film of the abdomen showed an upper right quadrant mass (*Fig. 3*). The oral cholecystogram revealed four large partially radiolucent stones. On the radionuclide liver scan, moderate hepatomegaly of the right lobe and the anterior left lobe was present with multiple areas of decreased activity consistent with multiple space-occupying masses (*Fig. 4*). The CT scan displayed a bulbous mass in the right hepatic lobe consistent with a normal variant or a well-differentiated neoplasm (*Fig. 5*). The tumor was of the same density as the liver and measured 50 Delta units without contrast and 90 Delta units with contrast enhancement. On exploratory laparotomy, a large hepatic adenoma measuring  $20 \times 10 \times 10$  cm was present in the right lobe. A second mass  $15 \times 10 \times 7$  cm was also present in the left hepatic lobe (in retrospect, this tumor was also seen on the CT scan). Diagnosis by frozen section was hepatic adenoma. The tumor was not resected. Cholecystectomy was performed. An intraoperative cholangiogram again demonstrated the liver mass (*Fig. 6*). Because of bleeding from the biopsy sites, a hepatic artery was ligated. Microscopic examination of the tissue segment showed a loss of the normal lob-



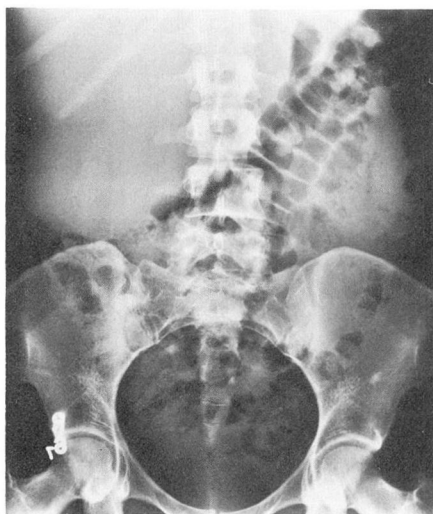**Fig. 1.** **A,** On the selective right renal arteriogram, the right renal artery (arrow) and the right kidney (arrow head) are displaced to the left of midline by a large upper right quadrant mass. **B,** Selective superior mesenteric arteriogram. On the arterial phase, the superior mesenteric artery (arrow) and its peripheral branches to the colon and jejunum are deviated to the left of midline by a large upper right quadrant mass. **C,** Selective superior mesenteric arteriogram. On the venous phase, the large upper quadrant density is displacing the colon and the small intestine inferiorly and to the left. **D,** Selective celiac arteriogram by transfemoral percutaneous catheterization again reveals the main celiac trunk and the splenic and hepatic vessels displaced to the left. The right hepatic and gastroduodenal arteries (arrows) are also displaced upward and to the left by a large right avascular hepatic mass.

ular pattern compatible with a hepatocellular adenoma. Postoperatively, the patient had fever and upper right quadrant pain. Because of a suspected liver abscess,

a repeat CT scan was performed which showed a large area of decreased density in the lower right lobe of the liver measuring approximately 30 Delta units (*Fig.*

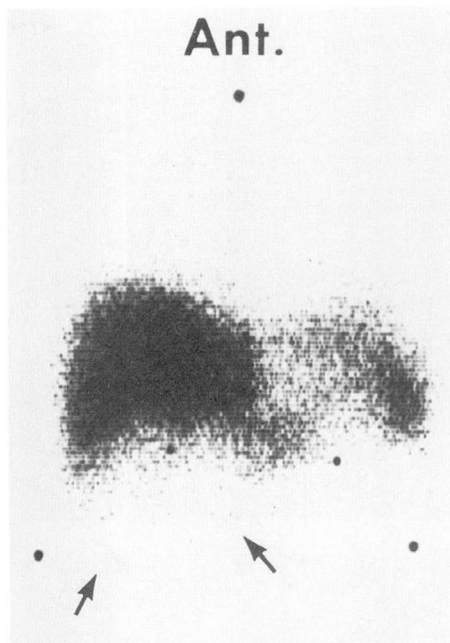


**Fig. 2.** Computed axial tomographic scan taken at level of the liver is compatible with a large cystic lesion of water density replacing almost entirely the right lobe of the liver (arrow). Reproduced by permission of Alfidi RJ, et al: The effects of biological motion on CT resolution. *Am J Roentgenol* 127:11-15, 1976.

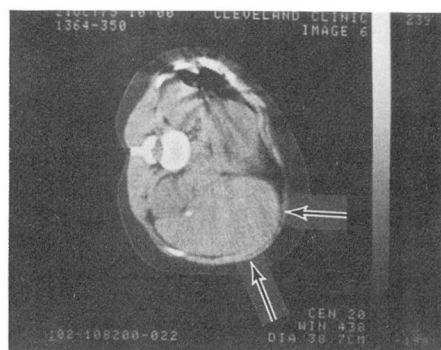


**Fig. 3.** Plain film of the abdomen reveals displacement of the right hepatic flexure and transverse colon by an enlarged right lobe of the liver or right upper quadrant mass.

7). This area of decreased density replaced the previously described bulbous area of the right lobe and resembled an abscess or necrotic hematoma. At reoperation, a large hematoma with necrosis of the hepatic adenoma was demonstrated and confirmed by biopsy. A drainage procedure was performed; postopera-

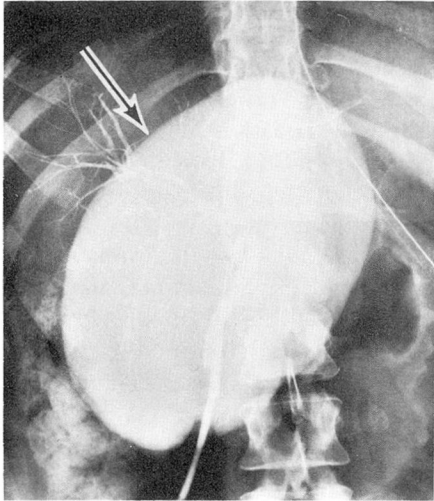


**Fig. 4.** Liver scan was obtained using 4mCi of  $Tc^{99m}$  sulfur colloid. Moderate hepatomegaly was evident involving the lower aspect of the right lobe and also the left lobe anteriorly. These areas had discrete margins and were compatible with space-occupying masses (arrows).



**Fig. 5.** CT scan of the liver in the right lateral decubitus position was compatible with bulbous enlargement of the right lower lobe of the liver. This was a nonspecific finding and could be a normal variant or a secondary to a low grade hepatoma or adenoma. The Delta numbers were consistent with normal liver parenchyma.





**Fig. 6.** On the operative cholangiogram, the biliary tree is visualized through the hepatic mass and is patent without evidence of calculi or obstruction. Contrast was seen within the duodenum on subsequent films. The large hepatic mass is well outlined as a large ovoid density (arrow) because of an air-tissue interface about the mass in the operative field. The mass itself is not filled with contrast.

tively, the patient did well and was discharged from the hospital 11 days later.

**Discussion**

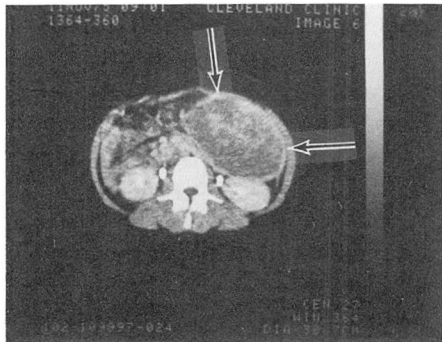
Several reports of benign hepatic tumors in women taking oral contraceptives have been published in recent years. Horvath et al,<sup>2</sup> in 1972, reported a case of well-differentiated hepatoma in a 28-year-old woman who had taken oral contraceptives for 7 years. In addition, seven cases of hepatic adenoma were also reported in 1973.<sup>3</sup> All these women were taking oral contraceptives. The possible relationship of hepatomas in women who use an oral contraceptive was suggested in a report by the committee on Safety of Medicine.<sup>4</sup> Many variables, however, can affect the assessment of the carcinogenesis of oral

contraceptives, and more study is needed.

Liver adenomas and cystadenomas are rare. Until 1972, 76 cases of benign lesions of the extrahepatic ducts, excluding the ampulla of Vater, were reported.<sup>5</sup> In a study done by Malt et al,<sup>6</sup> at the Massachusetts General Hospital between 1947 and 1968, there were 26 cases of benign tumors of the liver. Of these 26 cases, four hepatoadenomas and seven cysts were present.

Hepatic cysts are rare and are more often found in children than in adults. Causes of acute symptoms are secondary to intracystic hemorrhage, intraperitoneal rupture, or abscess formation. A cystic hamartoma of the liver in an adult can be an acute abdominal emergency simulating a perforated duodenal ulcer.<sup>7</sup>

Until recently, a diagnosis of cystic liver could only be made definitively by laparotomy, which also had the advantage of affording immediate treatment. Some investigators advo-



**Fig. 7.** CT scan done postoperatively at the level of the liver now reveals a large area of decreased density present in the lower right lobe of the liver in the previously described region of the adenoma (arrows). This finding was consistent with an abscess or necrotic hematoma with a density measurement of 30 Delta units.

cate aspiration biopsy and others peritoneoscopy.<sup>8</sup> Also at one time, Thorotrast given intravenously was suggested as a means of diagnosis. At angiography, hepatic cysts are usually avascular structures with vascular displacement of normal vessels.<sup>9</sup> These vessels form a smooth curve about the cyst. The venous hepatogram usually shows a large radiolucent defect.

CT scanning is accurate in cyst versus solid tumor identification and differentiation. In a comparison study between the detection of lesions by CT scan and radionuclide liver scans, CT was found to be equally accurate.<sup>10</sup> Density determinations provide an appraisal of the tumor substance without surgical intervention, because the density values are very precise in differentiating between parenchymal masses and cysts. With utilization of the CT cursor, cystic lesions usually measure 0 to 10 Delta units and rarely exceed 20 Delta units (0 Delta units equal the density of water). In contrast, tumor masses usually measure 30 to 50 Delta units after contrast enhancement while normal liver parenchyma with contrast enhancement measures approximately 90 Delta units. Therefore, CT scanning offers a noninvasive source of valuable data of clinical importance. CT may be limited in diagnosing a small, solid hepatic tumor of the same density as liver parenchyma.

Through the years, different types of treatment have been suggested for benign hepatic tumors and cysts. Primary resection has been advocated because of the previously described complications. If a cystic structure is noted, marsupialization or irrigation with coagulating fluids is possible.

Excessive bleeding at operation may be difficult to control, and a hepatic lobectomy may be necessary.<sup>8, 11</sup> Galloway et al<sup>12</sup> reported four cases of "minimal deviation hepatoma," a tumor of atypical cells with a relatively benign course. One patient was taking oral contraceptives. The tumor was classified as an intermediate stage between adenoma and hepatoma. Because 4 of 19 previous patients died after attempted radical resection, limited resection combined with chemotherapy was suggested to reduce operative mortality.

It is hoped that with some of the sophisticated CT refinements anticipated, nonsurgical diagnosis will soon become a reality. CT guided needle aspiration may lessen the need for laparotomy as a primary means of definitive diagnosis in selected cases. The advantage of accurate needle localization should facilitate drainage of the fluid when a cyst is found. As previously mentioned, irrigation with a coagulating fluid could be performed to help eliminate recurrence of the cysts.

CT is an accurate method for performing percutaneous biopsies and aspiration procedures and is the imaging modality of choice.<sup>8</sup> With aspiration, a definitive preoperative cytologic diagnosis can be made. The accuracy is directly related to the localization of the needle path and the precise location of the needle tip. Since the scan thickness is only 13 mm, an exact three dimensional position of the needle tip can be obtained. To date, a cystic liver was aspirated by CT guidance in only one patient. In this patient, clear cyst fluid was obtained from several cysts within the liver; and the diagnosis of polycystic renal and liver disease was con-

firmed. CT guided biopsies have also been performed on retroperitoneal masses, pulmonary and pleural lesions, renal cysts and tumors, liver abscesses, hematomas, and metastasis. In addition, percutaneous transhepatic cholangiograms, aspiration of a urinoma, biopsies of bone and pancreas have been performed. Therefore, if a cystic lesion is present and the density approximates water density, the diagnosis is almost pathognomonic. This information in conjunction with a CT guided aspiration will confirm the diagnosis.

### Summary

Primary benign adenomas and cystadenomas of the liver are rare, but the number of reported cases is increasing. The majority of patients are women taking oral contraceptives, and the incidence seems to be more than coincidental. The use of CT scanning has been helpful in preliminary studies to differentiate cysts from solid tumors. CT coupled with aspiration may alleviate the need for a laparotomy for a definitive diagnosis in certain cases.

### References

1. Alfidi RJ, Haaga JR, Meaney TF, et al: Computed tomography of the thorax and

- abdomen; a preliminary report. *Radiology* **117**: 257-264, 1975.
2. Horvath E, Kovacs K, Ross RC: Ultrastructural findings in a well-differentiated hepatoma. *Digestion* **7**: 74-82, 1972.
3. Baum JK, Bookstein JJ, Holtz F, et al: Possible association between benign hepatomas and oral contraceptives. *Lancet* **2**: 926-929, 1973.
4. Lingeman CH: Letter: Liver-cell neoplasms and oral contraceptives. *Lancet* **1**: 64, 1974.
5. Hossack KF, Herron JJ: Benign tumors of the common bile duct; report of a case and review of the literature. *Aust NZ J Surg* **142**: 22-25, 1972.
6. Malt RA, Hershberg RA, Miller WL: Experience with benign tumors of the liver. *Surg Gynecol Obstet* **130**: 285-291, 1970.
7. Gough AS, Pike C: Cystic hamartoma of the liver in an adult presenting as an abdominal emergency. *Br J Surg* **50**: 342-343, 1962.
8. Grime RT, Moore T, Nicholson A, et al: Cystic hamartomas and polycystic disease of the liver. *Br J Surg* **47**: 307-313, 1959.
9. Alfidi RJ, Rastogi H, Buonocore E, et al: Hepatic arteriography. *Radiology* **90**: 1136-1142, 1968.
10. Alfidi RJ, Haaga JR, Havrilla TR, et al: Computed tomography of the liver. *Am J Roentgenol* **127**: 69-74, 1976.
11. Larsson-Cohn U, Stenram U: Liver ultrastructure and function in icteric and non-icteric women using oral contraceptive agents. *Acta Med Scand* **181**: 257-264, 1967.
12. Galloway SJ, Casarella WJ, Lattes R, et al: Minimal deviation hepatoma; a new entity. *Am J Roentgenol* **125**: 184-192, 1975.