

# Hereditary hypertrophic neuropathy combining features of tic douloureux, Charcot-Marie-Tooth disease, and deafness

Robert P. Cruse, D.O.  
John P. Conomy, M.D.  
Asa J. Wilbourn, M.D.  
Maurice R. Hanson, M.D.

*Department of Neurology*

Hereditary hypertrophic sensorimotor polyneuropathy combining the features of Charcot-Marie-Tooth disease, trigeminal neuralgia, and deafness occurred through four generations of a family originating in Haywood County, North Carolina. Fourteen individuals had pes cavus, distal muscle atrophy, depressed or absent muscle stretch reflexes, cutaneous sensory deficits, and defective proprioception. Six family members had recurrent, lancinating, trigeminal pain, and seven were deaf. The family was brought under scrutiny when the propositus, a 60-year-old woman, was examined for treatment of tic douloureux. Neurologic information was ultimately obtained regarding 52 family members. No history of consanguinity could be ascertained within this kinship. The genealogy of the family we studied is presented in *Figure 1*. In addition to clinical neurologic examinations, electromyographic and nerve conduction studies were obtained on those individuals indicated in the genealogy diagram. Audiometric studies were obtained when there was clinical indication of defective hearing. Quantitative cutaneous sensory testing was obtained in the propositus.

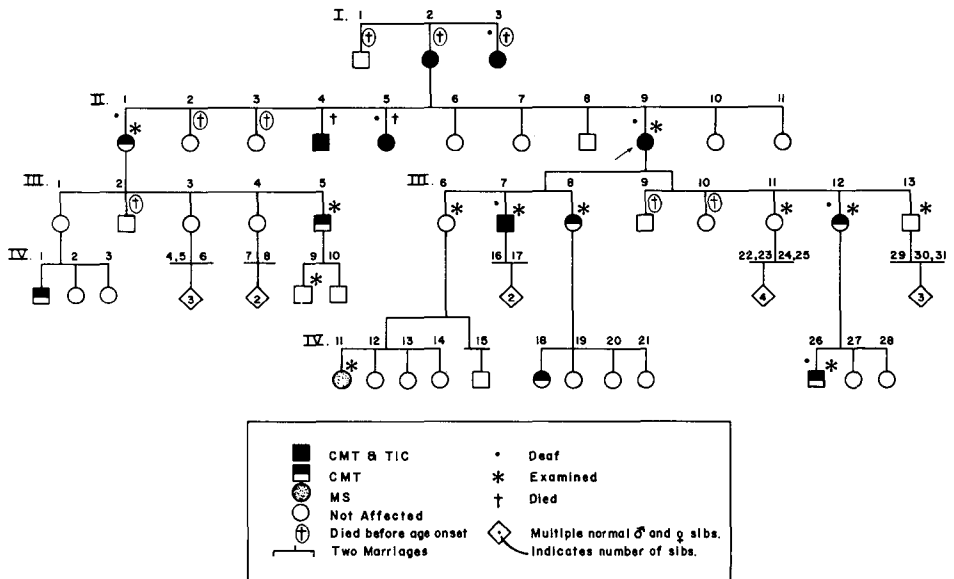


Fig. 1. Hereditary neuropathy with features of Charcot-Marie-Tooth disease, tic douloureux, and deafness.

## Case reports

**Case 1.** This 60-year-old woman, complaining of facial pain, was examined in October 1975. Pes cavus was present from childhood and she admitted a slowly progressive disturbance of gait throughout her life. She first experienced left maxillary division tic douloureux at age 41. Recurrent and progressively severe facial pain was treated unsuccessfully with numerous medications, peripheral nerve blocks, and acupuncture. In 1962 she underwent intracranial section of the maxillary division of the left fifth cranial nerve. Surgical procedure produced anesthesia in her face in an appropriate distribution, but relief of pain was only temporary, and tic douloureux returned in a few months. She became aware of hearing loss at age 47, which was progressive up to the time that she was examined. Examination disclosed atrophy of the left masseter and temporalis muscles and synkinetic movements of the left side of her face. The left pupil was slightly larger than the right, and there was diminution of the left corneal reflex in addition to

defective appreciation of pain, temperature, and light touch sensation confined to the second division of the left fifth cranial nerve. Hearing was diminished bilaterally. She further displayed moderate peroneal muscle atrophy and pes cavus. Muscle stretch reflexes were hypoactive in her arms and absent in her legs. There was mild weakness of intrinsic muscles of the hands and feet and of the muscles of the anterior and posterior tibial compartments bilaterally. These findings were associated with a polyneuropathic cutaneous sensory loss in her limbs. Her peripheral nerves were not enlarged to palpation.

Cerebrospinal fluid protein was 116 mg/dl and other spinal fluid studies were normal. An audiogram revealed severe sensorineural deafness with poor speech discrimination. An audiogram performed in 1957 had showed only mild bilateral hearing loss. Electromyographic and nerve conduction studies showed no sensory-evoked responses in her distal limb nerves. Motor conduction studies of the peroneal, ulnar, and median nerves showed severely slowed motor conduc-

tion velocities ranging from 19 to 22 m/sec (normal 40–70 m/sec). Motor nerve responses could not be obtained in the legs. Needle electromyography revealed severe, chronic denervation atrophy with minimal fibrillations in distal muscles. Quantitative cutaneous sensory testing was performed according to the method of Conomy and Barnes (Fig. 2). These studies showed distal-proximal detection gradients, threshold elevations and diminished cycling frequencies, all of which were consistent with cutaneous polyneuropathic involvement.<sup>1, 2</sup>

A left sural nerve and gastrocnemius muscle biopsy was performed and the tissues were subjected to neuropathologic examination. Peripheral nerve tissue showed severe myelin loss with relative axonal preservation. Electron microscopic studies confirmed Schwann's cell membrane hyperplasia, severe demyelination, and abortive remyelination. The muscle biopsy specimen showed changes consistent with chronic denervation which was confirmed by further histochemical study of the tissue.

The patient's tic douloureux has been effectively controlled with doses of carba-

mazepine ranging from 800 to 1200 mg/day.

**Case 2 (I-2).** The mother of the propositus was the first family member known to be affected by this illness. She had a staggering gait in childhood which progressed to incapacitation later in life. She first experienced facial pain at age 51 and died at age 79 of an unknown cause.

**Case 3 (I-3).** This woman had unilateral paroxysmal facial pain, deafness, and staggering gait.

**Case 4 (II-4).** This man had the onset of unilateral tic douloureux at age 35. He had high-arched feet, progressive gait disorder, loss of muscle stretch reflexes, and sensory defects in his legs. He died at age 55 reportedly of cerebral infarction.

**Case 5 (II-5).** This woman had the onset of left-sided tic douloureux at age 46. She had bilateral pes cavus and gait difficulties. She died at age 66 of complications of intracranial surgery performed in an effort to relieve her facial pain.

**Case 6 (II-1).** This 51-year-old woman was known to have a club foot from birth. Her examination showed mild distal muscle wasting and diminished stretch reflexes. Electromyographic studies

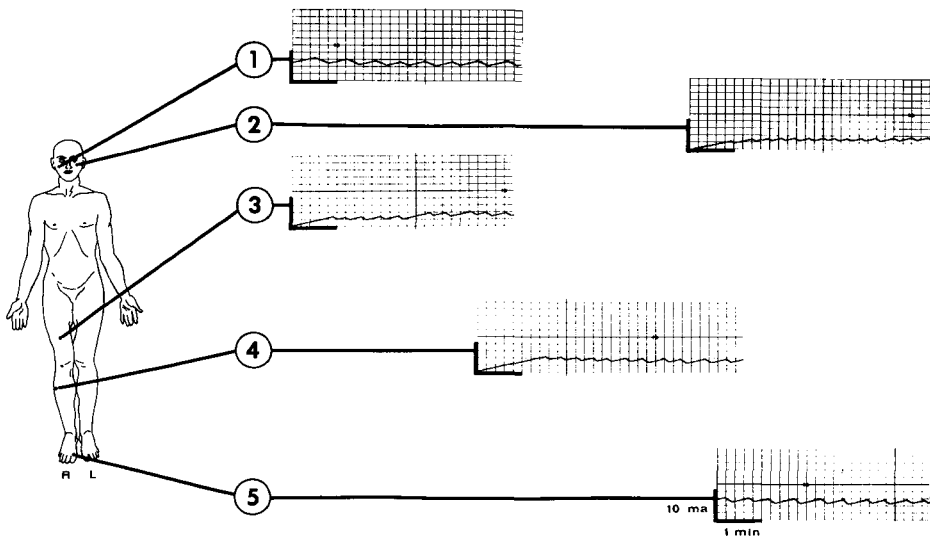


Fig. 2. Sensorimotor neuropathy – tic douloureux.

showed a mixed sensorimotor abnormality of the peripheral nerves in the limbs.

**Case 7 (III-5).** This 33-year-old man had a history of "weak ankles" while in military service. He had pes cavus, depressed muscle stretch reflexes, and electromyographic and nerve conduction studies consistent with a disorder of the peripheral nerves.

**Case 8 (III-12).** This 33-year-old woman complained of gait difficulty and mild deafness. She had high-arched feet and depressed stretch reflexes. Electrophysiologic studies revealed a mixed sensorimotor polyneuropathy.

**Case 9 (III-7).** This 47-year-old man first experienced left-sided tic douloureux at age 30. He complained of impaired coordination since childhood and had progressive deafness beginning in his early 30s. Clinical and electrophysiologic examination confirmed impairment of the peripheral nerves of the type seen in the other family members. Audiometry confirmed a sensorineural hearing loss.

**Case 10 (III-8).** This 43-year-old woman was known to have bilateral pes cavus. She was not examined.

**Case 11 (IV-26).** A 6 $\frac{1}{2}$ -year-old boy showed mild pes cavus deformity bilaterally. Audiometry disclosed bilateral conductive hearing loss with no evidence of sensorineural abnormality. Electrophysiologic studies disclosed a mixed sensorimotor polyneuropathy.

**Case 12 (IV-18).** This 23-year-old woman was reported to have bilateral pes cavus and absent stretch reflexes.

**Case 13 (IV-1).** This 15-year-old boy was reported to have high-arched feet.

**Case 14 (IV-9).** This 6 $\frac{1}{2}$ -year-old boy had high-arched feet, but at this point has not undergone an entirely normal neurologic examination. Electromyogram and nerve conduction studies have been normal.

**Case 15 (IV-2).** This 23-year-old woman was found to have transient intranuclear ophthalmoplegia and optic neuritis. Spinal fluid gammaglobulin was elevated at 21 mg/dl. Her electromyographic

studies were normal. She was believed to have multiple sclerosis and had no evidence of familial disease.

## Discussion

Hereditary hypertrophic neuropathy, confirmed by histopathologic examination in the proband of this report, is rarely seen in association with cranial nerve involvement. The findings in the family we report are reminiscent of the combination of findings seen in Helsing's syndrome,<sup>3-5</sup> but because of the detection and confirmation of hypertrophic polyneuropathy, we believe this family to be a unique, phenotypic variant of familial hereditary neuropathic disease. Deafness seems to set these patients apart from those patients originally reported by Helsing and other investigators. The family we studied shows a familial illness with sensorineural deafness, trigeminal neuralgia, pes cavus, and a distal sensorimotor polyneuropathy. Pes cavus was frequently noticed in infancy, and the deafness occurred in later childhood or in adult life. Tic douloureux, present in six family members, was always of early adult onset in contrast to idiopathic trigeminal neuralgia which is usually a disease of old age. As with idiopathic trigeminal neuralgia, we achieved beneficial therapeutic response with the administration of carbamazepine. Electrophysiologic studies showed a generalized and mixed sensory and motor neuropathy of segmental demyelinating type with physiologic involvement of the seventh and eighth cranial nerves. Pathologic examination in one patient disclosed a demyelinating neuropathy accompanied by hypertrophy of Schwann's cell membranes suggesting that the biochemi-

cal basis of this disease resides in altered Schwann's cell metabolism. The genealogic studies are suggestive of a dominant autosomal inheritance with variable penetrance. The elevated cerebrospinal fluid protein level in the patient we studied suggested that the hypertrophic polyneuropathic disease in this family had an abnormal laboratory finding in common with that in other hypertrophic neuropathies, including Dejerine-Sottas disease and Refsum's syndrome.

#### Acknowledgment

We thank Dr. Marta Steinberg for her assistance and advice in the study of this family.

#### References

1. Conomy JP, Barnes KL: A technique for the quantitative assessment of cutaneous sensory function in subjects with neurologic disease. *Trans Am Neurol Assoc* **99**: 83-87, 1974.
2. Conomy JP, Barnes KL: Quantitative assessment of cutaneous sensory function in subjects with neurologic disease. *J Neurol Sci* **30**: 221-235, 1976.
3. Helsing G: Hereditärer Facialiskrampf. *Acta Med Scand* **73**: 526-537, 1930.
4. Lundberg PO, Westerberg CE: A hereditary neurological disease with facial spasm. *J Neurol Sci* **8**: 85-100, 1969.
5. Kalyanaraman K, Smith BH, Schlagenhauff RE: Hereditary hypertrophic neuropathy with facial and trigeminal involvement; report of a case and comments on its possible identity with Helsing syndrome. *Arch Neurol* **31**: 15-17, 1974.