

Toxic megacolon – unusual complication of pseudomembranous colitis

Thomas Hoogland, M.D.
Avram M. Cooperman,
M.D.

Department of General Surgery

Richard G. Farmer, M.D.

Department of Gastroenterology

Victor W. Fazio, M.D.

*Department of Colon and Rectal
Surgery*

Pseudomembranous colitis (PMC) is a severe inflammatory disease process that affects the gastrointestinal tract. It was first described as a postoperative complication by Finney¹ in 1893. The name is derived from a thick tenacious membrane that coats the lumen of the bowel and consists of fibrin, leukocytes, and microorganisms. The severity of the illness varies from mild and clinically undetected to fulminating and fatal.

Rarely will PMC have presenting symptoms or simulate toxic megacolon. An experience with two fatal postoperative cases has prompted this report and a review of previously published cases (*Table*).

Case reports

Case 1. A 69-year-old woman with a rectosigmoid tumor was admitted to the Cleveland Clinic Hospital on September 3, 1975. The preoperative proctoscopic biopsy specimen of this lesion revealed atypical cells. Results of physical examination and all laboratory tests (complete blood count, SMA-12, SMA-6, ECG, chest roentgenogram, spirometry, and arterial blood gases) were normal. At surgery a Meckel's diverticulum and benign sessile polypoid lesion of the colon were excised. Postoperatively, her progress was satisfactory until a symptomatic urinary tract infection (enterococcus, 100,000 colonies/ml) developed on the sixth postoperative day; the infection was treated with ampicillin, 500 mg orally, four times a day for 6 days.

Table. Summary of the five published cases of toxic megacolon complicating PMC

Authors	Underlying condition	Antibiotic used before onset of toxic dilatation	Treatment at stage of megacolon	Outcome
Brown et al ²³	Otitis media	Tetracycline, novobiocin, chloramphenicol, cephalothin	Lactobacillus granules, digitalis, steroids, methicillin	Satisfactory after 1 mo
Ecker et al ⁵ 1970	Sinusitis	Lincomycin	Donor feces enemas, ACTH, cardiotonics, vancomycin	Satisfactory after several months
Wells et al ²⁴	Not stated	Clindamycin	Not stated	Fatal
Hoogland et al Case 1	Postoperative, resection of colonic polyp	Kanomycin, ampicillin	"Blowhole" transverse colostomy and loop ileostomy, methicillin, chloramphenicol, cardiotoxic drugs, steroids	Fatal
Hoogland et al Case 2	Postoperative, total hip replacement	Lincomycin	Ascending and transverse colon "blowhole" colostomy, vancomycin, cephalothin, cardiotonics	Fatal

On the 12th postoperative day, loose, watery green stools were passed, a rectal temperature of 101F and white blood cell count (WBC) of 21,600 mm³ were recorded. Ampicillin was discontinued. A Gram stain and stool culture for aerobic and anaerobic bacteria revealed normal flora. Treatment was symptomatic and consisted of diphenoxylate (Lomotil) tablets and yogurt. The clinical course was stable for the next 4 days although the diarrhea continued. On the 17th postoperative day she became lethargic. At this time a distended abdomen was noted. Laboratory data, previously normal, now revealed hemoconcentration (hematocrit 52%), an elevated blood urea nitrogen (BUN) of 62 mg/dl (normal 15 mg/dl), and a creatinine of 3.1 mg/dl. An abdominal roentgenogram revealed a dilated and gas-filled colon and rectum. The

patient became hypotensive, and Ringer's lactate (5 liters) and colloid (100 g albumin) administered intravenously restored a depleted central volume. Proctoscopic examination revealed a diffuse, thick confluent pseudomembrane adherent to the rectal mucosa. A repeat abdominal roentgenogram revealed colonic dilatation to 12 cm (*Fig. 1*). Methicillin, 1 g; chloromycetin, 250 mg; and methylprednisone, 300 mg, were each given intravenously every 6 hours. Eighteen hours later the abdomen became more distended. Tachypnea and dyspnea as well as hypotension developed. The patient underwent a decompressive "blow hole" transverse colostomy and "loop ileostomy" in the hope of decompressing the colon and reducing the sepsis.

Postoperatively she became anuric, and metabolic acidosis and septic shock

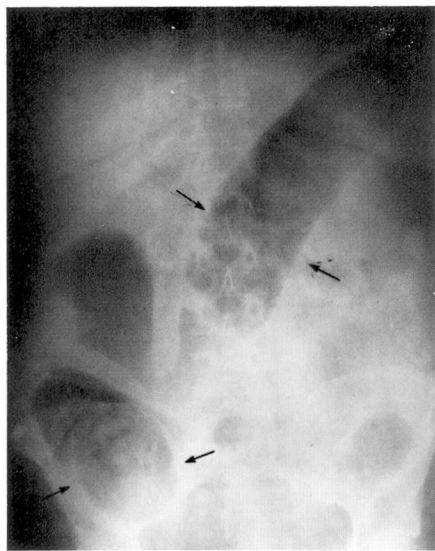


Fig. 1. Roentgenogram shows dilated cecum and transverse colon.

developed. The WBC rose to 55,000 mm^3 . Hypotension, bradycardia, and premature ventricular contractions developed, and she did not respond to intravenous fluids and cardiotonic drugs. She died 15 hours after operation.

At autopsy the entire colon revealed a diffuse confluent pseudomembrane that was adherent to the colonic wall. The pseudomembrane showed leukocytes, goblet cells, gram-positive cocci and gram-negative rods. The process extended into the submucosa and did not involve the deeper layers. There was no involvement of the small bowel or other abdominal organs.

Case 2. A 62-year-old man with osteoarthritis of the right hip was admitted to the Cleveland Clinic Hospital on November 17, 1974, for a right total hip replacement. He had a history of episodes of mild gout, hypertension, obesity, and an allergy to penicillin. An anal fissure had been excised in 1960.

On November 18, 1974, he received a Charnley-Müller right total hip prosthesis. Prophylactic postoperative antibiotics consisted of lincomycin, 600 mg

intravenously every 6 hours for 3 days and then orally, 500 mg four times a day for 3 days. On the first postoperative day the temperature was 103°F and the chest roentgenogram, WBC, and blood cultures were normal. For the next 2 days the temperature was normal. On the fifth and sixth postoperative days two liquid stools were passed. The rectal temperature was 100°F.

On the evening of the sixth postoperative day, hypotension, abdominal distension, and dehydration were apparent. An abdominal roentgenogram showed marked gaseous distension of the entire colon to 14 cm (Fig. 2). Proctoscopic examination revealed an erythematous rectal mucosa with a thick yellow membrane coating the entire rectum.

A diagnosis of PMC with megacolon was made. A Gram stain of the stool showed normal flora. Stool cultures were negative for *Staphylococcus* and *Salmonella* but positive for two strains of *Escherichia coli*. Both strains were resistant to all tested antibiotics. The cultures also revealed *Klebsiella pneumoniae* sensitive to clindamycin and enterococci resistant to clindamycin.

Blood cultures revealed *E. coli* resistant to all tested antibiotics. The WBC was elevated at 36,000/ mm^3 . The BUN was 96 mg/dl. The serum creatinine was 5.6 mg/dl. These values had been normal 3 days earlier. Six liters of colloid and Ringer's lactate were given intravenously and the central venous pressure was maintained at 10 cm H_2O . Through a Levin tube, 1 g vancomycin was given every 4 hours, and cephalothin (Keflin), 2 g intravenously every 4 hours. During the next 12 hours the abdomen became more distended, the WBC rose to 52,000 mm^3 , and the abdominal roentgenogram showed progressive distension of the entire colon. The patient was brought to surgery and under local anesthesia an ascending and transverse "blow hole" colostomy was made. Approximately 2000 cc of purulent, malodorous material was drained, and a biopsy specimen of the

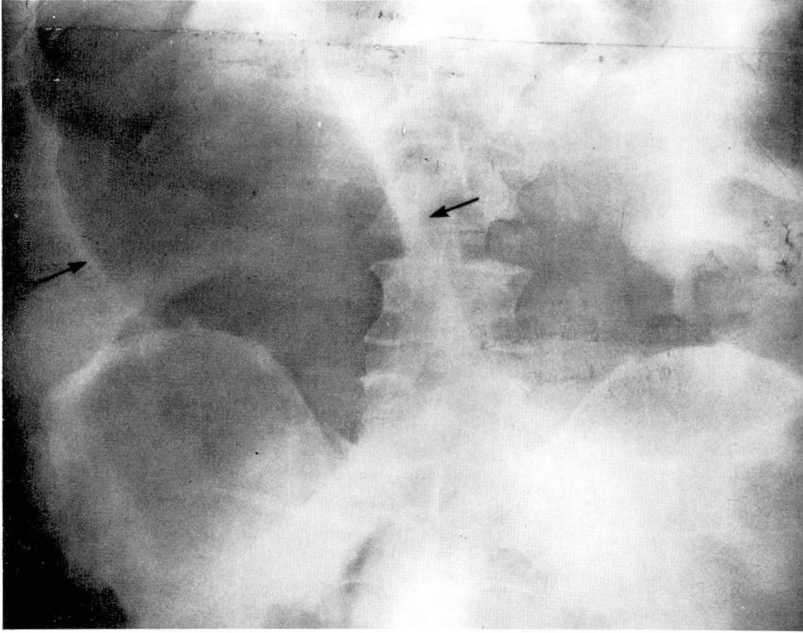


Fig. 2. Severe dilatation of cecum outlined by arrows.

colon wall showed PMC.

Postoperatively the patient's condition deteriorated. A right pleural effusion was drained and 1900 cc of serous fluid was obtained. Intubation was necessary and anuria developed. The WBC rose to 82,500 mm³. Subsequently hypotension and bradycardia developed which remained refractory to cardiotonic drugs. The patient died 72 hours after surgery.

An autopsy revealed severe PMC of the entire colon including a 2- × 2-cm hamartomatous polyp in the mid-colon. The purulent, crusty, yellow-tan pseudomembrane was firmly adherent to the colon wall. The colon wall was mildly thickened and edematous. No areas of friability or obvious necrosis within the bowel wall or mesentery were present. There was no involvement of small intestine or other abdominal organs.

Microscopically the pseudomembrane showed many leukocytes, necrotic debris, fibrin, goblet cells, and many gram-positive and gram-negative bacteria (*Fig. 3*).

Discussion

Although PMC has been recog-

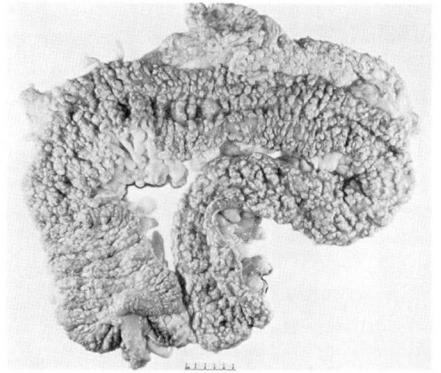


Fig. 3. Pseudomembrane and polypoid lesions on the gross specimen at necropsy.

nized for 84 years, there has been no agreement regarding its pathogenesis, incidence, and treatment. Factors predisposing to this process include postoperative states,^{2,3} intestinal obstruction, colon surgery,³ sepsis, cardiac disease,⁴ staphylococcal overgrowth of the bowel, and antibiotics.⁵ Rarely will PMC develop in the absence of any of these factors.⁶ In the past few years nearly all re-

ported instances have followed the use of antibiotics. The antibiotics included ampicillin, tetracycline, chloramphenicol, lincomycin and its chlorodeoxy analogue, clindamycin.⁷⁻¹³ Despite the numerous reports incriminating antibiotics, it is difficult to prove that antibiotics alone are responsible for the development of PMC, since infection and other factors that dictate the need for antibiotics may themselves be factors in the development of this process.

For example, Pettet et al¹⁴ compared the incidence of postoperative PMC at the Mayo Clinic in two 14-year periods. The incidence of PMC was similar before (1925-1938) and after (1938-1952) antibiotics were introduced. During the latter period an increased awareness of the entity led to a correct premortem diagnosis in 14 of 26 cases.

As antibiotics became more widely used, particularly in bowel preparation, a number of reports showed that staphylococcal overgrowth was responsible for "enterocolitis."¹⁵ Even then, despite vigorous supportive treatment, a mortality rate of 91% was not uncommon in severely ill patients.¹⁶ As antibiotic preparation of the bowel became modified so that shorter preparations were used, enterocolitis became less common.

Although diarrhea follows the use of antibiotics in 10% to 50% of cases, PMC develops much less frequently.¹⁷ In one prospective study, a proctoscopic picture compatible with PMC developed in 10% of patients receiving clindamycin.¹⁷

When lincomycin and clindamycin were studied in experimental animals, a consistent change in cecal bacterial flora was noted.¹⁸ These changes were dose related. This relationship between duration of usage,

dose, and change in flora has not been as direct in the few human studies.

The clinical picture of PMC is fairly typical, beginning with diarrhea, which may abate spontaneously when the drug is stopped, or may progress to produce electrolyte abnormalities and dehydration. It is important that the diagnosis be made early, before these complications develop. This is because morbidity and mortality increase as the disease progresses.¹⁷ An unusual feature of our two cases was the abrupt and explosive onset of symptoms. In one patient hypotension and massive diarrhea were the presenting symptoms. Whether this is unusual or represents a more aggressive onset in suppressed postoperative patients is unknown.

In many instances cessation of the antibiotics alone will result in relief of symptoms and reversal of the proctoscopic findings. Some investigators have observed that yogurt, donor fecal enemas,¹⁹ steroids,²⁰ vancomycin²¹ or cholestyramine may hasten resolution, but these reports are anecdotal and uncontrolled. In a few instances PMC may progress and simulate a toxic megacolon similar to that seen in inflammatory bowel disease, Chagas' disease or amebiasis.

Kleckner et al²² in 1952 and Pettet et al³ in 1954 observed dilatation of the colon with PMC in autopsy studies. However, it was Brown et al²³ in 1968 who first described toxic dilatation of the colon complicating PMC. Since then other cases have been reported, although more have likely been encountered.^{5, 24}

Two important diagnostic tests that establish the diagnosis are proctoscopic examination and plain roentgenograms of the abdomen. Procto-

scopic examination will reveal a thick yellow membrane that coats the rectal mucosa. It consists of fibrin, cell debris, leukocytes, and viable bacteria which may lie between the pseudomembrane and the mucosa.

Plain roentgenograms of the abdomen will reveal dilatation of the colon in cases with megacolon. The diameter of the colon will vary; in our two cases the colons measured 12 and 14 cm at their widest diameter. The picture is easily confused with a toxic megacolon of ulcerative or granulomatous colitis, amebiasis or Chagas' disease. Although dilatation of the colon per se may be encountered after operation, it is not associated with fulminating diarrhea. The need for barium studies in these acutely ill patients is in question and may be contraindicated.

After diagnosis is made antibiotic therapy should be stopped. In some patients, however, this may not halt the diarrhea and clinical course. For these patients, the number of published cases is too few to make any definitive statement regarding treatment.²⁵

The principles of treatment common to all critically ill patients should be applied to "PMC megacolon" patients as well. A normal intravascular and extracellular volume should be established using colloid, salt and plasma solutions and, if necessary, blood. A nasogastric tube should be passed to decompress the stomach and prevent aerophagia. Since bacteria may proliferate beneath the membrane, a Gram stain and culture of the rectal mucosa, pseudomembrane, and stool are done. If the clinical course progresses and sepsis develops, then antibiotics should be resumed. Our policy has been to in-

stitute gentamycin and Cleocin pending culture reports. Beyond this, treatment is speculative.

Despite these measures, the clinical course of our two postoperative patients progressed and deteriorated, and a decompressive transverse colectomy and ileostomy were done to vent the colon and reduce the systemic toxicity. Although successful in treating the toxic megacolon of ulcerative colitis and Crohn's disease,²⁶ this surgical procedure did not alter the fatal outcome in our two cases. Whether this was because viable bacteria remained beneath the pseudomembrane and potentiated the septic course or whether the disease is more fulminant in postoperative patients is not known.

Success with ileostomy and colectomy, subtotal colectomy with ileostomy and a mucus fistula provides hope. Certainly early diagnosis and awareness of the disease offer more hope than either of these surgical alternatives.

Summary

PMC is an uncommon inflammatory condition that may involve the small and large intestines. Although described nearly 100 years ago, long before antibiotics were introduced, today the disease is associated with the use of antibiotics, particularly lincomycin and clindamycin. In one prospective study, a proctoscopic picture compatible with PMC developed in 10% of patients taking lincomycin. The severity of this disease varies from mild and not clinically symptomatic to fulminating with a fatal outcome. Two cases are summarized. In the postoperative period (following insertion of a total hip prosthesis in one patient and excision of a sessile

polypoid colonic lesion in the second), progressive abdominal distention, diarrhea, and shock developed. One patient was taking ampicillin and the second lincomycin. In both, PMC was diagnosed. A loop ileostomy and transverse colostomy were done in both patients, but they died. The current literature is reviewed.

References

1. Finney JM: Gastro-enterostomy for cicatrizing ulcers of the pylorus. *Johns Hopkins Hosp Bull* **4**: 53-55, 1893.
2. Hultborn KA: Acute postoperative enterocolitis; report of 7 cases and review of the literature. *Acta Chir Scand* **111**: 29-44, 1956.
3. Pettet JD, Baggenstoss AH, Dearing WH, et al: Postoperative pseudomembranous enterocolitis. *Surg Gynecol Obstet* **98**: 546-552, 1954.
4. Tedesco FJ, Stanley RJ, Alpers DH: Diagnostic features of clindamycin-associated pseudomembranous colitis. *N Engl J Med* **290**: 841-843, 1974.
5. Ecker JA, Williams RG, McKittrick JE, et al: Pseudomembranous enterocolitis—an unwelcome gastrointestinal complication of antibiotic therapy. *Am J Gastroenterol* **54**: 214-228, 1970.
6. Baird WL Jr, Musser AW, Miller RL: Staphylococcal pseudomembranous enterocolitis. *NC Med J* **24**: 508-510, 1963.
7. Benner EJ, Tellman WH: Pseudomembranous colitis as a sequel to oral lincomycin therapy. *Am J Gastroenterol* **54**: 55-58, 1970.
8. Cohen LE, McNeill CJ, Wells RF: Clindamycin-associated colitis. *JAMA* **223**: 1379-1380, 1973.
9. Pittman FE, Pittman JC, Humphrey CD: Colitis following oral lincomycin therapy. *Arch Intern Med* **134**: 368-372, 1974.
10. Pittman FE, Pittman JC, Humphrey CD: Lincomycin and pseudomembranous colitis. *Lancet* **1**: 451-452, 1974.
11. Scott AJ, Nicholson GI, Kerr AR: Lincomycin as a cause of pseudomembranous colitis. *Lancet* **2**: 1232-1234, 1973.
12. Stroehlein JR, Sedlack RE, Hoffman HN, et al: Clindamycin-associated colitis. *Mayo Clin Proc* **49**: 240-243, 1974.
13. Viteri AL, Howard PH, Dyck WP: The spectrum of lincomycin-clindamycin colitis. *Gastroenterology* **66**: 1137-1144, 1974.
14. Pettet JD, Baggenstoss AH, Judd ED Jr, et al: Generalized postoperative pseudomembranous enterocolitis. *Proc Staff Meet Mayo Clin* **29**: 342-349, 1954.
15. Turnbull RB Jr: Clinical recognition of postoperative micrococcic (staphylococcic) enteritis. *JAMA* **164**: 756-761, 1951.
16. Dixon CF, Weismann RE: Acute pseudomembranous enteritis or enterocolitis; complication following intestinal surgery. *Surg Clin North Am* **28**: 999-1023, 1948.
17. Tedesco FJ, Barton RW, Alpers DH: Clindamycin associated colitis; a prospective study. *Ann Intern Med* **81**: 424-433, 1974.
18. Small JD: Fatal enterocolitis in hamsters given lincomycin hydrochloride. *Lab Anim Care* **13**: 411-420, 1968.
19. Collins DC: Pseudomembranous enterocolitis; further observations on the value of donor fecal enemas as an adjunct in the treatment of pseudomembranous enterocolitis. *Am J Proctol* **11**: 389-391, 1960.
20. Prohaska JV, Long ET, Nelsen TS: Pseudomembranous enterocolitis; its etiology and the mechanism of the disease process. *Arch Surg* **72**: 977-983, 1956.
21. Khan MY, Hall WH: Staphylococcal enterocolitis—treatment with oral vancomycin. *Ann Intern Med* **65**: 1-8, 1966.
22. Kleckner MS Jr, Barga JA, Baggenstoss A: Pseudomembranous enterocolitis: clinicopathologic study of 14 cases in which disease was not preceded by operation. *Gastroenterology* **21**: 212-222, 1952.
23. Brown CH, Ferrante WA, Davis WD Jr: Toxic dilatation of the colon complicating pseudomembranous enterocolitis. *Am J Dig Dis* **13**: 813-821, 1968.
24. Wells RF, Cohen LE, McNeill CJ: Clindamycin and pseudomembranous colitis. *Lancet* **1**: 66, 1974.
25. Stanley RJ, Melson GL, Tedesco FJ: The spectrum of radiographic findings in antibiotic-related pseudomembranous colitis. *Radiology* **111**: 519-524, 1974.
26. Turnbull RB Jr, Hawk WA, Weakley FL: Surgical treatment of toxic megacolon; ileostomy and colostomy to prepare patients for colectomy. *Am J Surg* **122**: 325-331, 1971.