

# Klippel-Trénaunay syndrome associated with chronic disseminated intravascular coagulation and massive osteolysis

Judith A. D'Amico, M.D.

*Department of Pediatrics and Adolescent Medicine*

George C. Hoffman, M.B.,  
B.Chir., F.R.C.Path.

*Department of Laboratory Hematology*

Paul G. Dymont, M.D.

*Department of Pediatrics and Adolescent Medicine*

The Klippel-Trénaunay syndrome is characterized by a hemangiomatous lesion of a limb with varices and limb hyperplasia. Recently a boy was evaluated with this syndrome in association with two other rare conditions, chronic disseminated intravascular coagulation, and massive osteolysis. These disorders are discussed and their possible interrelationships explored.

## Case report

A 15-year-old boy was first examined at the Cleveland Clinic in March 1972. He was the second of two children; his mother had had a normal pregnancy, labor, and delivery. As a neonate, a large hemangioma involving the left buttock and part of the left thigh was noted. Circumcision at that time was uneventful. No medical problems were described until the patient was 13 months old when he reportedly had a pathologic fracture of the left tibia which healed poorly despite extensive therapy. Consultants concluded that the hemangioma over the left limb involved the tibia causing delayed healing of the fracture. Following that event, little growth of the left leg was attained, although the limbs were described as being equal in length prior to that time.

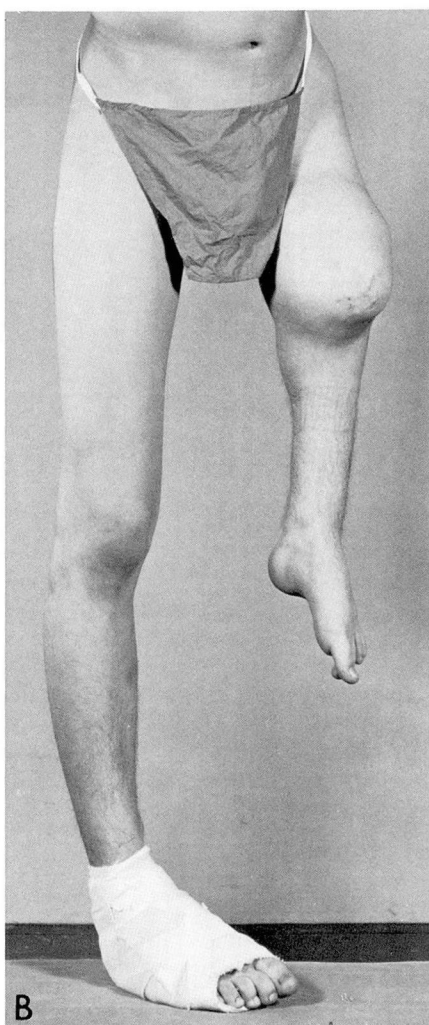
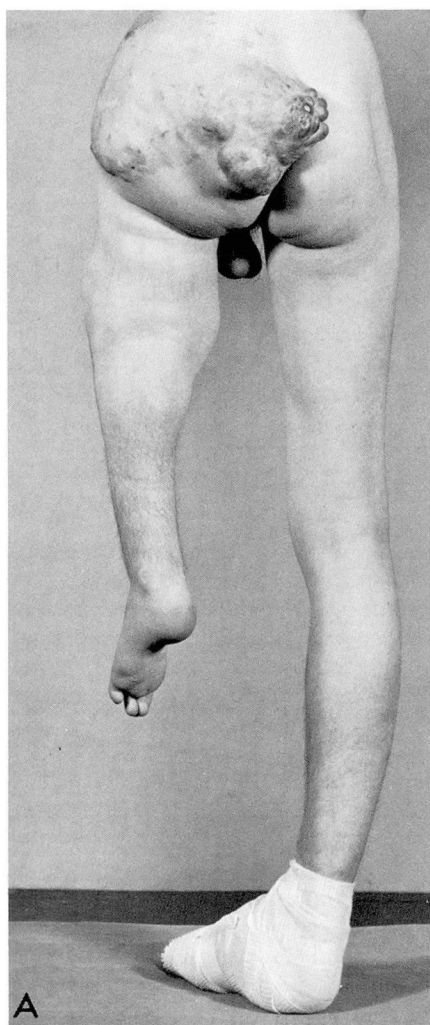
The patient did well until March 1972, when he was first examined for continued oozing from the site of plantar wart surgery. No history of epistaxes, bleeding gums, or petechiae was elicited, although

he did complain of always having bruised easily. Physical examination revealed a healthy looking boy without evidence of bruising or petechiae. A large cavernous hemangioma involving the left buttock and extending onto the thigh of a shortened left limb was the only physical finding of note (*Fig. 1A and B*).

Laboratory studies (*Table*) revealed a low fibrinogen level and mild thrombocytopenia, slightly prolonged thrombin time, abnormally accelerated euglobulin lysis time, and the presence of fibrin split

products as measured by the Fi test,<sup>1</sup> protamine sulfate paracoagulation test,<sup>2</sup> and Thrombo-Wellcotest test.<sup>3</sup> Peripheral blood smears demonstrated morphologic changes compatible with a microangiopathic hemolytic anemia. The condition was diagnosed as disseminated intravascular coagulation, but no specific therapy was advised because of the patient's relatively asymptomatic state. Wound healing progressed normally without further bleeding.

In October 1972 the patient was exam-



**Fig. 1.** **A**, Posterior view of patient at age 15 demonstrating diffuse hemangioma involving the left buttock and thigh with limb shortening. **B**, Anterior view.

Table. Results of laboratory studies

| Test                                  | Date                    |                         |                         |
|---------------------------------------|-------------------------|-------------------------|-------------------------|
|                                       | March 1972              | October 1972            | May 1975                |
| Platelet count                        | 136,000/mm <sup>3</sup> | 100,000/mm <sup>3</sup> | 110,000/mm <sup>3</sup> |
| Fibrinogen                            | 71 mg/dl                | 50 mg/dl                | 64 mg/dl                |
| Prothrombin time                      | 14 sec<br>(12 sec)*     | 13 sec<br>(12 sec)*     | 17 sec<br>(12 sec)*     |
| Activated partial thromboplastin time | 37 sec                  | ...                     | 34 sec                  |
| Factor V                              | 75%                     | ...                     | ...                     |
| Factor VII                            | 80%                     | ...                     | ...                     |
| Thrombin time                         | 23 sec<br>(15 sec)*     | ...                     | 20 sec<br>(12 sec)*     |
| Euglobulin lysis                      | 2 hr                    | 50 min                  | 30 min                  |
| Fibrin split products                 |                         |                         |                         |
| Fi test                               | +                       | ...                     | ...                     |
| Protamine sulfate                     | +                       | +                       | +                       |
| Thrombo-Wellcotest                    | ...                     | ...                     | 40 µg/ml                |
| Bleeding time, Ivy                    | 15 min                  | ...                     | ...                     |

\* Controls.

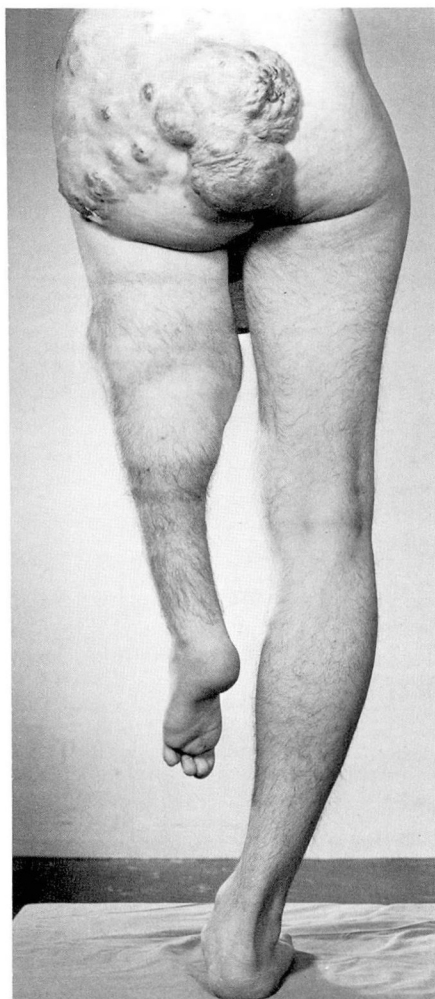ined for the sudden onset of pain in the left thigh following a minor fall. Roentgenograms showed a pathologic fracture of the left femoral head, total resorption of the midshaft of the left femur, and demineralization of the bones of the left hemipelvis, knee, fibula, and foot.

In May 1975 he returned with a chief complaint of severe left hip pain of 1 week's duration. He had experienced intermittent dull left hip pain once or twice a year for the previous 6 years. Physical examination revealed a well-developed 17-year-old boy in no distress. The general physical and neurologic examinations were normal except for several small petechiae, a considerably shortened left limb covered by a varicose cavernous hemangioma, and a mild lumbosacral scoliosis. No bruits were heard over the hemangioma. The patient walked well with a left limb brace and without apparent pain at that time. Roentgenographic examinations of the left extremity showed massive osteolysis of the femur with disappearance of all but the femoral head. The left hemipelvis, left tibia, and left fibula were also affected by the osteolytic process (*Fig. 2*). Results of laboratory tests showed a coagulation pattern and red blood cell morphology essentially un-

changed from that identified 3 years previously. The patient experienced no further pain while hospitalized nor at follow-up 2 weeks later.

Discussion

The triad of cavernous heman-gioma of a limb associated with var-ices and soft tissue and bone hyper-trophy was first described by Klippel and Trénaunay<sup>4</sup> in 1900. More recent observers<sup>5-9</sup> have demonstrated the presence of a malformed deep ve-nous system within the angioma. The formation of varices and subsequent hypertrophy of the involved extrem-ity are believed to follow the devel-opment of venous stasis within the abnormal vessels. Children with the typical manifestation of this disorder frequently do not develop varices or limb hypertrophy until several years after the hemangioma is first discov-ered.<sup>9-12</sup> In fact, not only may this disorder be present without limb hy-pertrophy, but it also may be associ-ated with hypoplasia of the involved extremity.<sup>7, 9</sup> Therefore, the limb hy-poplasia in this case is consistent with



**Fig. 2.** Posterior view of patient at age 17 showing increase in size of the hemangioma.

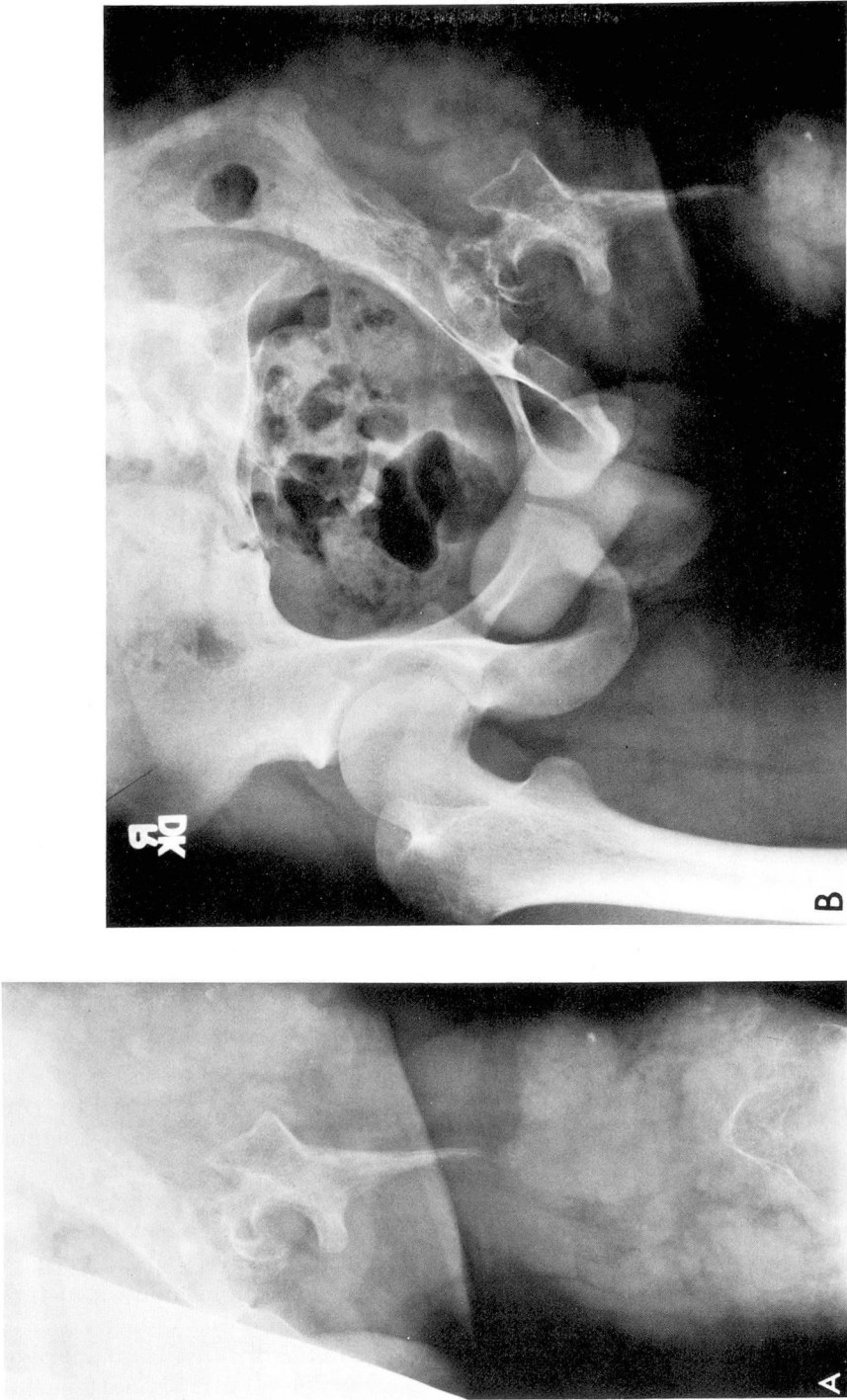
previous reports of the Klippel-Trénaunay syndrome. The possibility exists, however, that this patient's limb hypoplasia may have been related to osteolytic changes of the bones rather than secondary to the vascular malformation.

The association of thrombocytopenia with large hemangiomata was first reported in 1940 by Kasabach and Merritt,<sup>13</sup> but it was not until more recent times that aberrations in

the coagulation mechanism itself were described.<sup>14-17</sup> The main characteristics of this coagulopathy are moderate reduction in platelets, reduction in fibrinogen and other plasma coagulation factors, evidence of fibrinolysis, and the presence of fibrin split products. In studying this phenomenon, Gilon et al<sup>16</sup> demonstrated a relative decrease in the peripheral blood platelet count as opposed to that within the hemangiomatous mass in patients with this disorder, a finding that was later substantiated by Petit et al<sup>18</sup> using chromium-labeled platelets. Gilon et al<sup>16</sup> theorized that the tortuosity of the vessels within the angioma resulted in the trapping and subsequent destruction of platelets which, in turn, led to the activation of the coagulation mechanism and a localized intravascular coagulopathy. This theory is supported by the discovery that although the prothrombin and partial thromboplastin times are usually normal or only slightly prolonged in the peripheral blood of these patients, samples from within the hemangioma itself show greatly prolonged values.<sup>19</sup> Heparinization, high doses of corticosteroids, selective surgical removal of the hemangiomatous mass, and local radiation therapy have been used in an attempt to control this disorder; however, only the latter two methods have been shown to be of any long-term value.<sup>15, 17</sup>

Massive osteolysis is a disease of bone characterized by progressive demineralization and replacement of bone by fibrous connective tissue.<sup>20</sup> Minor trauma frequently heralds its onset. Jackson<sup>21</sup> first described this disease in 1838 when he reported the case of a young man in whom osteol-





**Fig. 3.** A, Roentgenogram of left femur at age 17 showing the tapering characteristic in massive osteolysis. B, Roentgenogram of pelvis demonstrating osteolytic involvement of the left hemipelvis.

ysis of the humerus developed following a simple fracture. The osteolytic process progressed over a period of years until the humerus was totally replaced by a thin fibrous band.

Massive osteolysis may be isolated to the originally involved structure or may go on to involve contiguous bones. In more than 130 reported cases, males appear to be equally as affected as females, and the average age of onset is in late adolescence with a range from 18 months to 58 years. The rapidity and extent of bony resorption is unpredictable, showing any pattern from persistent, relentless destruction to mild demineralization with spontaneous remission. This process usually ends in the development of a flail limb; however, if the chest wall is involved, massive chylothorax and death frequently ensue. The bones most commonly affected are the ribs and scapulae followed by the legs, arms, pelvis, head, and neck.<sup>22</sup> Biopsy specimens of the bone and its surrounding tissues show numerous thin-walled, widely dilated vessels.<sup>23</sup>

This histologic finding and the fact that systemic hemangiomatosis has been reported in association with massive osteolysis<sup>12, 24-26</sup> led to the theory that an angiomatous malformation was the cause of this curious bone lesion.<sup>23</sup> The question arises, however, whether the hemangiomatosis observed clinically and apparently histologically is directly related to the development of massive osteolysis. Hemangiomata with their origin in bone are well-known entities, but their roentgenographic and histologic features are distinct and quite unlike those described in massive osteolysis.<sup>27</sup> However, some hemangiomata of soft tissue possess vascular

patterns that promote localized hyperoxygenation, a factor known to increase bone resorption.<sup>28</sup> To investigate this possibility, angiography has been performed on extremities involved in massive osteolysis; however, a change in circulation time compatible with a state of hyperoxygenation was not demonstrated.<sup>25, 29</sup>

Some investigators believe that the dilated vessels present in biopsy specimens of massive osteolysis may not be related to hemangiomatosis, but may actually represent a compensatory increase in the size of the bone marrow's rich vascular plexus following resorption of its bony matrix.<sup>29, 30</sup> Although more data would be necessary before any conclusions could be reached, the evidence at present does not appear to support the theory that the bony resorption of massive osteolysis is secondary to an intrinsic vascular malformation.

Another possible cause of massive osteolysis is a reversal of the normal osteoblastic to osteoclastic ratio.<sup>28</sup> Some researchers have reported increased numbers of osteoclasts in specimens of massive osteolysis,<sup>29, 31, 32</sup> but this has not been a consistent finding.<sup>33</sup> Therefore, despite several theories, the cause of this condition is still not determined.

The roentgenographic stages of osteolysis have been described by Torg and Steel.<sup>33</sup> They include (1) nondescript patchy osteoporosis, (2) concentric shrinkage (tapering of the involved ends of tubular bones), (3) complete resorption, and (4) progression to contiguous bony structures (*Fig. 3A and B*).

The initial differential diagnosis of massive osteolysis should include such disorders as Sudek's atrophy, atrophy of disuse, and bony changes

secondary to infectious and metabolic derangements. However, after stage 1, the roentgenographic appearance of this disease is so characteristic as to exclude most other diagnostic entities. The only disorder that could be confused with massive osteolysis in later stages is that of acroosteolysis, an autosomal dominant disease with osteolysis of the carpal and tarsal bones. The main differentiating features are that acroosteolysis is hereditary, affects only the distal bones of the hands and feet rather than those of the proximal extremities, and characteristically involves noncontiguous bones.<sup>34</sup>

Attempts at definitive therapy of massive osteolysis have included radiation therapy, high-dose corticosteroids, bone transplants, vitamin D, parathyroid hormone, and calcium.<sup>22</sup> Successfully treated cases have been reported, but there is little to suggest that any one therapy is curative.

Although one cannot draw any definite conclusions on the role of this patient's hemangioma in the development of chronic disseminated intravascular coagulation and massive osteolysis, experimental evidence does support a direct relationship between the vascular malformation of the Klippel-Trénaunay syndrome and the appearance of a consumption coagulopathy. The same cause and effect relationship between hemangiomatous lesions and massive osteolysis has not been conclusively proved to date; yet the occurrence of these three rare disease states in the same patient leads to speculation concerning their possible interrelationships.

## References

1. Castelan DJ, Hirsh J, Martin M: Latex-bound antifibrinogen test for plasma fibrinogen assay. *J Clin Pathol* **21**: 638-642, 1968.
2. Kidder WR, Logan LJ, Rapaport SI, et al: The plasma protamine paracoagulation test; clinical and laboratory evaluation. *Am J Clin Pathol* **58**: 675-686, 1972.
3. Garvey MB, Black JM: The detection of fibrinogen-fibrin degradation products by means of a new antibody-coated latex particle. *J Clin Pathol* **25**: 680-682, 1972.
4. Klippel M, Trénaunay P: Naevus variqueux osteohypertrophique. *Arch Gen Med* **77**: 641-670, 1900.
5. Weber FP: Angioma-formation in connection with hypertrophy of limbs and hemihypertrophy. *Br J Dermatol* **19**: 231-235, 1907.
6. Bourde C: Classification des syndromes de Klippel-Trénaunay et de Parkes-Weber d'après les données angiographiques. *Ann Radiol* **17**: 153-159, 1974.
7. Bohorquez-Salcedo A: Variaciones clínicas del síndrome de Klippel-Trénaunay. *Angiologia* **23**: 255-261, 1971.
8. Muñoz-Cardona P, Sanz-Fernandez J, Gutierrez-Diez JR, et al: Algunas consideraciones del síntoma óseo en la enfermedad de Klippel-Trénaunay. *Angiologia* **23**: 269-273, 1971.
9. Bologa EI: Klippel-Trénaunay syndrome of the right arm with atrophy of bone and soft tissue. *Borgygy Vener Szemk* **40**: 168-171, 1964.
10. Servelle M: Les malformations congénitales des veines. *Rev Chir* **68**: 88, 1949.
11. Brooksaler F: The angioosteohypertrophy syndrome; Klippel-Trénaunay-Weber syndrome. *Am J Dis Child* **112**: 161-164, 1966.
12. Frost JF, Caplan RM: Cutaneous hemangiomas and disappearing bones; with a review of cutaneo-visceral hemangiomatosis. *Arch Dermatol* **92**: 501-508, 1965.
13. Kasabach HH, Merritt KK: Capillary hemangioma with extensive purpura; report of a case. *Am J Dis Child* **59**: 1063-1070, 1940.
14. Patzer-Trzaskowska T, Skrabalak I: Klippel-Trénaunay-Parkes Weber syndrome with simultaneous consumption coagulopathy in a fourteen year old girl. *Pediatr Pol* **44**: 601-606, 1969.
15. Fischer M: Consumption coagulopathy in patients with Klippel-Trénaunay syndrome. *Wein Klin Wochenschr* **85**: 207-212, 1973.
16. Gilon E, Ramot B, Sheba C: Multiple

- hemangiomas associated with thrombocytopenia; remarks on the pathogenesis of the thrombocytopenia in this syndrome. *Blood* **14**: 74-79, 1959.
17. Sutherland D, Clark H: Hemangioma associated with thrombocytopenia; report of a case and review of the literature. *Am J Med* **33**: 150-157, 1962.
  18. Petit P, Schweisguth O, Contoni A, et al: Les angiomes géants du nourrisson avec thrombopénie. *Arch Fr Pédiatr* **14**: 789-798, 1957.
  19. Lang PG, Dubin HV: Hemangioma-thrombocytopenia syndrome: a disseminated intravascular coagulopathy. *Arch Dermatol* **111**: 105-107, 1975.
  20. Gorham LW, Wright AW, Shultz HH, et al: Disappearing bones; a rare form of massive osteolysis; report of two cases, one with autopsy findings. *Am J Med* **17**: 674-682, 1954.
  21. Jackson JVS: Singular case of absorption of bone (boneless arm). *Boston Med Surg J* **10**: 368, 1838.
  22. Bullough PG: Massive osteolysis. *NY State J Med* **71**(2): 2267-2278, 1971.
  23. Gorham LW, Stout AP: Massive osteolysis (acute spontaneous absorption of bone, phantom bone, disappearing bone), its relation to hemangiomatosis. *J Bone Joint Surg* **37A**: 985-1004, 1955.
  24. Fornasier VL: Haemangiomatosis with massive osteolysis. *J Bone Joint Surg* **52B**: 444-451, 1970.
  25. Halliday DR, Dahlin DC, Pugh DG, et al: Massive osteolysis and angiomatosis. *Radiology* **82**: 637-644, 1964.
  26. Wallis LA, Asch T, Maisel BW: Diffuse skeletal hemangiomatosis; report of two cases and review of literature. *Am J Med* **37**: 545-563, 1964.
  27. Bucy PC, Capp CS: Primary hemangioma of bone with special reference to roentgenologic diagnosis. *Am J Roentgenol* **23**: 1-33, 1930.
  28. Gorham LW: Circulatory changes associated with osteolytic and osteoblastic reactions in bone; the possible mechanism involved in massive osteolysis; an experimental study. *Arch Intern Med* **105**: 199-216, 1960.
  29. Milner SM, Baker SL: Disappearing bones. *J Bone Joint Surg* **40B**: 502-513, 1958.
  30. Gambier R: L'osteolisi segmentaria progressiva. *Chir Org Movimento* **41**: 85-110, 1955.
  31. Kery L, Wouters HW: Massive osteolysis; report of two cases. *J Bone Joint Surg* **52B**: 452-459, 1970.
  32. Tilling G, Skobowytsh B: Disappearing bone disease, morbus Gorham. Report of a case. *Acta Orthop Scand* **39**: 398-406, 1968.
  33. Torg JS, Steel HH: Sequential roentgenographic changes occurring in massive osteolysis. *J Bone Joint Surg* **51A**: 1649-1655, 1969.
  34. Schurtleff DB, Sparkes RS, Clawson DK, et al: Hereditary osteolysis with hypertension and nephropathy. *JAMA* **188**: 363-368, 1964.