

# Acute ophthalmoplegia, ataxia, and areflexia (Fisher syndrome) in childhood

Ronald L. Price, M.D.  
Patrick S. O'Connor, M.D.

*Department of Ophthalmology*

A. David Rothner, M.D.

*Department of Neurology  
Department of Pediatrics and Adolescent  
Medicine*

A case of ophthalmoplegia, ataxia, and areflexia known as Fisher syndrome in a 3<sup>1</sup>/<sub>2</sub>-year-old boy is reported. The clinical features, diagnosis, and outcome are described. The relationship of Fisher syndrome to acute idiopathic polyneuritis (the Guillain-Barré syndrome) is discussed. This case is unique in that the syndrome developed coincident with infectious mononucleosis. The need to consider infectious mononucleosis in any acute neurologic illness in childhood is stressed.

In 1956, Fisher<sup>1</sup> described a syndrome characterized by the acute onset of total bilateral external ophthalmoplegia, severe ataxia, and absence of the deep tendon reflexes. Although the onset of the disorder was alarming, the course was benign. Since that time numerous cases have been reported<sup>2-11</sup> with less than 10 cases occurring in children and none reported in association with infectious mononucleosis.

## Case report

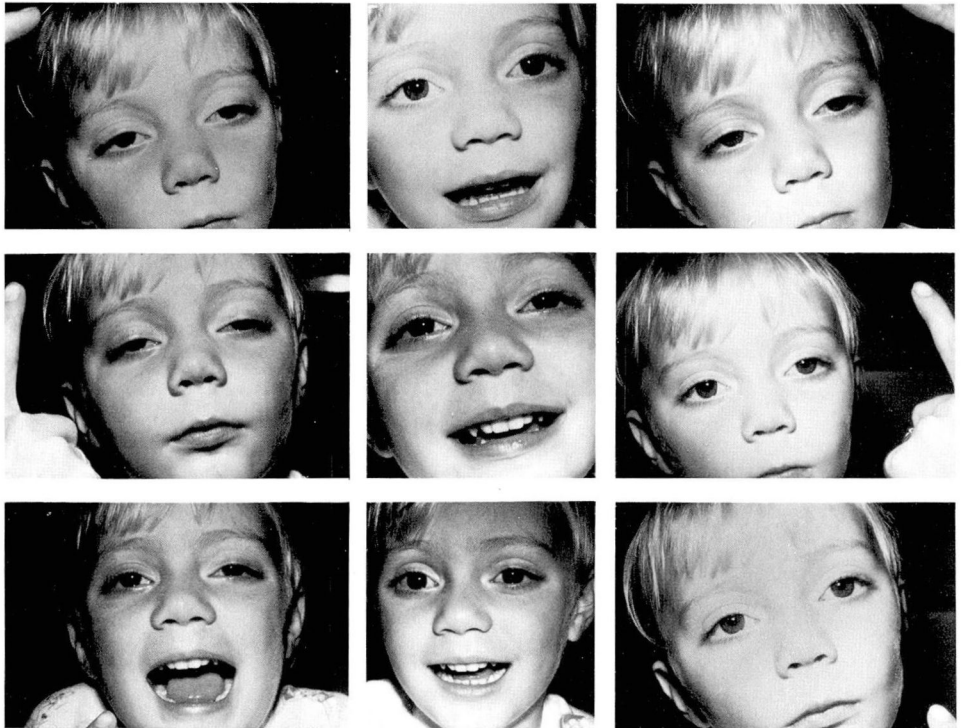A 3<sup>1</sup>/<sub>2</sub>-year-old Caucasian boy had total bilateral external ophthalmoplegia and ataxia. Eight days prior to admission he had had a flu-like syndrome with pharyngitis, diarrhea, vomiting, and a fever of 101 F, which lasted 5 days. On the sixth day his gait became unsteady; a mild, generalized headache de-

veloped and he appeared to stare continuously. His family history and medical history were normal. Ophthalmologic examination revealed an alert, cooperative patient who identified the Allen card pictures at half the normal visual distance for his age. His binocular near visual acuity was 20/40 near Snellen equivalent at 14 inches. There was moderate bilateral ptosis to the lower pupillary margin, but both eyelids could be elevated on command. Complete bilateral external ophthalmoplegia was present (*Fig. 1*) with absence of elevation on forced lid closure and no optokinetic response. His pupils were round, equal, and reacted normally to accommodation and to light, both directly and consensually. Slit lamp and ophthalmoscopic examinations were normal.

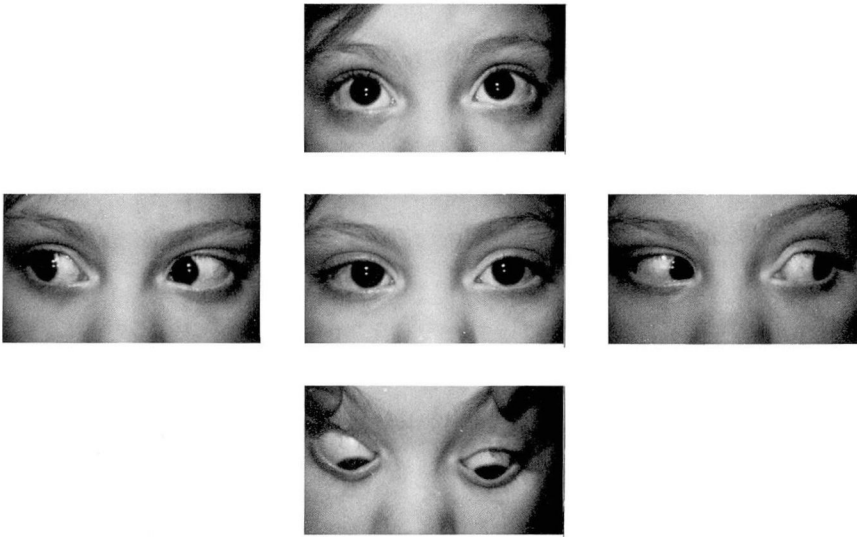
The general physical examination was normal. Specifically, no adenopathy, tonsillar exudate, hepatomegaly, or spleno-

megaly were present. Neurologic examination revealed mild bilateral facial weakness, generalized hypotonia, areflexia, gait ataxia, and finger to nose dysmetria. Muscle strength, plantar responses, and sensory testing were normal.

Laboratory examination disclosed the following values: white blood cell count 9600/mm<sup>3</sup> with 69% lymphocytes, most of which were reactive and atypical, hematocrit 41%, and hemoglobin level 13.4 g/dl. The mono spot test was positive. The heterophil test was positive at 1:128 and the differential absorption tests confirmed the diagnosis of infectious mononucleosis. The SMA-12, serum electrolytes, blood ammonia, and urinalysis were normal. Cerebrospinal fluid examination revealed a slightly elevated protein of 48 mg/dl with a normal protein electrophoresis. Bacterial and viral cultures of the throat were negative. Epstein-Barr virus titers were not performed. An elec-



**Fig. 1.** During the initial examination, patient is attempting to look in the nine gaze positions demonstrating complete ophthalmoplegia, ptosis and mild facial weakness.



**Fig. 2.** Five months after the onset of illness, patient demonstrates full eye motion and mild ptosis.

troencephalogram was minimally and nonspecifically abnormal. Electromyogram and nerve conduction velocities were normal at 2 days and 2 months. Skull and chest roentgenograms were normal, as was computed tomography of the skull.

The ophthalmoplegia cleared in 2 months with gradual clearing of the ataxia and almost complete return of the deep tendon reflexes over 4 months. Repeat blood count at this time showed no atypical lymphocytes. When last seen, 5 months after his illness, mild ptosis and hyporeflexia persisted (*Fig. 2*), but his general physical and mental health were excellent.

### Discussion

Fisher syndrome is characterized by the acute onset of total external ophthalmoplegia, severe ataxia, and absent deep tendon reflexes following an upper respiratory or gastrointestinal infection. The patients range in age from 3½ to 63 years with a male to female ratio of 3:1. Sluggish pupils, mild ptosis, and a partial or total bilateral facial paresis are seen variably in over 50% of cases. Muscle

strength is otherwise usually normal. An absent Bell phenomenon occurs occasionally. Sensation is normal and mentation usually is intact. The cerebrospinal fluid protein is elevated in over 50% of cases and all cases to date have resolved spontaneously, though one recurrence has been reported in a 6-year-old child after an interval of 5 years.<sup>4</sup>

Fisher felt that these patients represented a variant of the Guillain-Barré syndrome which is characterized by the acute onset of ascending neuritis following, in 5 to 12 days, an upper respiratory or gastrointestinal infection in two thirds of cases.<sup>2</sup> Paralysis is noted first, beginning as a flaccid weakness of the lower limbs without pain. The paralysis ascends to involve the upper limbs and may lead to death, if there is respiratory muscle involvement. Sensory changes are generally absent, but, if present, are very mild, consisting of cutaneous hypesthesia and impaired vibratory sense. Facial diplegia occurs in 85% of patients.<sup>12</sup> Typically, there is an elevation of cerebrospinal fluid

protein with a normal cell count. Ocular involvement occurs rarely and may include partial or complete ophthalmoplegia, isolated ocular motor nerve paresis, pupil paresis, total internal ophthalmoplegia, papilledema, optic neuritis, or optic atrophy.<sup>13</sup> The disease is usually self-limiting, but when ophthalmoplegia is present, the mortality rate is 15% to 60% due to associated respiratory failure.<sup>14</sup>

In 1937, Guillain proposed a classification of the Guillain-Barré syndrome based on topographic considerations:<sup>15</sup> (1) involvement of the extremities only, (2) involvement of the extremities and cranial nerves, (3) involvement of the cranial nerve only, and (4) polyradiculopathy with mentation changes. It is this third class, termed "la forme mésocéphalique pure," which most closely applies to our patient.

Although patients with Fisher syndrome are similar to class 3 Guillain-Barré syndrome, these two syndromes have many dissimilarities. Ataxia, though it occurs in Guillain-Barré syndrome, is usually associated with muscle weakness or impaired deep sensory modalities. Severe ataxia occurs in Fisher syndrome with normal or minimally impaired motor strength and sensation.<sup>15</sup> Ophthalmoplegia, rare and possibly ominous in Guillain-Barré syndrome, occurs universally in Fisher syndrome, which to date is benign.

Both syndromes do, however, share certain characteristics such as similar onset and laboratory findings. Additionally, cranial neuropathies can precede the onset of weakness in Guillain-Barré syndrome, so it is not unreasonable to postulate that they can occur alone.<sup>15</sup> It appears best to

consider these syndromes as a continuum of disease and not to attempt further subclassification. This has been suggested and the term encephalo-myelo-radiculo-neuropathy has been proposed to emphasize the similarities of these two syndromes, at least in children.<sup>16</sup>

Several neurologic entities could be mistaken for Fisher syndrome. In children and adults, acute myasthenia gravis precipitated by an acute infectious illness may produce a similar constellation of eye signs, but areflexia and ataxia without marked weakness will not occur. Other neurologic disorders primarily of adulthood must also be considered. A cerebrovascular accident involving the vertebrobasilar circulation could produce a similar ophthalmoplegia, but would invariably be associated with profound depression of consciousness, long tract signs, and/or pupillary changes. Wernecke's encephalopathy with its abrupt onset of mental changes, ataxia, and extraocular muscle paralysis most closely mimics Fisher syndrome. The frequent finding of peripheral neuropathy, alcoholism, mental changes, and long-standing nutritional deficiencies combined with the infrequent occurrence of total ophthalmoplegia helps to distinguish these two syndromes. Other entities, such as diphtheria, botulism, exogenous toxins, Devic's disease, pituitary apoplexy, and bulbar poliomyelitis should also be considered, but are usually easily differentiated.

There are other disorders in which multiple cranial nerve dysfunction can occur and also be mistaken for Fisher syndrome. Such disorders are rarely of acute onset, seldom self-limiting, and are usually distinguishable

by their accompanying systemic disorders. These include neoplasm, congenital defects, orbital "myositis," ocular myopathy, sarcoidosis, endocrinopathy, connective tissue disorder, nutritional deficiency, and diabetes.

All speculation on the site of the lesion in Fisher syndrome must be on a theoretical basis, for no pathologic material is available. The syndrome is a bizarre mixture of apparently central and peripheral lesions with signs and symptoms referable to pathways in the supranuclear central nervous system, cerebellum, brainstem, lower motor neurons, and spinocerebellar tract areas, and it appears best explained by a combination of both peripheral and central nervous system involvement.<sup>2</sup>

The etiology and underlying mechanism of both Guillain-Barré and Fisher syndromes are unknown. Infections, particularly viral,<sup>17</sup> vaccinations, serum sickness, collagen diseases, dysproteinemia, leukemia, and visceral carcinomatosis have been implicated in the Guillain-Barré syndrome.<sup>18</sup> The Guillain-Barré syndrome has also recently been reported in association with heterophil negative cytomegalic positive mononucleosis.<sup>19</sup> No such relationship had previously been found in the Fisher syndrome. However, it had been suggested that heterophil testing be carried out in these patients.<sup>2</sup> Additionally, the mononucleosis syndrome itself has a high incidence of nervous system involvement; in one series<sup>20</sup> the incidence of central nervous system involvement with infectious mononucleosis was 5.5%. More importantly, in these neurologically affected patients, the neurologic signs and symptoms were the major and/

or heralding feature of the illness. In six of these patients the only detectable clinical manifestations were neurologic. Nervous system involvement varied from a classic Guillain-Barré syndrome in some to headaches, diplopia, papilledema, and sixth nerve palsy in others. None had Fisher syndrome. In a later report<sup>21</sup> it was pointed out that acute cerebellar ataxia in childhood may also be associated with infectious mononucleosis. It was further stressed<sup>22</sup> that mononucleosis itself is a syndrome that may be caused by a variety of agents, such as Epstein-Barr virus, cytomegalic virus, toxoplasmosis, and listeriosis, the last three giving a heterophil negative test.

Our patient with his preceding clinical symptoms, lymphocytosis with atypical lymphocytes, positive differential heterophil titer, and hepatic enlargement, meets the criteria of infectious mononucleosis. His neurologic findings of ataxia, areflexia, and ophthalmoplegia with facial paresis are diagnostic of Fisher syndrome. These findings combined with the well-established<sup>7</sup> relationship between the Guillain-Barré syndrome and infectious mononucleosis suggest a similar relationship here.

### Summary

A previously healthy 3½-year-old white boy had total external ophthalmoplegia, ataxia, and areflexia occurring 1 week after an upper respiratory infection. The relationship between Fisher syndrome and Guillain-Barré syndrome is explored and the differential diagnosis discussed. The relationship of mononucleosis to these entities is reviewed. The invariably benign nature of Fisher syndrome as opposed to the possibly

lethal nature of the Guillain-Barré syndrome is stressed. The possible sites for involvement are described and the need to consider infectious mononucleosis in any acute neurologic illness of childhood is stressed.

## References

1. Fisher M: An unusual variant of acute idiopathic polyneuritis (syndrome of ophthalmoplegia, ataxia and areflexia. *N Engl J Med* **255**: 57-65, 1956.
2. Smith JL, Walsh FB: Syndrome of external ophthalmoplegia, ataxia and areflexia (Fisher). *Arch Ophthalmol* **58**: 109-114, 1957.
3. Neubert FR: Complete ophthalmoplegia in acute toxic polyneuritis. *Br J Ophthalmol* **42**: 632-633, 1958.
4. Van Allen MW, MacQueen JC: Ophthalmoplegia, ataxia and the syndrome of Landry-Guillain-Barré. *Trans Am Neurol Assoc* **89**: 98-103, 1964.
5. Patel A, Pearce L, Hairston R: Miller Fisher syndrome (variant of Landry-Guillain-Barré-Strohl syndrome—ophthalmoplegia, ataxia, areflexia). *South Med J* **59**: 171-175, 1966.
6. Bell W, VanAllen M, Blackman J: Fisher syndrome in childhood. *Develop Med Child Neurol* **12**: 758-766, 1970.
7. Qaquadah BY, Taylor WF: Miller Fisher syndrome in a 22-month-old child. *J Pediatr* **77**: 868-870, 1970.
8. Elizan TS, Spire JP, Andiman FA, et al: Syndrome of acute idiopathic ophthalmoplegia with ataxia and areflexia. *Neurology* **21**: 281-292, 1971.
9. Yalaz K, Selekler K: Syndrome of acute idiopathic ophthalmoplegia with ataxia and areflexia in childhood (Miller Fisher's syndrome). *Turkish J Pediatr* **12**: 127-131, 1971.
10. Rao MN, Urmila S: Fisher's syndrome—a case report. *Indian Pediatr* **11**: 515-517, 1974.
11. Weintraub MI: External ophthalmoplegia, ataxia and areflexia complicating acute infectious polyneuritis. *Am J Ophthalmol* **83**: 355-357, 1977.
12. Merritt H: *A Textbook of Neurology*, ed 5. Philadelphia, Lea & Febiger, 1973.
13. Walsh FB, ed, Hoyt WF: *Clinical Neuro-ophthalmology*, v. 2, ed 3, Baltimore, Williams & Wilkins Co, 1969.
14. Duke-Elder S, ed: *Neuro-ophthalmology. System of Ophthalmology*, v. 12. St. Louis, CV Mosby Co, 1971.
15. Munsat TL, Barnes JE: Relation of multiple cranial nerve dysfunctions to the Guillain-Barré syndrome. *J Neurol Neurosurg Psychiatr* **28**: 115-120, 1965.
16. Gamstorp I: Encephalo-myelo-radiculoneuropathy; involvement of the CNS in children with Guillain-Barré-Strohl syndrome. *Develop Med Child Neurol* **16**: 654-658, 1974.
17. Gibberd FB, Kelly RE: Acute internal and external ophthalmoplegia with polyradiculitis of probable virus aetiology. *Brain* **87**: 657-644, 1964.
18. Kisch AL: Guillain-Barré syndrome following smallpox vaccination. *N Engl J Med* **258**: 83-84, 1958.
19. Jordan MC, Rousseau WE, Stewart JA, et al: Spontaneous cytomegalovirus mononucleosis; clinical and laboratory observations in nine cases. *Ann Intern Med* **79**: 153-160, 1973.
20. Silverstein A, Steinberg G: Nervous system involvement in infectious mononucleosis. *Arch Neurol* **26**: 353-358, 1972.
21. Bergen D, Grossman H: Acute cerebellar ataxia of childhood associated with infectious mononucleosis. *J Pediatr* **87**: 832-833, 1975.
22. Jordan MC: Nomenclature for mononucleosis syndromes. *JAMA* **234**: 45-46, 1975.