

Anterior decompression for progressive brain stem compression in the Klippel-Feil syndrome

Guy M. Sava, M.D.
Donald F. Dohn, M.D.

Department of Neurological Surgery

A. David Rothner, M.D.

*Department of Neurology
Department of Pediatrics and Adolescent
Medicine*

In 1912 Klippel and Feil¹ described a condition characterized by fusion and reduction in the number of cervical vertebrae. Since that time more than 200 cases have been reported. To our knowledge none have been treated by the transmandibular translanguinal approach described by Hall et al.² The importance of this malformation lies in the secondary effects produced on the nervous system. Symptoms include cord and brain stem compression, weakness, spasticity, staggering, dysmetria, nystagmus, sensory loss, and lower cranial nerve involvement.

We report a case of progressive brain stem compression treated by posterior decompressive cervical laminectomy followed by an anterior decompression.

Case report

An 18-year-old man was studied for progressive spasticity. He was the second of five siblings. The diagnosis of Klippel-Feil syndrome was suggested when the patient was 8 years old. At age 12 years he was more awkward than he had been the previous year. Clumsiness was noted particularly after he sat any length of time. He repeatedly dropped things and believed his grip was deteriorating. On one occasion while playing football he fell; his arms immediately became numb and he was unable to move for 45 minutes. This subsequently re-

solved completely. Since that time progressive quadriplegia and bulbar symptoms have developed.

Family history. Both nonconsanguineous parents are alive and well. The oldest child, aged 19 years, had respiratory distress at birth requiring tracheostomy. Presently she has whistling respirations, mild spasticity, and no brevicollis. Cervical roentgenograms were abnormal. Her nonidentical twin is normal. A 14-year-old sister has no symptoms. On examination she had spasticity and brevicollis. Cervical roentgenograms were normal. A 10-year-old sister had severe headache and facial numbness following minimal head trauma. She had brisk reflexes and brevicollis; malformations of the cranio-occipital junction and probable stem compression were similar to those of her 18-year-old brother. The parents have no brevicollis and roentgenograms are normal.

Physical examination. The patient's neck was short with webbing and his head tilted to the right. His gait was spastic. Cranial nerve examination demonstrated the uvula deviating to the right and there was a hyperactive gag reflex. Motor examination showed bilateral increased tone, left greater than right with cog wheeling. Muscle strength was normal. Reflexes were hyperactive in all extremities with bilateral positive Babinski signs. Cerebellar testing confirmed spasticity. There was decreased sensation in pin prick and temperature over the shoulders.

Roentgenograms. The initial cervical roentgenograms showed failure of segmentation in the upper cervical spine with basilar impression and possible assimilation of the atlas. Computed tomography demonstrated platybasia and basilar impression. Myelography showed severe narrowing of the upper cervical canal with angulation at the cervical medullary junction.

Hospital course. Because of anticipated difficulty with intubation and extreme reluctance to hyperextend an already compromised cervical canal, a tracheostomy was performed prior to the posterior craniocervical decompression. Postoperatively his spasticity resolved. Initially he thought his

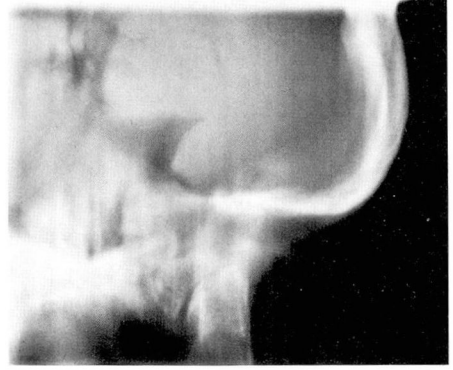


Figure. Air myelography shows narrowing of column at craniocervical junction.

walking was improved. However, when examined 3 months after operation his gait had deteriorated and the findings at examination were the same as those noted preoperatively except for the brief interim of diminished spasticity. Approximately 11 months after posterior cervical decompression he had increased difficulty swallowing and his speech was unintelligible. Air myelography demonstrated narrowing of the column at the craniocervical junction (*Figure*). Even though he had an adequate posterior decompression, his cord was severely compressed by the odontoid process over a deformed C-1 and C-2 which were acutely angulated. A combined surgical team consisting of otorhinolaryngologists and neurosurgeons performed an anterior decompression. With a midline labiomandibular glosotomy approach, the odontoid process was removed and decompression of the cervical medullary junction was achieved. Postoperatively he became stronger and spasticity diminished within 1 week. The tracheostomy was closed without difficulty. When examined again 3 months after operation, he had no difficulty swallowing and the cosmetic and functional results were excellent.

Discussion

Fusion of cervical vertebrae, low occipital hairline, and limitation of movement of the cervical spine constitute the Klippel-Feil syndrome.^{1,3} There are

three types of Klippel-Feil syndrome: (1) portions of several cervical or thoracic vertebrae fused to form a single block; (2) failure of segmentation at two or more cervical levels; (3) a more extensive anomaly including segmentation errors in the lower dorsal or lumbar spine in addition to cervical involvement. Several accompanying anomalies have been described and include cervico-ocular acoustic dysplasia, crossed renal pelves, aortic coarctation, and congenital, high scapular deformity (Sprengel's deformity).³ The genetic pattern varies and autosomal dominant, autosomal recessive, and sporadic cases have been reported.³

In this patient basilar impression was associated with marked brain stem and cord compression. This history of temporary quadriplegia recalls the report by Strax and Baran.⁴ They called attention to the susceptibility of patients with Klippel-Feil syndrome to spinal cord injury. Their report demonstrates how an apparently insignificant fall out of bed led to quadriplegia in a patient with this disorder. It also demonstrates the fragility of the lower brain stem and the upper cervical cord in the Klippel-Feil syndrome, and reiterates the necessity for careful scrutiny and long-term follow-up. It emphasizes the use of a new

surgical technique which allows adequate decompression of symptomatic patients by a method not described previously.

Summary

A case of Klippel-Feil syndrome with spinal cord and brain stem compression treated by both the posterior cervical decompression and anterior craniovertebral decompression is reported. The genetics, different forms of this disorder, presenting symptoms, and complications are reviewed. A new approach to decompression is discussed.

References

1. Klippel M, Feil A: Anomalie de la colonne vertébrale par absence des vertèbres cervicales; cage thoracique remontant jusqu' à la base du crâne. *Bull et mém Soc anat de Par* **87**: 185-188, 1912.
2. Hall JE, Denis F, Murray J: Exposure of the upper cervical spine for spinal decompression by a mandible and tongue-splitting approach; case report. *J Bone Joint Surg* **59**: 121-123, 1977.
3. Gunderson CH, Greenspan RH, Glaser GH, et al: The Klippel-Feil syndrome; genetic and clinical reevaluation of cervical fusion. *Medicine* **46**: 491-512, 1967.
4. Strax TE, Baran E: Traumatic quadriplegia associated with Klippel-Feil syndrome; discussion and case reports. *Arch Phys Med Rehabil* **56**: 363-365, 1975.