

# Demonstration of a bronchopleural fistula by ventilation lung scanning

James R. Yarnal, Ph.D., D.O.  
Muzaffar Ahmad, M.D.

*Department of Pulmonary Disease*

William Peppo, D.O.\*

Lung scanning by xenon 133 ( $^{133}\text{Xe}$ ) ventilation is a study that is easy to perform and may be diagnostic of bronchopleural fistula when other routinely employed procedures such as methylene blue instillation, fiberoptic bronchoscopy, and bronchography are not helpful.

The incidence of bronchopleural fistulae following pulmonary resection in one large series was 2.7%.<sup>1</sup> The mortality in this series was 16.4%, but it can be as high as 23% to 67%.<sup>2,3</sup> In view of the present epidemic of lung cancer,<sup>4</sup> with a concomitant increase in the number of operations, postoperative complications would also be expected to increase. However, the incidence of bronchopleural fistulae may vary from center to center, with an obvious bronchial stump leak being the only entity of assured recognition.<sup>5</sup> A small leak may not be recognized initially, and possibly may lead to increased morbidity or even mortality at a later date. We report a case of a postpneumonectomy bronchopleural fistula in which xenon lung scanning confirmed the diagnosis.

---

\**Department of Medicine, Pulmonary Section, Detroit Osteopathic Hospital, Detroit, Michigan.*

### Case report

A 58-year-old diabetic black male with suspected tuberculosis was admitted because of a positive intermediate PPD skin test and a right upper lobe infiltrate. Sputum smears failed to show mycobacteria and fiberoptic bronchoscopy revealed epidermoid carcinoma. An extensive work-up including mediastinoscopy was negative, and a right pneumonectomy was performed. The bronchial stump was closed in two layers, using O Prolene. The pathology report revealed right hilar lymph node involvement with tumor and invasion of the right main stem bronchus. Prophylactic cephalothin was given postoperatively. Isoniazid therapy was begun because of the positive skin test and bacillus Calmette Guérin (BCG) vaccine was administered intrapleurally.

Three days postoperatively a mild productive cough and a temperature of 101.3 F (oral) developed. Physical examination revealed superficial phlebitis (from cephalothin), but no adventitious sounds in the left lung. Although a sputum culture grew *Pseudomonas aeruginosa*, no change of antibiotic was instituted, because the organism was thought to be only colonizing the airways. Cobalt 60 radiotherapy to the mediastinum and right supraclavicular area was begun on the 14th postoperative day. After a short stay at home, the patient was readmitted on the 19th postoperative day when spiking temperatures (101.5 F), white blood cell count of 15,200 mm<sup>3</sup> and shortness of breath associated with paroxysms of continuous coughing developed. Minimal blood-streaked yellowish sputum was expectorated and once again grew *P. aeruginosa*. Four days later the patient experienced severe shortness of breath and hemoptysis during a relentless paroxysm of coughing when he lay on his left side. Fluid from the right side obtained by thoracentesis grew *P. aeruginosa*, and a smear demonstrated Auramine-Rhodamine fluorescent bacilli resembling mycobacteria. (Cultures were eventually positive for *Mycobacterium tuberculosis*.)

The posteroanterior roentgenogram obtained at admission the 19th postoperative

day showed the right pneumonectomy and partial obliteration of the right hemithorax with fluid (Fig. 1). Figure 2A shows selected posterior views of the <sup>133</sup>Xe ventilation scan performed approximately 30 hours after the bout of marked hemoptysis. Figure 2A was obtained 10 seconds and 2 minutes after inhalation of 10 mCi of <sup>133</sup>Xe. The left lung demonstrates essentially normal inhalation and equilibration. However, uptake of the isotope was observed in the right hemithorax where the pneumonectomy had been performed. This finding is diagnostic of an abnormal communication between the residual bronchus and the right chest cavity—a bronchopleural fistula. The xenon is localized superiorly because of the inferiorly placed effusion. Figure 2B demonstrates the washout phase of the scan obtained at 120 to 180 seconds. The left lung is once again normal with no retention of xenon. The presence of a bronchopleural fistula is confirmed on the right with obvious retention of the isotope occurring.

The patient was initially treated with a tube thoracostomy, isoniazid, ethambutol, rifampin, systemic gentamicin and carbenicillin, and intrapleural gentamicin. After one month of this conservative therapy, a pleural-cutaneous fistula was surgically created and the patient was discharged from the hospital 6 days later.

### Discussion

An accurate and early diagnosis of postoperative bronchopleural fistula is imperative to initiate timely and appropriate therapy. Delay in diagnosis and treatment "can lead to chronic complications and increased morbidity."<sup>6</sup> As discussed in a recent editorial,<sup>5</sup> a bronchopleural fistula is more common in a patient with poor health preoperatively and with chronic bronchial infections. Tuberculosis and a right pneumonectomy were also significant risk factors.

Besides being suspected clinically, several techniques are available to help

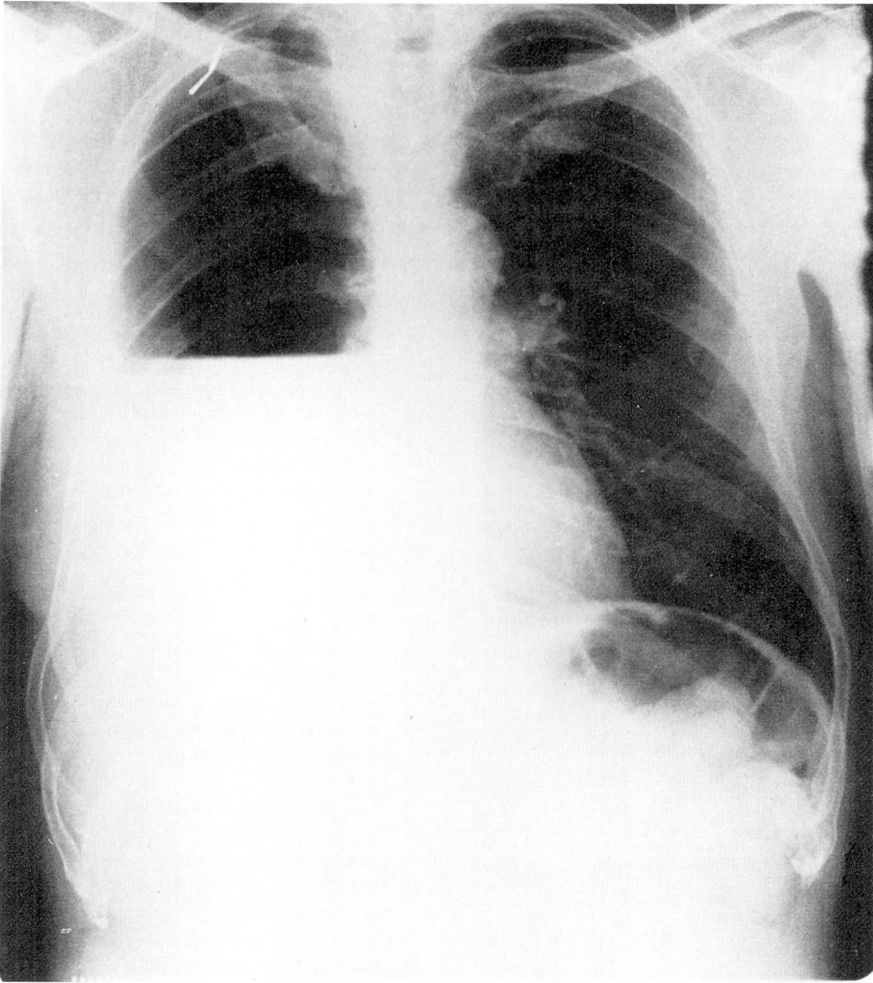


Fig. 1. The admission posteroanterior chest roentgenogram.

in the diagnosis of a bronchopleural fistula. A routine chest roentgenogram may be suggestive of a stump leakage by the presence of a changing air-fluid level or an increasing pneumothorax. Instillation of methylene blue into the pleural space followed by the presence of bluish-tinged sputum is diagnostic, as is the patient's subjective response (smell or taste) to an intrapleural injection of ether.<sup>7</sup> Bronchography may detect a large fistula, but is not useful in detecting small (early) leaks; a sinogram may

also be helpful in selected cases.<sup>8</sup> Bronchoscopy has the same limitations as bronchography, but when positive, allows accurate localization of the abnormal communication. This case report describes a reliable technique for the demonstration of a bronchopleural fistula even when undetectable by these other invasive techniques.<sup>9</sup> Although  $^{133}\text{Xe}$  is the isotope usually used for ventilation lung scanning, any similar radiopharmaceutical can be employed.<sup>10</sup> The simple and valuable tech-

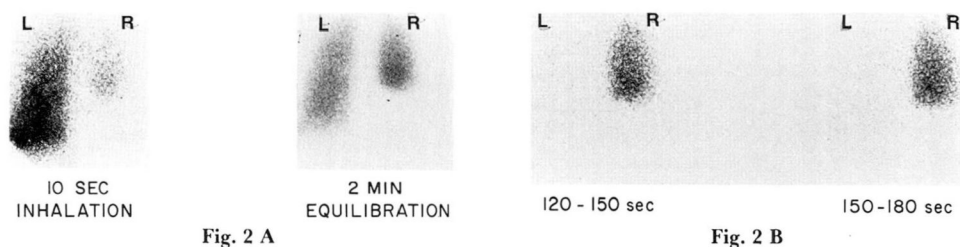


Fig. 2 A and B. Posterior radionuclide images from the  $^{133}\text{Xe}$  ventilation scan.

nique described here can be performed whenever the question of a bronchopleural fistula postoperatively arises. Additionally, in a patient with a bronchopleural fistula treated by chest tube thoracostomy, the technique may be helpful in determining the origin of residual pleural air, i.e., from an unclosed fistula or from the chest tube itself.

Although this and two previous cases<sup>9,10</sup> were postpneumonectomy bronchopleural fistulae, there is no reason to suspect that this technique would be any less valuable in either spontaneous or postlobectomy fistulae.

### Acknowledgment

We thank Dr. Donald Hayosh for allowing us to present the details of this case.

### References

1. Williams NS, Lewis CT: Bronchopleural fistula: review of 86 cases. *Br J Surg* **63**: 520-522, 1976.
2. Malave G, Foster ED, Wilson JA, et al: Bronchopleural fistula--present-day study of an old problem; a review of 52 cases. *Ann Thorac Surg* **11**: 1-10, 1971.
3. Bjork VO: Suture material and technique for bronchial closure and bronchial anastomosis. *J Thorac Surg* **32**: 22-27, 1956.
4. Mittman C, Bruderman I: Lung cancer: To operate or not? *Am Rev Respir Dis* **116**: 477-496, 1977.
5. Bronchopleural fistula. *Br Med J* **2**: 1093-1094, 1976.
6. Schachter EN, Kreisman H, Putman C: Diagnostic problems in suppurative lung disease. *Arch Intern Med* **136**: 167-171, 1976.
7. Franz BJ, Murphy JD: The masked bronchopleural fistula. *J Thorac Surg* **29**: 512-517, 1955.
8. Hsu JT, Bennett GM, Wolff E: Radiologic assessment of bronchopleural fistula with empyema. *Radiology* **103**: 41-45, 1972.
9. Zelefsky MN, Freeman LM, Stern H: A simple approach to the diagnosis of bronchopleural fistula. *Radiology* **124**: 843-844, 1977.
10. Greyson ND, Rosenthal L: Detection of postoperative bronchopleural fistulas by radionuclide fog inhalation. *Canad Med Assoc J* **103**: 1366-1368, 1970.