

Cancer of the thyroid appearing after (but probably not caused by) treatment with radioactive iodine

George Crile, Jr., M.D.

*Resident Emeritus Consultant
Department of General Surgery*

Caldwell B. Esselstyn, Jr.,
M.D.

Department of General Surgery

Sebastian A. Cook, M.D.

Department of Nuclear Medicine

In the 30 years that ^{131}I has been used in the treatment of hyperthyroidism, its use has not been associated with any increase in the incidence of cancer of the thyroid. McDougall¹ reported 15 cases and showed that in six of them the period between treatment and the appearance of the cancer was so short (3 months to 4 years) that the cancer probably was not caused by radiation, but was present at the time of treatment. In 7 of 15 patients, the dose of ^{131}I was so low (less than 3.5 mCi in four cases and less than 6.7 mCi in three cases) that the radiation was not sufficient to stop the proliferation of the thyroid cells. In one patient, the dose was not stated. In only four patients of the tens of thousands who have been treated with ^{131}I did a cancer appear after an adequate dose and after a lapse of time sufficient to allow for its possible induction by radiation.

Nodular goiter with hyperthyroidism is not as common as Graves' disease, and often it is associated with a larger nodular goiter for which thyroidectomy is a more effective treatment than ^{131}I . Nevertheless a cancer of the thyroid has been reported 3 years and 9 months after treatment with 30 mCi ^{131}I .² The cancer was on the side opposite the original adenoma and probably, because of its appearance so soon after the treatment, it was not

caused by the radiation. The case reported here is similar in that cancer appeared after radiation for a nodular goiter with hyperthyroidism and probably was present before the treatment was given.

Case report

The patient was a 46-year-old woman, who in 1943, at age 29, had had two subtotal thyroidectomies for hyperthyroidism. Fourteen years later the goiter recurred along with symptoms of hyperthyroidism, and she was treated with propylthiouracil and iodine.

In June 1960 she was seen for the first time at the Cleveland Clinic. Iodine and thiouracil were discontinued. Pulse rate was 120 and blood pressure 130/80 mm Hg. Despite a good appetite she had lost 18 kg (40 pounds) and was nervous. The basal metabolic rate was +15%. Both lobes of the thyroid were enlarged and nodular and were estimated to weigh 75 g. The uptake of radioactive iodine was 76%. She was treated with 25 mCi ^{131}I . Two months later the uptake was still 56% and the basal metabolic rate +13%. The gland was a little smaller. An additional 10 mCi was given. Two months later the goiter had disappeared except for a hard nodule in the upper pole of the left lobe.

In February 1961, 6 months after her first treatment, the basal metabolic rate was +21%, the pulse rate 108, and the ^{131}I uptake 33%. Twenty mCi ^{131}I was given. Two months later the basal metabolic rate had fallen to -4%, and the pulse rate was 88. Clinically the hyperthyroidism was completely controlled. The patient was advised to take thyroid, 2 grains, which she did intermittently, but never regularly. Two years later the basal metabolic rate was -24%, and she was advised to continue taking thyroid; however, she failed to do this regularly.

In September 1975, the patient returned complaining of dysphagia, for which no cause could be found. She was obese. The thyroid was described as having a firm nod-

ule in the left lobe. Clinically she was euthyroid.

A roentgenogram of the chest showed "multiple nodules in both lungs," which had not been present in 1964. Aspiration biopsy of one of these nodules was performed under fluoroscopic control and was interpreted as showing a "lumined microfragment suggestive of follicular carcinoma of the thyroid." Despite the fact that she had not taken thyroid regularly, thyroid function appeared to be normal with an effective thyroxine ratio of 1.02 (normal, 0.86 to 1.07). The thyroid scan showed irregular uptake, mostly in the right lobe where a small nodule was palpable, but this nodule appeared to be picking up ^{131}I .

Although no pulmonary nodules had been observed in the 1964 roentgenogram of the chest, a roentgenogram taken in 1965 at another hospital and reviewed after the 1975 roentgenogram was taken showed (retrospectively) that many of the nodules seen in 1975 had been present in 1965. Since this was only 5 years after treatment with ^{131}I , it seems unlikely that the primary cancer could have been the result of the treatment and that in less than 5 years it could have metastasized so extensively. Although differentiated carcinomas of the thyroid have been reported to have occurred within 5 years of the time of exposure to radiation, we are not aware of any that have been reported to have shown distant metastases in so short a time.

In September 1975, one of us (C.B.E.) did a total thyroidectomy, and transplanted two parathyroids into the sternomastoid muscle. The gland was nodular and showed extensive fibrosis and calcification. Frozen section diagnosis was calcified follicular adenoma, but on permanent section there was in addition a focus of follicular carcinoma or follicular variant of a papillary carcinoma that was invading the capsule of the remnant of the right lobe.

After operation, there was transient tetany followed by complete recovery in 2 months. Despite total thyroidectomy (proved by scan) and despite taking no thyroid medication, the patient remained euthyroid with

the value of the effective thyroxine ratio, 0.94 (normal, 0.86 to 1.07). This and an uptake in the chest of 6% of a total body dose of 1 mCi of ^{131}I indicated that the pulmonary nodules were taking up ^{131}I (Fig. 1). In November 1975 the patient was given 150 mCi ^{131}I . A month later, a roentgenogram showed that the nodules had decreased in size, and in January 1976 the nodules had disappeared. (Fig. 2). She was given sodium levothyroxine (Synthroid), 0.15 mg daily, and when last seen in June 1977, there was no evidence of persistence of the cancer.

Discussion

Although there is no question that a follicular cancer of the thyroid was discovered after treatment with ^{131}I , the fact that the goiter at the time of treatment was nodular and that pulmonary metastases appeared less than 5 years after the ^{131}I was given suggests that the cancer was already present in the thyroid at the time of treatment. Moreover, the patient failed to take the suppressive doses of thyroid that might have prevented the growth and metastasis of the tumor.

The developments in this case do not

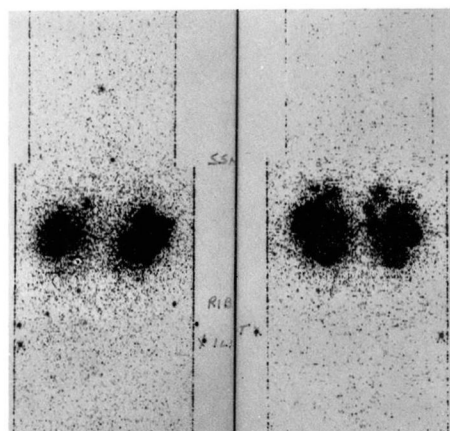


Fig. 1. Anterior and posterior views of the thorax and abdomen from a ^{131}I total body scan showing multiple discrete rounded areas of uptake by functioning metastatic thyroid tumor in both lungs.

in any way argue against the routine use of radioactive iodine in patients with Graves' disease with diffuse goiters, and they should not be taken to imply that the treatment with ^{131}I caused the cancer. They do, however, argue strongly for emphasizing to such patients the necessity of taking full suppressive doses of thyroid as a lifelong program. It also raises the question of whether in nodular goiters in younger patients the use of ^{131}I might result in exposure of certain cells to carcinogenic doses of radiation.

In diffuse goiters doses of radioactive iodine sufficiently large to control the hyperthyroidism expose the whole gland to radiation of homogeneous intensity and of sufficiently high dosage to insure shrinkage of the gland and inability of the cells to reproduce or give rise to cancers. Thus in patients with Graves' disease and diffuse goiter, ^{131}I in full therapeutic dose actually protects against the possible development of thyroid cancer. In an experience with 5123 patients with Graves' disease treated at the Cleveland Clinic with ^{131}I we have seen no cancers.

In nodular goiters, however, the uptake of ^{131}I is irregular. It may be concentrated in nodules, in which case it exposes the rest of the gland to low-dose radiation in the range of carcinogenicity. Also the ^{131}I may be taken up by the parenchyma and give carcinogenic doses of radiation to cold nodules. In any event, unless special indications are present it may be wise to withhold ^{131}I in the treatment of hyperthyroidism in young people with nodular goiters. Hamburger and Meier² have also reported a case in which cancer of the thyroid occurred after treatment of a nodular goiter with ^{131}I , but in this case too, the cancer appeared so early (3 years 9 months after treatment) that it seems likely that it had been present at

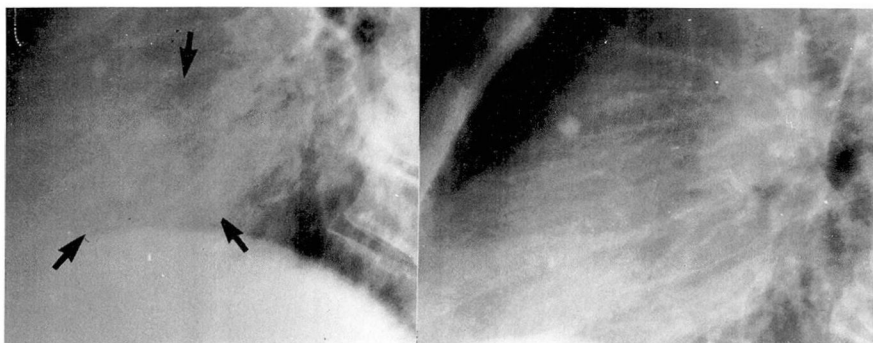


Fig. 2. Lateral chest roentgenogram coned down to the lower half of the lung fields showing pre- ^{131}I treated nodules in the lower lung fields on the left and subsequent clearing of such nodules on the chest roentgenogram obtained months later.

the time the ^{131}I was given. Thus in neither Hamburger and Meier's case nor in ours is there any proof of a causal relationship between treatment with ^{131}I and the appearance of the cancer of the thyroid.

Summary

A case is reported in which pulmonary metastases of a carcinoma of the thyroid appeared 5 years after nodular goiter with hyperthyroidism was treated with ^{131}I .

The safety of treating Graves' disease without nodules with ^{131}I is emphasized and the theoretical, but unproved danger of using ^{131}I in treating young patients with nodular goiters is pointed out.

In this case, it is likely that the cancer was already present in the thyroid at the time of the treatment with ^{131}I . This patient failed to take suppressive doses of thyroid. To prevent progressive growth of occult cancer, it is important for all patients treated by ^{131}I to take suppressive doses of thyroid as a lifetime protection against stimulation of the tumor cells by thyroid stimulating hormone.

References

1. McDougall IR: Thyroid cancer after iodine- 131 therapy. *JAMA* 227: 438, 1974.
2. Hamburger JI, Meier DA: Cancer following treatment of an autonomously functioning thyroid nodule with sodium iodide I 131. *Arch Surg* 103: 762-764, 1971.