

Practical application of the flow-volume loop

Joseph A. Golish, M.D.
Muzaffar Ahmad, M.D.
James R. Yarnal, Ph.D., D.O.

Department of Pulmonary Diseases

Diminished airflow is the abnormality most frequently noted on spirometry. This finding is not always caused by intrinsic airways obstruction, but can be caused by a variety of other pathogenetic mechanisms. Apart from diffuse bronchial obstruction, these include small airways disease, upper airway obstruction, suboptimal effort of the patient, muscular weakness, and restrictive lung diseases. Such problems may not be readily distinguishable by spirometry, but a special physiologic test, the flow-volume loop can be helpful in their differentiation.

Standard spirogram versus flow-volume loop

The flow-volume loop is merely one kind of graphic display of breathing mechanics during the forced vital capacity maneuver. The vital capacity (VC) is the maximum volume of air that an individual can expel after maximum inspiration (*Fig. 1*). Residual volume (RV) is that volume of air that remains after maximal exhalation. Total lung capacity (TLC) is the sum of those two volumes. When the vital capacity maneuver is performed at a maximal rate, it is called a forced vital capacity (FVC). The standard spirogram (V-t) is the most commonly used graphic display of the forced vital capacity maneuver. The measured parameters are

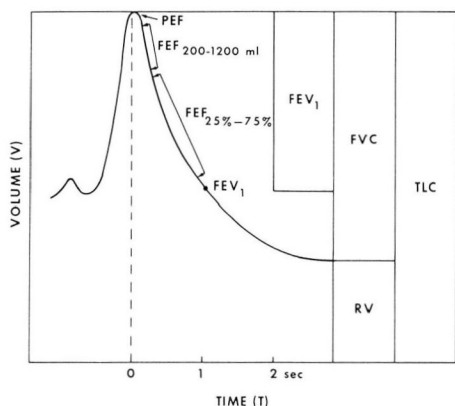


Fig. 1. Lung compartments and the standard spirogram.

volume (V) on the vertical axis and time (t) on the horizontal axis. From this curve, one can derive the forced expiratory volume in one second (FEV_1), the peak expiratory flow (PEF), the forced expiratory flow at 200 to 1200 ml ($FEF_{200-1200\text{ ml}}$), and the maximum mid-expiratory flow rate ($FEF_{25\%-75\%}$). Together, these flows can provide information about the patient's effort, neuromuscular strength, large airway patency, and the status of the small airways.

The flow-volume loop is also a graphic display of the forced vital capacity maneuver (Figs. 2 and 3A). As opposed to the simple spirogram, however, the measured parameters are volume (V) on the horizontal axis and flow (\dot{V}) on the vertical axis. Since variation in flow is a more dynamic and sensitive measurement than either volume or time, much more information is available regarding breathing mechanics. In addition, the inspiratory phase is also recorded. The patient begins at RV and makes a maximal inspiratory effort as deeply and as rapidly as possible. The negative intrapleural pressure dilates the intrathoracic airways and overcomes the elastic recoil of the lung and chest wall. Flow gradually increases in a

dome-shaped fashion, when it again gradually diminishes as the lungs fill with air and the intrapleural pressure becomes less negative. At TLC all flow stops. The volume between RV and TLC is the VC. The patient then performs a forced vital capacity maneuver. The combination of maximal elastic recoil, maximum muscular effort, and fully dilated airways results in a sudden spike to a PEF. The flow rate then linearly decreases as recoil, muscular effort, airway caliber, volume, and pleural pressure diminish. At RV, all flow ceases.¹

Many pulmonary function laboratories obtain the loop by first having the patient forcibly exhale and follow this by forced inspiration. In our laboratory, this is done in reverse. Forced inspiration is the initial maneuver followed by exhalation. Although this sequence was originally used for technical reasons, it does provide additional information for the interpreter. With this method, a difference in the inspiratory and expiratory VC when present can be appreciated. This difference in sequencing of the forced inspiratory and expiratory maneuvers accounts for the inversion of the loop in some laboratories.

The flow-volume loop is not only described by its graphic appearance but

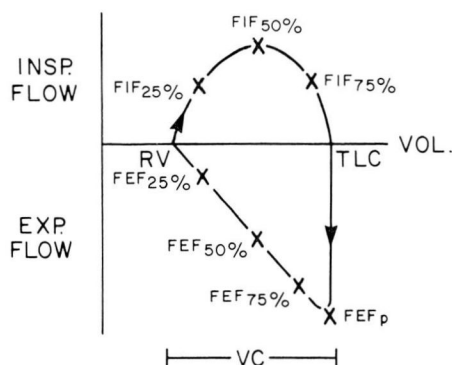


Fig. 2. Normal flow-volume loop.

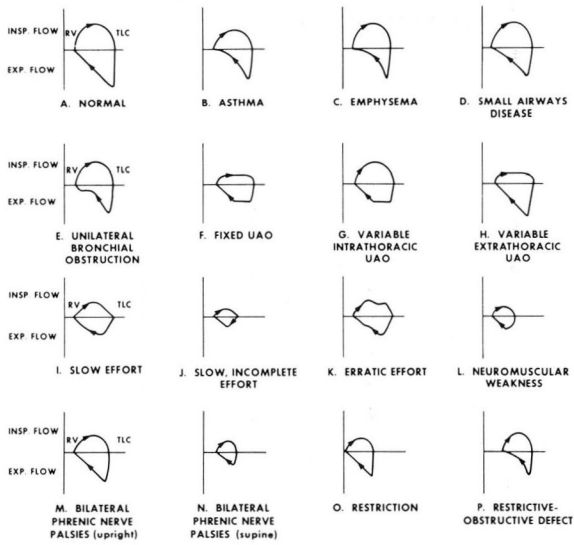


Fig. 3. Examples of flow-volume loop.

also by a series of flow rates derived from each portion of the curve (Fig. 2). Instantaneous flow rates (FIF, FEF) are measured at one fourth, one half, and three fourths of the VC during inspiration and expiration. Peak inspiratory and expiratory flows (FIF_p, FEF_p) are also measured. On the normal curve the peak inspiratory flow tends to occur at about 50% of VC and the FIF_{25%} and FIF_{75%} are about equal. The FEF_p occurs at a somewhat higher point in the VC than the FEF_{75%}. The FEF_p tends to be about one and a half times that of the peak inspiratory flow (FEF_p/FIF_p ratio). The ratio between the FIF_{50%} and FEF_{50%} is approximately one on a normal loop (mid-VC ratio). These relationships are disrupted by abnormal breathing mechanics.

These flow rates have a counterpart in the flow rates of the standard spirogram (Table 1). The flow rates of the standard spirogram, however, include a mixture of volume and time indices; therefore, their relationship to each other and to the flow rates of the flow

Table 1. Spirometric flow rates and their counterpart in the flow-volume loop

| V-t spirogram | \dot{V} -V loop |
|----------------------------|-------------------------------|
| FVC | FVC |
| PEF | FEF _p |
| FEF ₂₀₀₋₁₂₀₀ ml | FEF _{75%} (50%, 25%) |
| FEF _{25%-75%} | FEF _{50%} |

volume curve is variable, depending on absolute lung volume. In addition, the loop is inscribed during a combined inspiratory and expiratory maneuver, as opposed to the spirogram, which consists of exhalation alone. This difference in technique may also alter the relationship between respective volumes and flows.

In clarification of the pathogenetic mechanism of diminished airflow, the flow-volume loop may be superior to the volume-time spirogram. The flow-channel and its graphic display are much more sensitive indicators of subtle changes in airway dynamics. A greater sampling of expiratory flow rates is ob-

tained and disproportionality between those flow rates can be more readily identified for aid in differential diagnosis. Unlike the standard spirogram, the flow rates themselves maintain a consistent relationship with one another, independent of lung volume. Inspiratory flow is also measured with this study, and relationships between inspiratory and expiratory flow can be numerically described. The mid vital capacity ratio (FEF_{50%}/FIF_{50%}) is one such value that can be useful in identifying upper airway obstruction.

A frequently made error in interpretation of the flow-volume loop is overemphasis on flow rates derived from the curve rather than from the configuration of the curve itself. The flow rate is merely a single point on a given graphic display. It reflects statistical severity of impairment by comparing the patient to a population. Proportionality between flow rates may be of some diagnostic help but rarely provides the definitive answer. The configuration of the curve, however, provides an infinite number of flow rates and their relationships to each other. Proportionality is "built-in" when a curve is analyzed. Such a curve will often be diagnostic in identifying the mechanism of diminished airflow. Analysis of curve configuration is most helpful in examining the flow-volume loop, although the configuration of the flow-time curve and volume-time curve (spirogram) may also provide useful information.

Applications of the flow-volume loop

Reduction in flow is often thought to indicate the presence of obstruction. This is not necessarily so, however, since many other factors can limit flow.² Flow is proportional to the change in pressure across an airway divided by the intrinsic

resistance of that airway, as depicted in the equation $\dot{V} \propto \Delta P/R_{aw}$ (Table 2). Diffuse bronchial obstruction is not the only cause of increased airways resistance ($\uparrow R_{aw}$). Upper airway obstruction can produce an elevated airways resistance, as can the small airway caliber of restrictive disease and the diminished elastic support seen in emphysema. A reduction in the pressure gradient ($\downarrow \Delta P$) across an airway is demonstrated in patients with inadequate effort, neuromuscular weakness, and in restrictive ventilatory defects. Therefore, a variety of disorders can produce diminished flow without necessarily incriminating diffuse bronchial obstruction. The role of the flow-volume loop is to identify the pathogenetic mechanism of decreased flow when one of these other disorders is suspected.

The mechanisms of diminished flow due to obstruction can be subdivided into diffuse bronchial obstruction and upper airway obstruction (Table 3). Characteristically, bronchial obstruc-

Table 2. Mechanisms of diminished airflow

| $\dot{V} \propto \frac{\Delta P}{R_{aw}}$ | |
|-------------------------------------------|----------------------------------------------------------------------------------------------------------------------------------------------------------------------|
| $\uparrow R_{aw}$ | Intrinsic airways disease Bronchitis, asthma Upper airway obstruction Loss of elastic support Emphysema Diminished lung volume Restrictive disease |
| $\downarrow \Delta P$ | Inadequate effort Voluntary Neuromuscular disease Loss of elastic recoil Emphysema Diminished lung volume Restrictive disease |

Table 3. Causes of diminished airflow

| |
|-------------------------------------|
| Diminished flow due to obstruction |
| Bronchial obstruction |
| Diffuse |
| Bronchial asthma |
| Pulmonary emphysema |
| Small airways disease |
| Unilateral mainstem stenosis |
| Upper airway obstruction |
| Fixed |
| Variable intrathoracic |
| Variable extrathoracic |
| Diminished flow without obstruction |
| Inadequate effort |
| Voluntary |
| Involuntary |
| Neuromuscular weakness |
| Generalized |
| Diaphragmatic only |
| Restrictive disease |
| Pulmonary parenchymal |
| Extrapulmonic |

tion produces an abnormality in the mid and late expiratory portion of the flow-volume loop. In diffuse bronchial obstruction, that abnormality consists of a bowing configuration at the mid and late part of the expiratory phase³ (*Fig. 3B*). The inspiratory VC may be greater than the expiratory VC, and the discrepancy is apparent on the loop as a “gap” between the starting point and end-point of the loop. This air trapping is more prominent in emphysema than asthma, and unusual in chronic bronchitis, because of the fairly normal compliance in the last two disorders. As opposed to asthma, inspiratory flow is well preserved in emphysema (*Fig. 3C*), and the mid-expiratory bowing persists after the use of bronchodilators.

When bronchial obstruction is limited to the small airways, the bowing configuration of the loop is confined to the very latest portion of the expiratory curve (*Fig. 3D*). Superimposing a flow-volume loop performed with helium can provide another parameter of small air-

ways disease. The point of intersection of these two loops occurs when flow is no longer turbulent and density-dependent, but rather laminar and independent of different gas densities (helium versus air). This point is called the volume of isoflow and is elevated in the presence of small airways obstruction. In unilateral bronchial obstruction, for example, due to a unilateral mainstem bronchogenic carcinoma, a plateau may occur late in the expiratory phase of the loop⁴ (*Fig. 3E*).

When airflow is diminished due to upper airway obstruction, the loop is abnormal in the early inspiratory and/or expiratory portions.⁵ In fixed upper airway obstruction, a plateau is seen early in the inspiratory and expiratory phases. This results in a boxlike configuration to the loop (*Fig. 3F*). In the variable intrathoracic upper airway obstruction, that plateau only occurs early in expiration (*Fig. 3G*). In contradistinction, the variable extrathoracic upper airway obstruction produces a plateau early in inspiration only (*Fig. 3H*).

The flow-volume loop is also helpful in elucidating mechanisms of decreased airflow not due to obstruction (*Table 3*). These include inadequate effort, neuromuscular weakness, and restrictive disease. Inadequate effort can mimic almost any pattern on the flow-volume loop. The only characteristic finding is that the loop is not reproducible on successive efforts. Frequently the VC is low and variable on successive efforts. The normally smooth dome of inspiration and the sharp spike and linear decrease in exhalation tend to be quite bizarre and nonreproducible. The most effort-dependent flow rates, that is, the FEF_p and the FEF_{75%} are greatly reduced. The less effort-dependent flow rates such as the FEF_{50%} and FEF_{25%} are

less affected. The comment of the technician regarding effort is often quite helpful in identifying the uncooperative patient.

Figure 3I is an example of the complete but slow inspiratory and expiratory effort. *Figure 3J* is an example of efforts neither complete nor performed in a forced fashion. *Figure 3K* demonstrates not only incomplete inspiration and expiration and a submaximal effort, but also demonstrates a rather erratic maneuver. These "poor-effort" patterns may be generated for a variety of reasons. They can occur volitionally, as in the disinterested patient or the malingerer applying for pulmonary disability. Involuntary causes of suboptimal effort include uncontrollable cough, chest or abdominal pain, communication difficulties, or general debility.

Generalized neuromuscular weakness will produce diminished flow as measured by the flow-volume loop. Characteristically, however, the patient's cooperation and understanding are rated good by the pulmonary function technician and the graphic configuration is quite reproducible. The VC tends to be diminished and the most effort-dependent early expiratory flows are reduced. The expiratory portion of the curve tends to present a very late and rounded peak⁶ (*Fig. 3L*). The FEF_{75%} and the FEF_p are most diminished, whereas the late expiratory flows and all of the inspiratory flows are reduced only proportionally to the low VC. A variety of neurological diseases can produce this pattern, including amyotrophic lateral sclerosis, myasthenia gravis, and polymyositis.

Neuromuscular weakness isolated to the diaphragm results in a flow-volume loop with a normal configuration. The loop, however, is restricted in VC and when the patient assumes a supine po-

sition, severe reduction in the VC will result and may be associated with respiratory distress⁷ (*Fig. 3M and N*). Such bilateral phrenic nerve palsies may be isolated and idiopathic, or occur as part of a more generalized peripheral neuropathy.

Restrictive disease can cause reduction in airflow due to decreased VC, but like bilateral diaphragmatic weakness, the loop has a normal configuration⁸ (*Fig. 3O*). In contradistinction, however, there is no significant further reduction in the VC on assuming the supine position. The restriction may be due to an extrapulmonic cause such as kyphoscoliosis, bilateral pleural effusions, or massive ascites. Intrapulmonic restriction is often the result of pulmonary parenchymal disease such as sarcoidosis. A combined restrictive/obstructive defect such as bronchiectasis (*Fig. 3P*) will result in a small loop with an expiratory concavity.

A clear understanding of breathing mechanics as illustrated by the flow-volume loop can improve our insight into the standard pulmonary function tests. Many of the abnormalities discussed above could indeed be suspected or diagnosed on the basis of spirometry. In addition, many spirometers used for pulmonary function testing have the capability of generating a flow-time curve. This curve is quite analogous to the expiratory portion of the flow-volume loop and can frequently identify the mechanism of diminished airflow.

Summary

The flow-volume loop accurately and inexpensively clarifies disrupted breathing mechanics. Diminished airflow is a frequent finding on pulmonary function testing and is not necessarily due to airflow obstruction. Some other pathogenetic mechanism may be active in a

given patient and cause diminished airflow. The flow-volume loop can distinguish diffuse bronchial obstruction from small airways disease, upper airway obstruction, suboptimal patient effort, neuromuscular weakness, and restrictive disease. This physiologic test should be used whenever such an abnormality is suspected.

References

1. Hyatt RE, Black LF: The flow-volume curve; a current perspective. *Am Rev Respir Dis* **107**: 191-199, 1973.
2. Jordanoglou J, Pride NB: Factors determining maximum inspiratory flow and maximum expiratory flow of the lung. *Thorax* **23**: 33-37, 1968.
3. Bass H: The flow-volume loop; normal standards and abnormalities in chronic obstructive pulmonary disease. *Chest* **63**: 171-176, 1973.
4. Lord GP, Gazioglu K, Kaltreider N: The maximum expiratory flow-volume in the evaluation of patients with lung disease; a comparative study with standard pulmonary function tests. *Am J Med* **46**: 72-79, 1969.
5. Kryger M, Bode F, Antic R, et al: Diagnosis of obstruction of the upper and central airways. *Am J Med* **61**: 85-93, 1976.
6. Kreitzer SM, Saunders NA, Tyler HR, et al: Respiratory muscle function in amyotrophic lateral sclerosis. *Am Rev Respir Dis* **117**: 437-447, 1978.
7. Kreitzer SM, Feldman NT, Saunders NA, et al: Bilateral diaphragmatic paralysis with hypercapnic respiratory failure; a physiologic assessment. *Am J Med* **65**: 89-95, 1978.
8. Carilli AD, Denson LJ, Rock F, et al: The flow-volume loop in normal subjects and in diffuse lung disease. *Chest* **66**: 472-477, 1974.