

Nonhomogeneous copper distribution in primary biliary cirrhosis

William D. Carey, M.D.

Department of Gastroenterology

Considerable attention has been focused recently upon tissue copper levels in patients with primary biliary cirrhosis (PBC). Elevated hepatic copper levels in PBC were first demonstrated by neutron activation studies of tissue obtained at surgery or postmortem.¹ Six patients with PBC had copper levels 30 times normal. These observations were corroborated by others.²⁻⁵ There is little information regarding homogeneity of the distribution of copper in the liver, although the available evidence suggests that there are no major regional hepatic differences in PBC.³ A case of PBC has recently been encountered in which regional differences in hepatic copper concentration have been documented. The copper level was elevated in the area of the liver that was most abnormal morphologically and histologically.

Case report

A 44-year-old black woman was examined at the Cleveland Clinic for the first time in September 1977. Her chief complaint was intermittent swelling of both hands for 3 months. She also noted some hard crusted lesions on the volar aspect of the distal and proximal phalanges and on the tips of the fingers. She described a color change associated with a burning sensation when her hands were exposed to cold. She denied esophageal symptoms, pruritus, or constitutional symptoms.

Her height was 164 cm (65.6 inches); weight, 58.5 kg (128.7 pounds); pulse rate, 80 and regular; and blood pressure, 130/78 mm Hg. The general examination revealed a healthy woman. The skin abnormalities were limited to the hands; there were several pitting ulcers of the fingertips and the skin was dry. There was no atrophy. There were also small, hard subcutaneous densities on both thumbs, which were suspected to contain calcium. Examination of the heart, lungs, and abdomen was normal; pulses were normal; neurologic examination was normal.

The following laboratory studies were either negative or normal: serum calcium, inorganic phosphorus, glucose, blood urea nitrogen (BUN), uric acid, total protein, albumin, lactic dehydrogenase (LDH), white blood cell count, hemoglobin, red blood cell indices, urinalysis, platelet count, prothrombin time, serum protein electrophoresis, C1q level, antinuclear factor, serology, and urine porphyrin screen. Abnormal results were a cholesterol of 300 mg/dl (upper limit of normal, 240 mg/dl); bilirubin, 1.3 mg/dl; alkaline phosphatase, 1100 mU/ml (upper limit of normal, 85 mU/ml); 5' nucleotidase, 5.5 units/dl (normal, 0 to .16 units/dl); serum glutamic oxaloacetic transaminase (SGOT), 55 mU/ml (upper limit of normal, 40 mU/ml); serum glutamic pyruvic transaminase (SGPT), 63 mU/ml (upper limit of normal, 42 mU/ml); smooth muscle antibody positive in a titer of 1:10 and antimitochondrial antibody, positive in a titer of 1:160. Quantitative immunoglobulins revealed an IgG of 1500 mg/dl (normal); IgA, 530 mg/dl (increased); IgM, 265 mg/dl (slightly increased). The urine copper level was normal, although the ceruloplasmin was slightly elevated at 40 mg/dl (normal, 20 to 35 mg/dl). The serum copper was 164 μ g/dl (normal, 85 to 155 μ g/dl).

A liver-spleen scan was normal. An oral cholecystogram revealed suboptimal visualization of the gallbladder; an ultrasound examination of the gallbladder was normal. An intravenous cholangiogram showed bile ducts of normal size. A cineesophagogram showed no changes of progressive systemic sclerosis involving the esophagus.

The patient had manifestations of CRST syndrome (calcinosis, Raynaud's sclerodactyly, telangiectasia) and the liver tests and copper studies were suggestive of PBC. A liver biopsy was performed. Several cores of tissue were obtained and a total length of 2 cm was available for staining (hematoxylin and eosin). Further tissue was obtained for qualitative copper stain and for quantitative copper levels. Light microscopy was normal except possibly for a slight decrease in the number of bile ducts (*Fig. 1*). The quantitative copper was 25 μ g/g of dry weight (normal, <50 μ g/g of dry weight).*

Despite the relatively normal liver histology and quantitative copper, it was felt that the patient should have further studies of the liver. Accordingly, a peritoneoscopy was performed 2 months after the original biopsy. The liver appeared normal, except for the presence of several nodules 2 to 4 mm in diameter, redder than the surrounding parenchyma. These nodules were located primarily along the inferior aspect of the liver, a considerable distance from the area where the percutaneous biopsy had been obtained. Biopsies were obtained from the affected areas. Light microscopy showed extensive portal triaditis with some spread to the hepatic parenchyma (*Fig. 2*). There was extensive portal fibrosis and a reduction in the bile duct in the portal area. The specimen was thought to be compatible with primary biliary cirrhosis. The quantitative copper value was 118 μ g/g of dry weight.

The patient was believed to meet the histologic and biochemical criteria for PBC. She was given D-penicillamine, and tolerated the medicine well for 9 months; no symptoms of liver disease have developed. The standard liver tests remain essentially unchanged after 9 months of therapy, except for a slight reduction in the alkaline phosphatase value.

Discussion

The association between CRST syndrome and PBC has been established.⁶

* *Tissue copper studies performed in the laboratory of Dr. I. Sternlieb, Albert Einstein College of Medicine, Bronx, New York.*




Fig. 1. (top) Normal architecture is preserved (Masson stain, $\times 64$). (bottom) Bile ducts, reduced in number, are present (arrows) and are not surrounded by inflammatory response. Copper level is normal (Masson stain, $\times 160$).

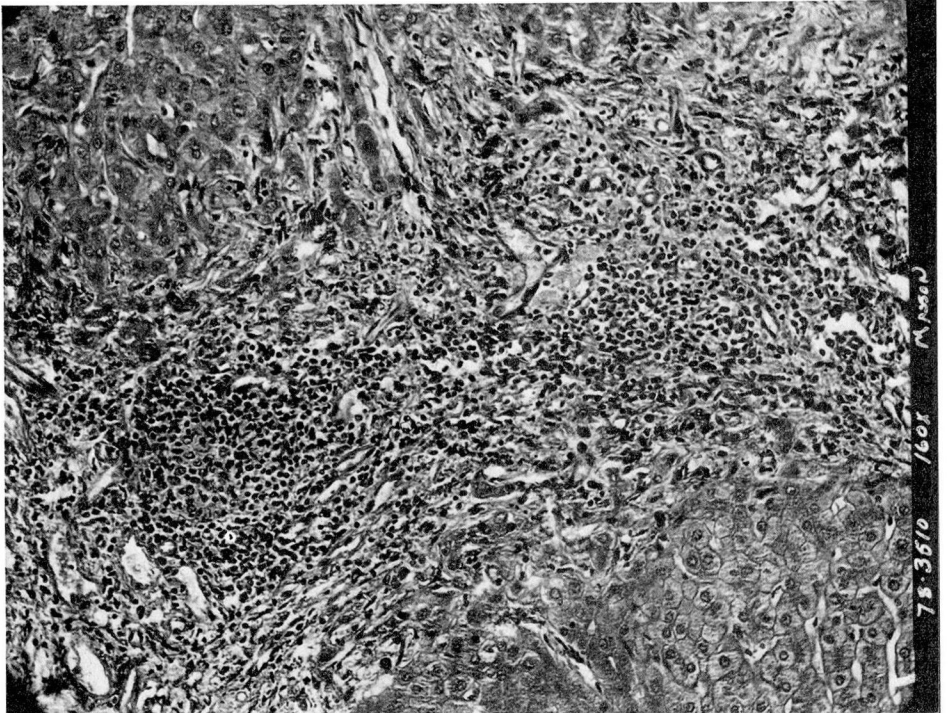
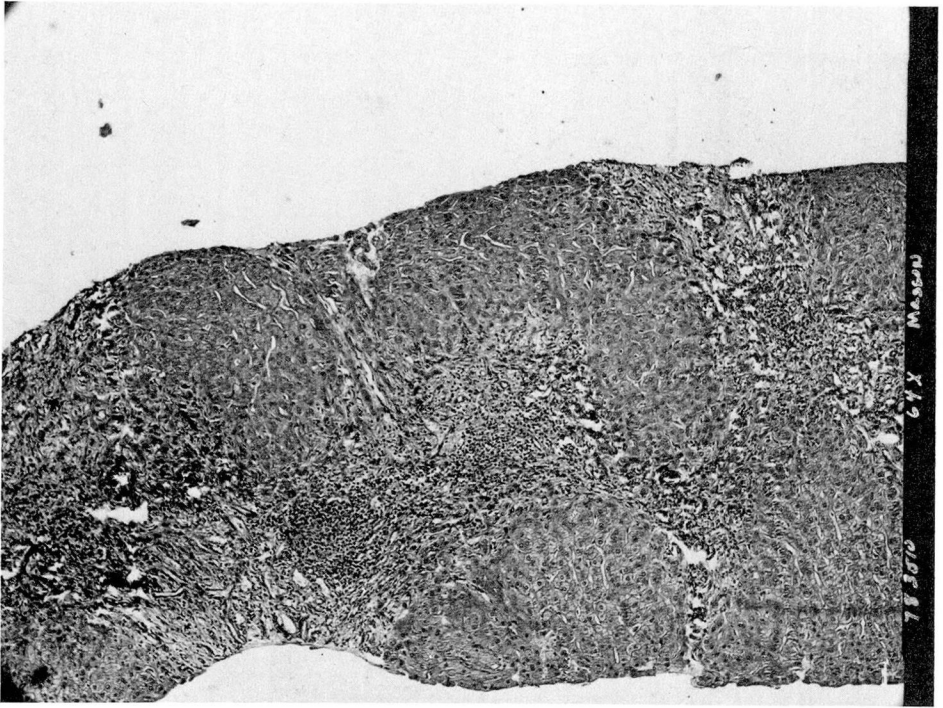


Fig. 2. (top) Wide bands of fibrosis and inflammatory cells suggestive of cirrhosis (Masson stain, $\times 64$). (bottom) No bile ducts are seen in any of the fibrotic areas. Copper level is elevated (Masson stain, $\times 160$).

Additional factors suggesting that PBC might be an autoimmune disease include the frequent occurrence of certain serum antibodies,⁷ abnormal cell-mediated immunity, circulating immune complexes, and abnormalities in the complement system.⁸ The interrelationship between the immune defects and abnormalities of copper metabolism in PBC is not clear.

Liver biopsy is essential in establishing the diagnosis of PBC, although the clinical features and associated abnormal laboratory findings are often suggestive. The histopathology is complex in that the disease passes through four stages.⁹ Percutaneous biopsies, because of the small volume of tissue retrieved, may not contain sufficient numbers of portal areas for the pathologist to make definitive statements regarding abnormalities of the bile ductules either qualitatively or quantitatively. Moreover, percutaneous biopsies may be insufficient for the diagnosis of cirrhosis in up to 60% of cases in which cirrhosis has been proved to exist.^{10, 11} The superiority of laparoscopy for establishing the presence of cirrhosis has been demonstrated.¹¹ In our patient the two biopsy specimens were clearly divergent with regard to the presence and degree of inflammation and fibrosis.

Hepatic copper concentrations are greatly elevated in most patients with PBC.¹² The mean value is similar to that of Wilson's disease. Copper also accumulates in the renal cortex and spleen. Unlike Wilson's disease, copper does not accumulate in the brain.³ Additionally, the ceruloplasmin levels, nearly always low in Wilson's disease, are usually elevated in PBC. These features plus clinical and standard biochemical parameters usually provide the clinician with enough information to differentiate between PBC and Wil-

son's disease. More difficult may be the differentiation between PBC and chronic active hepatitis,¹³ where occasionally clinical and serologic markers are of no help, and a therapeutic trial is the only diagnostic approach available.

An equivocal liver biopsy and a normal hepatic copper level may dissuade the physician from accepting the diagnosis of PBC. This case should serve as a reminder that a percutaneous biopsy may not provide representative tissue either for histologic study or for determination of copper levels. A review of other series suggests that our case is not unique. For example, Deering et al¹² found that two of 45 patients (4%) had normal hepatic copper levels at the pretreatment assessment. Are these true normal copper levels or does this reflect sampling error? Smallwood et al² showed little sampling variation of copper levels in two normal patients and substantial variation in at least one of three cirrhotic livers tested. They speculated that this variation of copper levels in different tissue specimens from the same liver is due either to uneven distribution of copper in the parenchyma or to the varying amounts of fibrous tissue present in each sample. In a larger study, Fleming et al³ reported liver copper levels in multiple random biopsies in 48 patients, eight of whom had PBC. They found only modest variations in copper distribution (a coefficient of variation of 6% to 36%) and concluded that a single liver biopsy reliably reflects hepatic copper stores. It is reasonable to infer that the patients in this postmortem study had advanced disease. After years of defective copper excretion, the distribution of copper may become homogeneous, even though at an early stage it may not have been so.

Analysis of two series^{12, 14} of patients with PBC is consistent with the notion

that an uneven distribution of copper may occur. Of the placebo-treated patients in the Mayo series,¹² the hepatic copper showed no change over the course of one year. However, eight of 17 patients had *less* hepatic copper, and two of these eight had substantially less (a reduction of more than 100 $\mu\text{g/g}$ of dry weight) even though no specific therapy was given. Although these patients were placed on a low-copper diet, it seems unlikely that this maneuver alone accounts for the observed fall in tissue copper. Similarly, Jain et al¹⁴ reported that in two of seven placebo-treated PBC patients, tissue copper levels were greatly reduced after 12 months. In one case the reduction in liver copper was 1000 $\mu\text{g/g}$ of dry weight liver. Six of 19 patients treated with D-penicillamine at the Mayo Clinic had *higher* copper levels in the biopsy specimens done after a year of treatment. Advancing disease, noncompliance with medication, and heterogeneity of diseases called PBC may help to explain the unexpected rise in hepatic copper; but, again, nonuniform distribution of copper early in the disease may explain the paradoxical rise observed.

Summary

A case of PBC is reported in which the initial percutaneous biopsy and quantitative tissue copper determinations failed to support the diagnosis of PBC. At laparoscopy the liver was involved focally with a nodular process. Biopsy specimens and copper levels from these involved nodules were highly suggestive of PBC. The occasional occurrence of nonhomogeneous distribution of copper in the liver in PBC seems likely. The relevant literature is reviewed. Several biopsies, preferably done at laparoscopy, should be considered in patients in whom biopsy mate-

rial obtained percutaneously does not support PBC suspected clinically. Further studies of sampling error in early PBC are warranted.

Acknowledgment

We thank William A. Hawk, M.D. for reviewing the histologic material.

References

1. Hunt AH, Parr RM, Taylor DM, et al: Relation between cirrhosis and trace metal content of liver; with special reference to primary biliary cirrhosis and copper. *Br Med J* 2: 1498-1501, 1963.
2. Smallwood RA, Williams HA, Rosenoer VM, et al: Liver-copper levels in liver disease; studies using neutron activation analysis. *Lancet* 2: 1310-1313, 1968.
3. Fleming CR, Dickson ER, Baggenstoss AH, et al: Copper and primary biliary cirrhosis. *Gastroenterology* 67: 1182-1187, 1974.
4. Worwood M, Taylor DM, Hunt AH: Copper and manganese concentrations in biliary cirrhosis of liver. *Br Med J* 3: 344-346, 1968.
5. Ritland S, Steinnes E, Skrede S: Hepatic copper content, urinary copper excretion, and serum ceruloplasmin in liver disease. *Scand J Gastroenterol* 12: 81-88, 1977.
6. Reynolds TB, Denison EK, Frankl HD, et al: Primary biliary cirrhosis with scleroderma, Raynaud's phenomenon and telangiectasia; new syndrome. *Am J Med* 50: 302-312, 1971.
7. Doniach D, Roitt IM, Walker JG, et al: Tissue antibodies in primary cirrhosis, active chronic (lupoid) hepatitis, cryptogenic cirrhosis and other liver diseases and their clinical implications. *Clin Exp Immunol* 1: 237-262, 1966.
8. Jones EA: Primary biliary cirrhosis and the complement system. *Ann Intern Med* 90: 72-84, 1979.
9. Scheuer PJ: Biliary disease and chronic hepatitis, *in*, *Liver Biopsy Interpretation*, 2nd ed. Scheuer PJ, ed. Baltimore, Williams and Wilkins, 1973, pp 25-39, 66-73.
10. Soloway RD, Baggenstoss AH, Schoenfield LJ, et al: Observer error and sampling variability tested in evaluation of hepatitis and cirrhosis by liver biopsy. *Am J Dig Dis* 16: 1082-1086, 1971.
11. Vido I, Wildhirt E: Korrelation des laparoskopischen und histologischen Befundes bei chronischer Hepatitis und Leberzirrhose. *Deutsch Med Wschr* 94: 1633-1637, 1969.

12. Deering TB, Dickson ER, Fleming CR, et al: Effect of D-penicillamine on copper retention in patients with primary biliary cirrhosis. *Gastroenterology* **72**: 1208-1212, 1977.
13. Geubel AP, Baggenstoss AH, Summerskill WHJ: Responses to treatment can differentiate chronic active liver disease with cholan-
gitic features from the primary biliary cirrhosis syndrome. *Gastroenterology* **71**: 444-449, 1976.
14. Jain S, Scheuer PJ, Samourian S, et al: A controlled trial of D-penicillamine therapy in primary biliary cirrhosis. *Lancet* **I**: 831-834, 1977.