

Ultrasonography in the diagnosis of obstructive uropathy caused by papillary necrosis

Edward Buonocore, M.D.

Department of Hospital Radiology

Donald G. Vidt, M.D.

Department of Hypertension and Nephrology

James E. Montie, M.D.

Department of Urology

Ultrasonography has become increasingly more important in the diagnosis of renal disorders.^{1,2} Compartmental renal anatomy is clearly delineated by ultrasonography without contrast media or instrumentation.³ This is particularly desirable in patients with acute renal failure where rapid differentiation between urinary tract obstruction and end organ failure is vital to successful therapy.

Recent experience with a young diabetic woman with acute renal failure and oliguria complicated by obstruction of the left ureter from papillary necrosis prompts this report. The differentiation between end-stage diabetic nephropathy (necessitating renal dialysis) and urinary tract obstruction (requiring surgical intervention) was important for the medical care and prognosis for this patient.

Case report

A 20-year-old white woman was transferred to the Cleveland Clinic after 5 days in a local hospital. She was febrile, had left lower abdominal pain, nausea, vomiting, and diarrhea, and increasing renal failure and oliguria were developing. Juvenile onset diabetes mellitus had been noted since she was 7 years old.

On admission to the medical services, the creatinine level was 7.7 mg/dl and the blood urea nitrogen (BUN) was 84 mg/dl.

The physical examination was difficult because of

exquisite lower abdominal tenderness. Urine output had fallen to less than 100 cc/day. Surgical and gynecologic consultants found no evidence of an abdominal mass or indications of an acute surgical abdomen. Several diagnoses were considered including urinary tract infection with obstruction, inflammatory bowel disease, tubal pregnancy, and sepsis. The history of long-term juvenile diabetes indicated the possibility of end-stage renal disease or papillary necrosis. Hemodialysis was contemplated.

Ultrasonograms of the kidneys' demonstrated moderate left renal pelvic dilatation and irregular enlargement of the upper pole calyx (*Fig. 1A and B*). The ureters were not identified. The right renal pelvis was of normal size. The preliminary diagnosis of left urinary tract obstruction prompted immediate urologic consultation. Retrograde passage of a catheter into the left ureter resulted in a hydronephrotic drip at 10 cm above the bladder and drainage of purulent urine from the left renal pelvis. The retrograde pyelo-

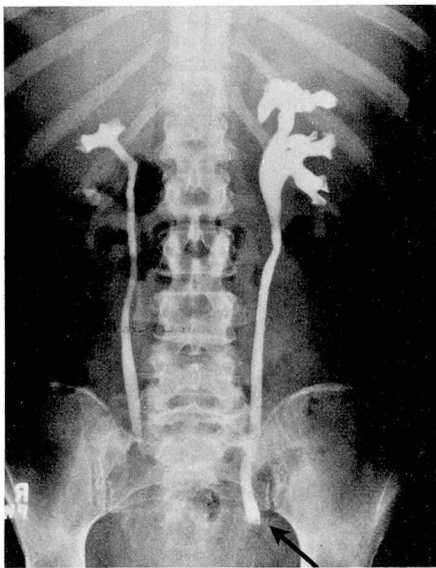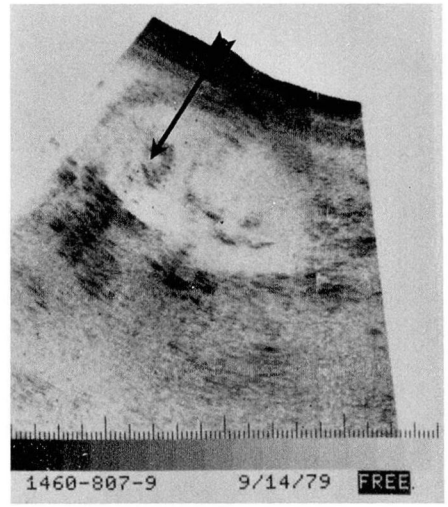
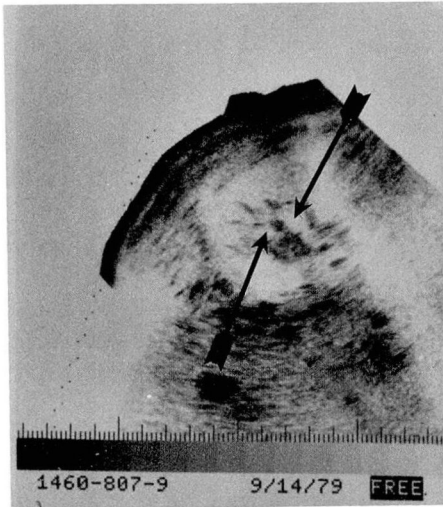


Fig. 1. **A,** (top left) Transverse ultrasonic view of the left kidney with urinary tract obstruction and papillary necrosis. Note the lucent (white) round areas (arrows), which represent dilated renal calyces and infundibuli. **B,** (top right) Longitudinal ultrasonography of same kidney; an irregular dilated calyx is identified in the upper pole of the left kidney (arrow), which corresponds to the area of papillary necrosis that has left an area of dilatation in the upper urinary collecting system. **C,** (bottom left) Retrograde pyelogram after catheter withdrawal. Note dilated pelvis and irregular calyces of left kidney and the dilated left ureter with filling defect in its distal third (arrow).

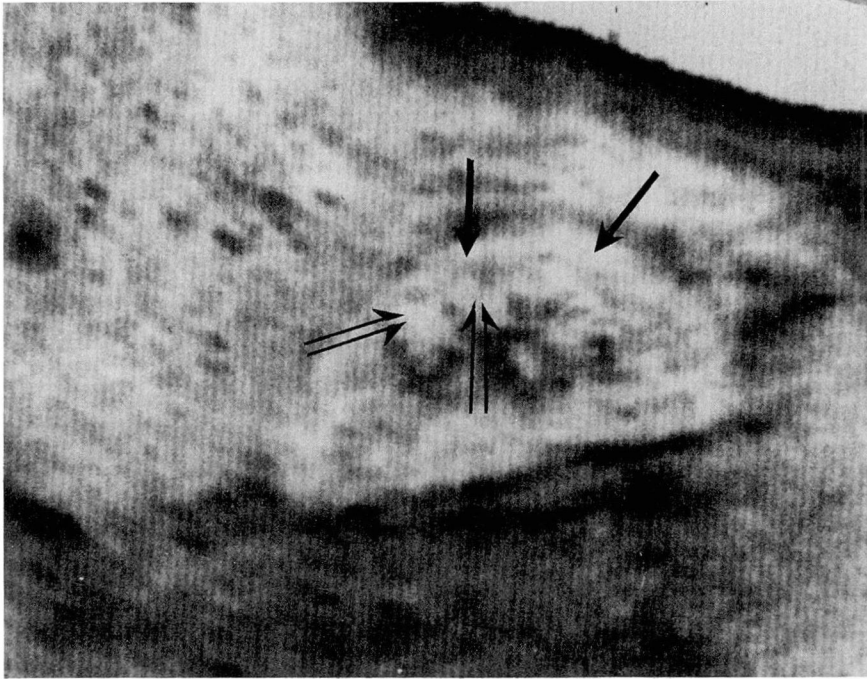


Fig. 2. Ultrasonogram of normal kidney. Note the compartmental anatomy identified by ultrasonography (renal cortex) (single arrows), the clearer medullary pyramids (double arrows), and the dense echoes of the renal hilum. The renal pelvis is collapsed, hence, it is not visualized.

gram demonstrated hydronephrosis of the left collecting system with irregularity of the upper pole calyx. The exact site of obstruction was not evident on these initial films. The right urinary tract was duplex without evidence of obstruction. The left ureteral stent was left in place. Within 12 hours the abdomen was nontender and the urine output increased to 125 cc/hr. After 4 days, her clinical condition was stable and the left ureteral catheter was removed. A pullout ureterogram demonstrated a filling defect of the lower third of the left ureter (*Fig. 1C*). Within 48 hours she became febrile again and it was necessary to reinsert the left ureteral catheter. Again she improved and 4 days later the ureteral catheter was again removed. Again she became febrile and it was necessary to reinsert the ureteral catheter. A ureterotomy was considered to remove the obstructing fragment of tissue, but after the ureteral catheter was removed for the third time, she spontaneously passed a frag-

ment of necrotic tissue on the 14th day after admission. Pathologic examination of the passed specimen showed bacteria-infested renal tissue and the diagnosis of papillary necrosis was confirmed. The patient remained asymptomatic and was discharged on long-term antibiotic therapy.

Discussion

In experienced hands, ultrasound is capable of demonstrating fine anatomic detail of the kidney.⁴ Familiarity with ultrasonic anatomy of the kidney is essential to the understanding of its precise role in identifying obstructive uropathy. In the normal kidney, low intensity echoes reflect from the renal cortex, whereas medullary pyramids are relatively more sonolucent. The arcuate arteries produce punctate, intense echoes at the corticomedullary junction

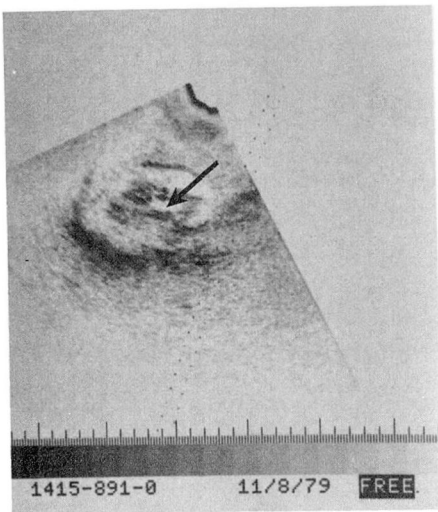
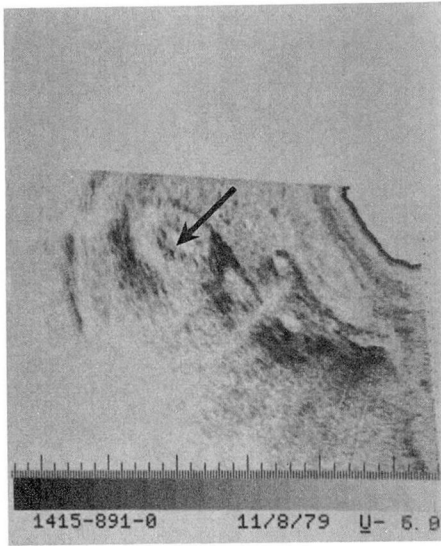


Fig. 3A (top) and B. (bottom) Transverse and longitudinal ultrasonograms of a normal kidney in a patient who was hydrated as part of a pelvic ultrasonic study. Note the dilated renal pelvis as manifested by the clear area of separation of the renal hilar echoes (arrow). This may be easily mistaken for hydronephrosis. Intravenous pyelogram was normal.

and, if visualized, are landmarks for the regional boundary between the cortex and medulla (*Fig. 2*).

Renal calyces and pelves are sonolu-

cent potential spaces lined by echogenic uroepithelium, surrounded by high intensity ultrasonic activity reflecting from renal hilar structures. The renal hilum consists predominantly of fat and vessels. These elements produce intense sonic reflections. The extent of dilatation of the renal pelvis can be gauged by the degree of sonolucency in the central renal hilum. With hydration, the collecting system will expand to produce a nonechogenic central clear area simi-

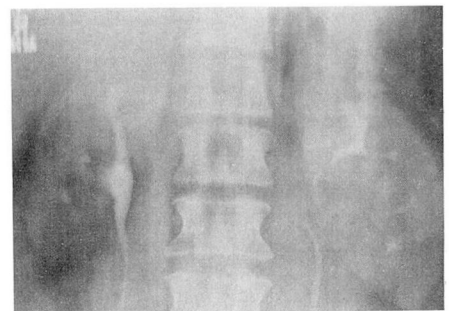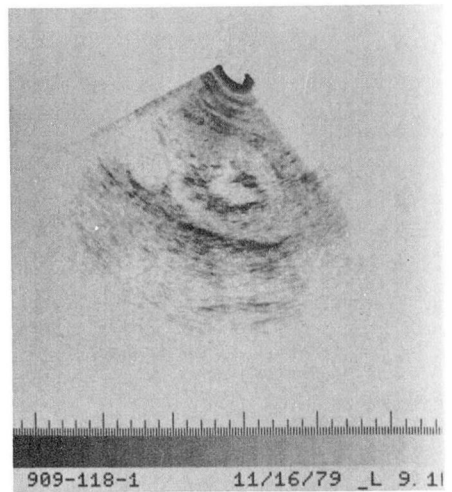


Fig. 4A. (top) Peripelvis renal cyst simulating a dilated pelvis. Note the lucent area of the central kidney and its similarity to a dilated renal pelvis in *Figure 3A. B. (bottom)* Corresponding laminogram of the kidneys during intravenous pyelogram in the same patient demonstrating compression of the renal pelvis by renal cyst. No evidence of urinary tract obstruction.

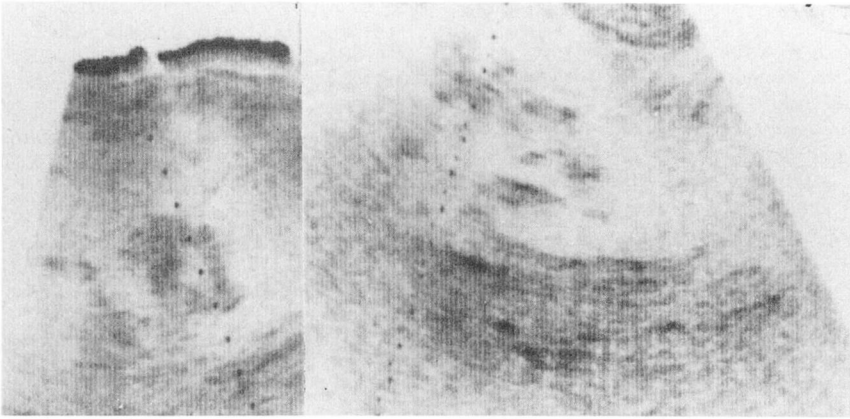


Fig. 5. False-positive example of urinary tract obstruction in a patient with renal vein thrombosis. The renal pelvic dilatation in this case is a normal variant. Retrograde catheterization ruled out urinary tract obstruction.

lar in appearance to a cyst⁵ (Figs. 3 and 4).

The ultrasonic appearance of normal renal collecting systems varies from patient to patient, depending upon the size of the renal pelvis, the state of hydration, and the location of the renal pelvis, whether intrarenal or extrarenal. The ultrasonic finding of a collapsed renal pelvis virtually excludes any possibility of urinary tract obstruction.⁶ Ellenbogen et al⁷ reported that ultrasonography had a sensitivity of 98% in identifying urinary tract obstruction. Only one false-negative study resulted after examination of 47 hydronephrotic patients. In 77 nonobstructed patients examined with ultrasound, 57 of the diagnoses were correct and 20 of the diagnoses of obstruction were incorrect, a false-positive rate of 26%.

The ultrasonic image of the upper urinary tract is a rough, qualitative evaluation of renal pelvic size. A non-specific configuration of dilatation may be produced in various normal physiologic states as well as certain pathologic nonhydronephrotic renal conditions. Severe overhydration with localized de-

struction of the renal calyces secondary to infection or papillary necrosis will produce enlarged sonolucent central renal spaces simulating hydronephrosis when no true obstruction exists.

The low false-negative rate makes ultrasonography an excellent screening procedure to rule out obstruction as a cause of renal failure. Short examination time without the need of contrast media, radiation, or instrumentation make it ideal as a first examination in patients with rising creatinine, sepsis, postoperative oliguria, or in patients with previous reactions to contrast media. If a nondilated pelvis is identified, obstruction may be excluded. However, if a dilated renal pelvis or any other abnormality is identified, additional studies using other modalities are indicated (Fig. 5). In this patient, renal pelvic dilatation and deformity of the superior left renal calyx prompted immediate surgical consultation. Retrograde pyelography and drainage of the left urinary tract resulted in immediate relief of pain and contributed to the rapid improvement of her medical status.

References

1. Green WM, King DL: Diagnostic ultrasound of the urinary tract. *JCU* **4**: 55-64, 1976.
2. Rosenfield AT, Taylor KJW: Gray scale nephrosonography: current status. *J Urol* **117**: 2-6, 1977.
3. Rosenfield AT, Taylor KJW, Crade M, et al: Anatomy and pathology of the kidney by Gray scale ultrasound. *Radiology* **128**: 737-744, 1978.
4. Cook JH III, Rosenfield AT, Taylor KJW: Ultrasonic demonstration of intrarenal anatomy. *AJR* **129**: 831-835, 1977.
5. Morin ME, Baker DA: The influence of hydration and bladder distension on the sonographic diagnosis of hydronephrosis. *JCU* **7**: 192-194, 1979.
6. Sanders RC, Bearman S: B-Scan ultrasound in the diagnosis of hydronephrosis. *Radiology* **108**: 375-382, 1973.
7. Ellenbogen PH, Scheible FW, Talner LB, et al: Sensitivity of Gray scale ultrasound in detecting urinary tract obstruction. *AJR* **130**: 731-733, 1978.