

Primary sarcoma of the pulmonary artery

David N. Fredericka, M.D.

Neil J. Hart, M.D.

Department of Cardiology

Sebastian A. Cook, M.D.

Department of Nuclear Medicine

Edward M. Cordasco, M.D.

Department of Pulmonary Diseases

Primary sarcoma of the pulmonary artery is an extremely rare disorder, usually not considered in the clinical differential diagnosis of cardiopulmonary disease. The manifestations of this malignant disease can mimic the more common conditions that include pulmonary embolism, primary pulmonary hypertension, metastatic pulmonary neoplasms, cardiomyopathy, constrictive pericarditis, and infective endocarditis. The sarcoma can be treated with early operative resection if the correct diagnosis is suspected clinically and confirmed angiographically.

Case report

A 66-year-old white man with congestive heart failure was transferred to the Cleveland Clinic for evaluation of a pulmonary nodule. His main complaint was extreme weakness. Except for obesity, he was in good health until 6 months before admission when gradual dyspnea, generalized weakness, leg swelling, orthopnea, and anorexia developed; he had lost 18 kg (40 pounds).

At his local hospital, a posteroanterior chest roentgenogram showed a coin lesion in the right lower lobe (*Fig. 1*). A second lesion, possibly a granuloma, was seen on a lateral view (*Fig. 2*). Studies for metastatic lung disease, including upper gastrointestinal examination, barium enema, intravenous urogram, liver-spleen scan, bone scan, and computed tomography (CT) of the abdomen were normal. A lung scan, however, showed no perfusion

to the left lung and a defect in the right lung in what appeared to be the anterior segment of the right upper lobe.

On physical examination, his vital signs were normal. He appeared ashen, fatigued, and subdued. Two spider angiomas were visible on his face. Mild jugular venous distension was present when he was in the sitting position. The first and second heart sounds were normal. A grade II/VI holosystolic murmur, which increased with inspiration and handgrip, was heard at the lower left sternal border. Both atrial and ventricular gallops were present. Pulmonary auscultation was normal.

Laboratory data revealed normal electrolytes, blood urea nitrogen (BUN), and creatinine. The automated multiple analysis system (SMA-12) showed a mild decrease in both the albumin and calcium values, with an increased uric acid level of 8.8 mg/dl; alkaline phosphatase, 155 units; and serum glutamic oxaloacetic transaminase (SGOT), 45 units; a normocytic, normochromic anemia with a hemoglobin of 12.3 g/dl, and white blood cell count of 16,900/mm³. The platelet count was normal. Arterial blood gases revealed a pO₂ of 51; pCO₂, 27; and pH, 7.50. The urinalysis showed trace protein, many bacteria, many white blood cells, and no tumor cells. Enterococci grew on the urine culture. Pertinent studies including an RPR, latex, and antinuclear factor were negative.

The electrocardiogram indicated incomplete right bundle branch block. A poster-

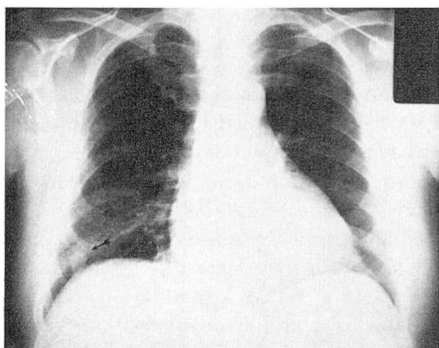


Fig. 1. Roentgenogram showing coin lesion located near right hemidiaphragm (arrow).

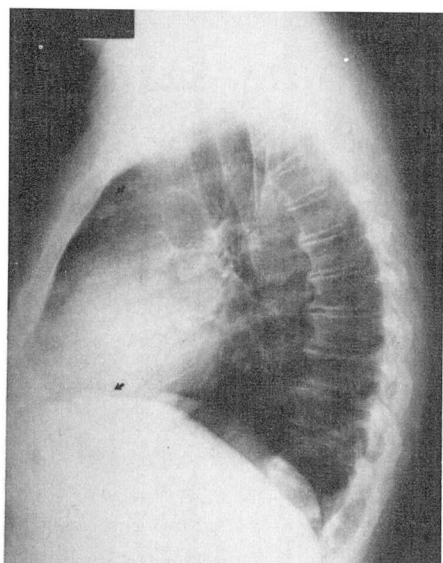


Fig. 2. Coin lesion seen on lateral film with second suspicious lesion in anterior clear space (arrows).

anterior roentgenogram revealed generalized cardiomegaly with clear lung fields except for the nodule in the right base. Echocardiographic analysis showed decreased compliance of the left ventricle, a dilated right ventricle, and a small pericardial effusion. The mitral, aortic, and tricuspid valves appeared normal, but the pulmonic valve was not visualized, which is not unusual in an adult.

During his hospitalization, *Staphylococcus epidermidis* was seen on two blood cultures, but was a possible contaminant. A purified protein derivative of tuberculin (PPD) was positive. Bronchoscopy was nondiagnostic as was an aspiration biopsy of the coin lesion. A repeat lung scan performed approximately 2 weeks after the initial outside scan was unchanged. Bone marrow examination was negative.

After the evaluation, the primary working diagnosis was a cardiomyopathy. The patient was also treated for probable pulmonary emboli and possible bacterial endocarditis with oxygen, digoxin, warfarin sodium (Coumadin), and vancomycin hydrochloride (Vancocin). There was some improvement after one month of hospitalization.

Four weeks later, he was readmitted with

nausea, weakness, dyspnea, and a further weight loss of 11.25 kg (25 pounds). Repeat roentgenograms now showed several pulmonary nodules (Figs. 3 and 4) and a repeat echocardiogram was unchanged. A third lung scan resembled the previous two scans. In addition, the ventilation scan showed good ventilation on the left indicating a ventilation-perfusion mismatch. The patient had a progressively downhill course and died.

At autopsy, an undifferentiated sarcoma was found obstructing 90% of the pulmonary artery trunk and the left main pulmonary artery. The right pulmonary artery was 80% occluded with segmental obstruction of the medium-sized arteries. The sarcoma had metastasized to the pulmonary parenchyma as well as to the diaphragm. Focal infarcts involved all lobes of the lung. The cardiomegaly included right ventricular hypertrophy, dilatation of the right atrium, and a serous pericardial effusion of 100 cc.

Discussion

Although approximately 20% of patients who die of malignancy may have cardiac involvement, it is usually detected clinically in less than 10%.¹ Most commonly, neoplastic heart disease is due to metastases from other sites such as carcinoma of the breast or bronchus. Less common neoplasms include primary types such as the benign atrial myxomas, the most frequently found primary heart tumor, and typically involves the left side of the heart. Malignant primary neoplasms, such as sarcomas, occur most often in the right side of the heart, especially the right atrium.² Sarcoma of the pulmonary artery, an extremely rare condition, should be considered as another neoplastic entity with its own characteristic presentation. This sarcoma of the pulmonary trunk can extend retrogradely to involve the pulmonary cusps and anterogradely in the pulmonary arterial system. Metastases, however, outside the lung are infrequent

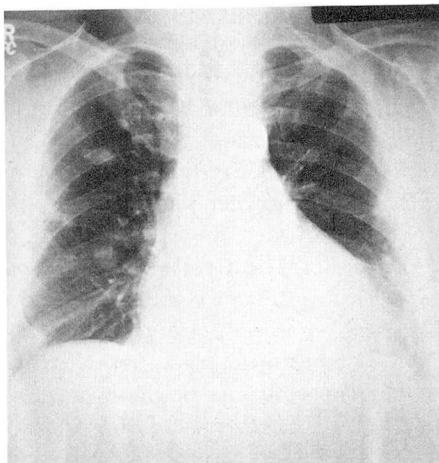


Fig. 3

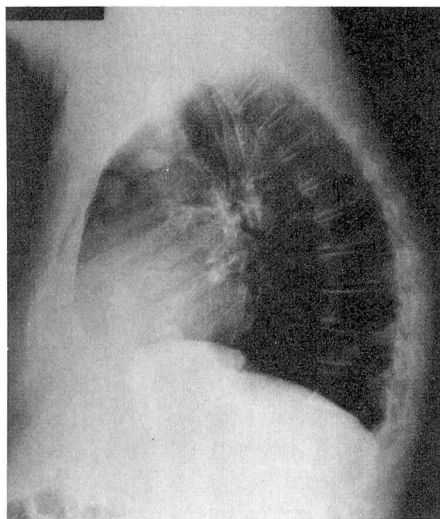


Fig. 4

Figs. 3 and 4 Posteroanterior and lateral films showing multiple nodules.

and hemopericardium is not expected.

According to Ali and Lee³ the first reported case of sarcoma involving the pulmonary artery as a distinct entity was recognized by Mendelstamm in 1923. In 1977, Shmookler et al⁴ reported two cases and reviewed 35 previously reported cases. The most common symptoms included dyspnea, chest pain, cough without hemoptysis, and hemop-

tysis alone. Syncope also occurred in a few patients. The major physical findings were a systolic murmur, cyanosis, subcutaneous edema, weight loss, jugular venous distension, and a basal diastolic murmur. Frequent roentgenographic findings included discrete pulmonary infiltrates, mediastinal or hilar masses or both, cardiomegaly, decreased peripheral pulmonary vascular markings, and enlarged pulmonary arteries. On the electrocardiogram, right ventricular hypertrophy can be present. If angiography is performed, filling defects in the pulmonary artery are seen, and elevated right ventricular pressures may be found. Pulmonary hypertension can occur secondary to tumor emboli.

Sarcoma of the pulmonary artery most commonly manifests itself clinically by producing signs and symptoms caused by decreased pulmonary perfusion and right ventricular systolic hypertension with subsequent hypertrophy, dilatation, and failure. The systolic ejection murmurs described in these patients may be produced by supra-valvular or valvular pulmonary outflow tract obstruction. Diastolic murmurs can result from partial summation of the atrial and ventricular gallops with a rapid rate. Tricuspid regurgitation, which can occur with increased right ventricular systolic pressure, was heard in our patient. The inspiratory increase in the intensity of the murmur of tricuspid regurgitation is called Carvallo's sign, but it may be absent if advanced right ventricular failure is present.

Since pulmonary thromboembolism can be easily mistaken for tumors of the pulmonary arteries, serial lung scans can be helpful in differentiating between the two.⁵ Typically, the scintigraphic perfusion defects associated with thromboembolic phenomena show a changing

pattern over a short period of time,⁶ whereas those associated with pulmonary artery sarcoma remain rather fixed. If the defects remain fixed, then angiography should be performed to substantiate that diagnosis. Although the most common cause for ventilation-perfusion mismatch is thromboembolism, at least 15 other conditions can also give the same mismatch.⁷ Therefore, when the perfusion lung scan remains fixed over a period of time, even though there may be a ventilation-perfusion mismatch, it should be suspected that the findings are not related to pulmonary emboli. Angiography can confirm the diagnosis of a tumor and appropriate therapy can be undertaken. DiGilio et al⁸ have reported that a resection can be performed successfully.

References

1. Hurst JW, Cooper HR: Neoplastic disease of the heart. *Am Heart J* **50**: 782-802, 1955.
2. Somers K, Lothe F: Primary lymphosarcoma of the heart; review of the literature and report of 3 cases. *Cancer* **13**: 449-457, 1960.
3. Ali MY, Lee GS: Sarcoma of the pulmonary artery. *Cancer* **17**: 1220-1224, 1974.
4. Shmookler BM, Marsh HB, Roberts WC: Primary sarcoma of the pulmonary trunk and/or right or left main pulmonary artery—a rare cause of obstruction to right ventricular outflow; report on two patients and analysis of 35 previously described patients. *Am J Med* **63**: 263-272, 1977.
5. Olsson HE, Spitzer RM, Erston WF: Primary and secondary pulmonary artery neoplasia mimicking acute pulmonary embolism. *Radiology* **118**: 49-53, 1976.
6. Tow DE, Wagner HN Jr: Recovery of pulmonary arterial blood flow in patients with pulmonary embolism. *N Engl J Med* **276**: 1053-1059, 1967.
7. Li DK, Seltzer SE, McNeil BJ: \dot{V}/\dot{Q} mismatches unassociated with pulmonary embolism; case report and review of the literature. *J Nucl Med* **19**: 1331-1333, 1978.
8. DiGilio MM, Lee HJ, Tatoes CJ, et al: Myxosarcoma of the pulmonary valve. *Chest* **62**: 639-642, 1972.