

Pitfalls in interpretation of the pulmonary valve echogram in patients with congenital heart disease

Douglas S. Moodie, M.D.

Department of Cardiology

Echocardiographic assessment of the pulmonary valve is important in patients with congenital heart disease as well as in patients with elevated pulmonary artery pressures. With the use of the pulmonary valve echogram, criteria have been defined for pulmonary hypertension¹⁻³ and correlates have been derived estimating pulmonary artery pressure and pulmonary resistance in these patients.⁴⁻⁷ Pulmonary valve motion has also been described in various congenital cardiac defects including pulmonary stenosis⁸⁻¹⁰ and transposition.¹⁰⁻¹⁶

We describe some potential sources of error in interpretation of the pulmonary valve echogram in a patient with congenital cardiac defects and we question the current criteria and correlations in patients with pulmonary hypertension.

Normal pulmonary valve

The technique for detecting the pulmonary valve echocardiographically has been defined.^{1, 3, 10, 15} The aortic root is identified by directing the transducer medially and superiorly from the mitral valve. From this position, the ultrasonic beam is then angled superiorly and laterally toward the left shoulder. As the signals from aortic walls disappear, an anterior sonolucent space, which represents the right ventricular outflow-pulmonary root junction,

becomes visible. Within this space, the pulmonary cusp echoes appear as thin moving lines. Posteriorly, the pulmonary artery is separated from the left atrium by a thick echo complex produced by structures in the atrial pulmonary sulcus.^{1,15} In some patients it is helpful first to locate this thick echo complex, and then by minimal angulation to delineate the pulmonary cusp echoes. In most instances, only the posterior pulmonary cusp can be visualized (*Fig. 1*). Correlation with anatomic specimens indicates that the posteriorly located leaflet image is derived from the left pulmonary cusp. The components of the pulmonary valve echogram (posterior leaflet) are seen in *Figure 1*. The *a* wave follows the P wave on the electrocardiogram. From point *b*, which represents the position of the valve at the onset of ventricular ejection, the leaflet rapidly moves to a fully open position

(point *c*). During systole, there is a gradual anterior movement of the leaflet (*c-d*) followed by rapid diastolic closure of the valve (*d-e*). During diastole, the leaflet moves gradually posteriorly to a point that precedes the onset of atrial systole.

The pulmonary valve echo can be used to record right ventricular systolic time intervals. The right ventricular pre-ejection period (RVPEP) is the time from the onset of the QRS complex on the electrocardiogram to the opening of the pulmonary valve (*Fig. 2*). The right ventricular ejection time (RVET) is the time from the opening of the pulmonary valve to pulmonary valve closure as defined on the echo (*Fig. 2*). Hirschfeld et al² and Riggs et al⁷ have recorded the pre-ejection period right ventricular ejection time ratio, RVPEP/RVET, in normals. This ratio does not appear to be influenced by age and heart rate.

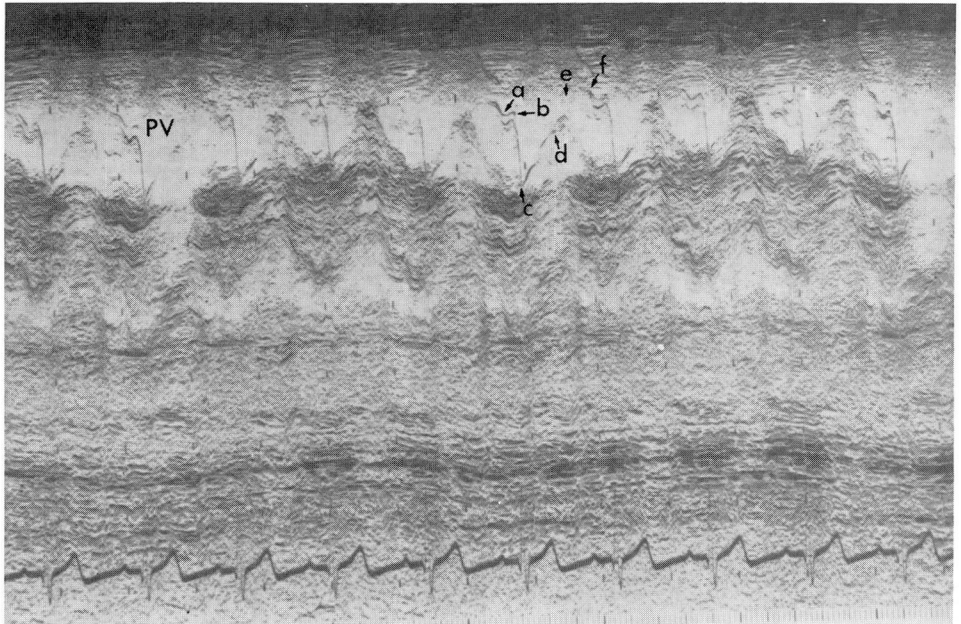


Fig. 1. Pulmonary valve leaflet: *a* = point following the P wave on the ECG, *b* = position of the leaflet at the onset of ventricular ejection, *b-c* = rapid systolic opening of the leaflet, *c-d* = leaflet in the open position during systole, *d-e* = diastolic closure, *e-f* = leaflet in the closed position during diastole. RVPEP/RVET ratio = 0.28.

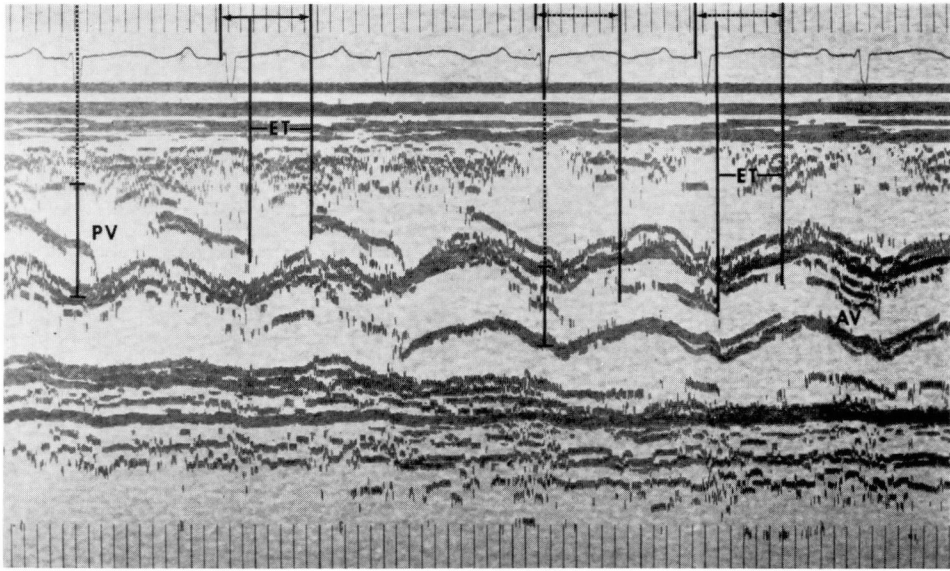


Fig. 2. Pulmonary and aortic valve echograms demonstrating their use for the determination of ejection times. The pre-ejection period is noted by the arrow from the time of the onset of the QRS complex on the electrocardiogram to the opening of the semilunar valve. The ejection time (ET) is the time from the opening of the valve to its closure. PV = pulmonary valve, AV = aortic valve.

Riggs et al⁷ have shown in newborn infants that the mean ratio declines from 0.39 to 0.28 from one hour to 72 hours of life. Hirschfeld et al,² in a somewhat older population, defined the normal ratio as 0.24 with a range of 0.16 to 0.30.

Patterns of pulmonary valve motion with pulmonary hypertension

The echocardiographic criteria for pulmonary hypertension have been described¹⁻³ as (1) loss of the "a" dip, (2) early midsystolic closure, (3) mid-systolic fluttering, (4) a decreased e-f slope, and (5) rapid opening of the pulmonary valve leaflet. It has been stated that with any significant degree of pulmonary hypertension the a wave will be absent^{1,6} or that an "a" dip may be present, but that it is less than 2 mm in depth.² Hirschfeld et al² found a close correlation between the RVPEP/RVET ratio and pulmonary artery diastolic pressure

and pulmonary vascular resistance. In their study, if the RVPEP/RVET ratio was greater than 0.40, the pulmonary vascular resistance was always greater than 5 units. If the ratio was less than 0.30, the pulmonary resistance was almost always less than 3 units and the pulmonary artery diastolic pressure was less than 25. A close correlation was not found between mean pulmonary artery pressure and the above-mentioned systolic time intervals. More recent studies by Riggs et al^{5,6} have basically confirmed these findings.

Figure 3 demonstrates an echo from a patient with pulmonary hypertension and right ventricular failure. The "a" dip is prominent (arrows) and measures 2 to 4 mm. Figure 4 demonstrates early systolic closure and mid-systolic fluttering in a 10-year-old boy with pulmonary hypertension and a ventricular septal defect. The third pulmonary valve complex appears to have an "a" dip and the

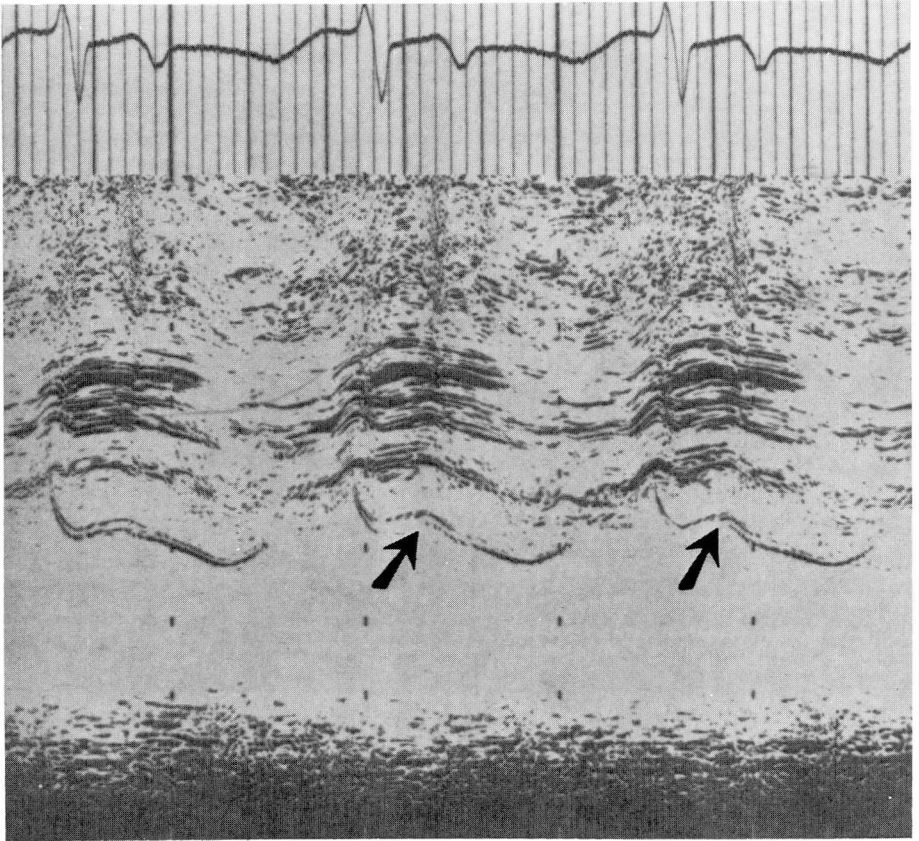


Fig. 3. Pulmonary valve echogram in a 5-year-old boy with situs inversus, atrial ventricular concordance, ventricular septal defect, patent ductus arteriosus, and dextrotransposition of the great arteries. Pulmonary artery pressure was 129/82; right ventricular pressure, 124/2-7; pulmonary resistance, 31.5 units; pulmonary arteriolar resistance, 29.5 units; RVPEP/RVET ratio, 0.50. An "a" dip is definitely present (2 to 3 mm). Early systolic closure and mid-systolic fluttering are noted. The e-f slope is decreased and there is rapid opening of the valve.

e-f slope is not decreased. *Figure 5* demonstrates a markedly diminished e-f slope in a patient with transposition of the great vessels who did not have pulmonary hypertension. Thus, we have not found the absence of an "a" dip, or rapid opening velocity to be consistent findings in patients with pulmonary hypertension.

One recent report⁶ has explained the "a" dip on the pulmonary valve as possibly reflecting the relative pressure existing across the pulmonary valve at the time of atrial systole. It was felt that an

absent or greatly dampened *a* wave would result in patients with pulmonary hypertension because the pulmonary artery end-diastolic pressure is usually well above the simultaneous right ventricular end-diastolic pressure. Weyman et al,⁸ however, have described marked variation in the "a" dip with normal respiration. In normal subjects, deep inspiratory "a" dips in which the pulmonary valve opens from a partially opened or domed position have been described.⁸ The phenomenon occurs especially in the presence of a short P-R

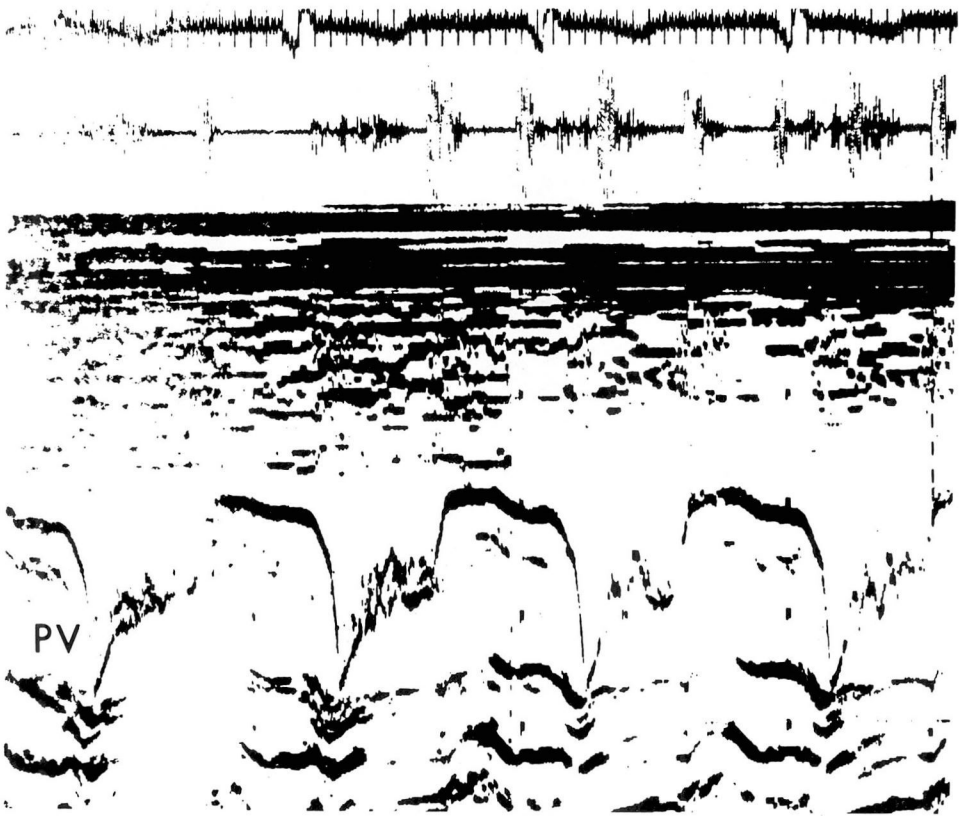


Fig. 4. Pulmonary valve echogram in a 10-year-old boy with pulmonary vascular disease and pulmonary hypertension secondary to a large ventricular septal defect (pulmonary artery pressure, 92.50; right ventricular pressures, 88/2-12; pulmonary resistance, 11.2 units; RVPEP/RVET ratio, 0.30). Note the marked mid-systolic fluttering and early closure of the valve. The third complex appears to have an "a" dip. The opening slope is greater than 350 mm/sec. The e-f slope is not significantly decreased.

interval. Thus, the variation in size and configuration of the "a" dip in patients with congenital heart disease also reflects normal inspiratory variation. In addition, in some instances the "a" dip of the pulmonary valve may not be due to the effects of atrial contraction on the valve, but to movement of the vessel wall (pulmonary artery) as can be clearly seen in those cases where the aorta displays an "a" dip (*Fig. 6*). Because of the difficulty in visualizing the pulmonary artery, especially the anterior wall, the movements of this vessel wall might not be seen. In a patient with pulmonary hypertension who does

have marked vessel wall movement, an "a" dip, even a normal appearing one (3 to 4 mm), might be seen.

That the "a" dip may, however, reflect pressure across the pulmonary valve at the time of atrial systole is seen in many patients with pulmonary hypertension who do not have demonstrable "a" dips and in those patients with complete heart block who have an "a" dip simultaneously with atrial contraction (*Fig. 7*).

In our patients who have pulmonary hypertension, the RVPEP/RVET ratio has been greater than 0.30 (*Table*). In those patients with normal pulmonary




Fig. 5. Pulmonary valve echogram of a 6-year-old boy following the Mustard procedure for transposition of the great vessels. Note markedly diminished e-f slope. There is early closure of the pulmonary valve. Pulmonary artery pressure was 25/20.



Fig. 6. Aortic root echogram demonstrating prominent posterior deflection of the aortic valve simulating an "a" dip simultaneous with marked vessel wall motion. AO = aorta, AV = aortic valve.

artery pressures, the ratio has generally been between 0.20 and 0.28 (*Table*). In the presence of pulmonary hypertension, the ratio is greater than 0.30, even when the pulmonary vascular resistance

is low and we have not seen a good correlation between RVPEP/RVET ratios and pulmonary artery resistance (*Table*). Thus, an RVPEP/RVET ratio of greater than 0.30 is seen in patients



Fig. 7. Pulmonary valve echogram in a patient with complete heart block. An "a" dip is noted following atrial contraction. The line points from the onset of the P wave to the beginning of the "a" dip. PV = pulmonary valve.

with pulmonary hypertension, but cannot be used to predict pulmonary vascular disease.

The pulmonary valve motion is distinctive in patients with pulmonary hypertension and the pulmonary valve echogram can help the clinician determine if pulmonary artery pressures are elevated. We suggest that the echocardiographic criteria for pulmonary hypertension be revised; namely, the pulmonary valve echogram shows evidence of elevated pulmonary artery pressure when there is (1) mid-systolic fluttering, and (2) early systolic closure of the valve with an RVPEP/RVET ratio greater than 0.30.

Even in those patients who have an RVPEP/RVET ratio greater than 0.30, mid-systolic fluttering, and early systolic closure of the valve, the pulmonary artery pressure may be only marginally elevated. We have recently seen an infant with a patent ductus arteriosus who had a postoperative echogram demonstrating elevated pulmonary artery pressure and mildly elevated pressures measured at operation (Fig. 8).

The pulmonary valve in pulmonary stenosis

Pulmonary valve motion has been previously described in patients with pulmonary stenosis.^{8,9} In patients with mild gradients no real abnormality was noted.¹²⁻¹⁹ The apparent thickness of the valve leaflet is no help in defining the presence of stenosis as we have seen what appears to be thickened valves in normal patients. It has been reported²⁰ that in patients with pulmonary valvular gradients from 50 to 142 mm Hg, the pulmonary valve echogram demonstrates a markedly increased (8 to 13 mm) "a" dip in that the pulmonary valve leaflets never return to a baseline or closed position before ventricular systole.

We have seen a marked "a" dip in a patient with a mild gradient (17 mm) after a pulmonary valvotomy (Fig. 9). As mentioned, we have seen marked "a" dips on the aortic valve simultaneously with marked vessel wall motion in diastole in patients who did not have aortic stenosis. Thus, the increased "a" dip of

Table. Relationship of right ventricular systolic time intervals to pulmonary artery pressure and pulmonary resistance

Patient	Age	Diagnosis	PA press	RV press	RP	RVPEP/ RVET
1	46 yr	Pulm hypertension	99/41	98/7-13	35.3 (RpA 30.2)	0.30
2	1 mo	Coarct, VSD, PDA	80/42	83/7-12		0.57
3	15 yr	Situs inversus, concordant vents, VSD, PDA, d-TGA	129/82	124/2-7	31.5 (RpA 29.5)	0.50
4	13 yr	ASD, VSD	120/67	113/1-12	26.0	0.33
5	5 yr	Pulm hypertension	137/84	126/1-7	21.4 (RpA 26.1)	0.65
6	15 yr	VSD	129/71	130/7-17	44.0 (RpA 39.0)	0.47
7	11 days	PS (60 to 70 mm)	19/11	95/2-10	0.9	0.40
8	15 yr	Normal	41/13	32/0-10	3.2 (RpA 0.2)	0.20
9	6 yr	PS (22 mm)	20/6	45/1-7	2.1	0.20
10	18 mo	VSD	72/27	62/6-10	8.4	0.38
11	15 yr	PAVC, PS, VSD, secundum ASD	35/13	92/3-18	2.7	0.20
12	1 yr	C veni (C), ASD	76/5	73/4-11	5.4	0.33
13	24 yr	Postop mustard, TI	22/8	24/2-5	(RpA 0.7)	0.28
14	11 yr	Postop mustard	97/66	97/8-13	(RpA 13.9)	0.46
15	18 mo	CAVC	83/55	82/7-12	4.8	0.37
16	10 yr	Postop mustard, PS, TI	32/22	76/6-12	(RpA 2.7)	0.21
17	7 yr	CAVC	55/20	69/1-15	4.8	0.44
18	7 yr	CAVC	49/23	47/7-17	6.2 (RpA 1.4)	0.33
19	39 yr	PS (25 mm)	15/7	39/1-6	4.2 (RpA 2.1)	0.21
20	8 mo	PS (50 mm)	17/12	61/5-9	3.7	0.23
21	15 yr	IHSS, PS	17/9	82/3-11	3.0	0.20
22	13.5 mo	VSD	48/13	50/1-5	1.5 (RpA 0.9)	
23	8 yr	C. atrium, anomalous venous return	62/24	62/2-8	3.6 (RpA 3.0)	0.33
24	6 yr	PS (22 mm)	45/1-7	20/6	2.1	0.22
25	10 yr	VSD	92/50	88/2-12	11.2	0.30
26	10 mo	VSD	57/20	55/4-8	2.4	0.33
27	4 yr	VSD, post-PA banding and PDS repair, hypoplasia of aortic arch	92/38	100/11-12	6.5 (RpA 0.9)	0.38
28	14 mo	PDA	93/58	93.0-8	20	0.40
29	16 mo	Pulm hypertension, mild	45/25	45/0-9	10	0.60
30	1 yr	Subpulmonic VSD	38/15	38/0-8	4	0.30

PA press = pulmonary artery pressure, RV press = right ventricle pressure, RP = total pulmonary resistance, pulm = pulmonary, RpA = pulmonary arteriolar resistance, Coarct = coarctation, VSD = ventricular septal defect, PDA = patent ductus arteriosus, vents = ventricles, d-TGA = dextrotransposition of the great arteries, ASD = atrial septal defect, PS = pulmonary stenosis, PAVC = partial atrioventricular canal, C vent (C) = common ventricle, postop = postoperative, TI = tricuspid insufficiency, CAVC = complete atrioventricular canal, IHSS = idiopathic hypertrophic subaortic stenosis.

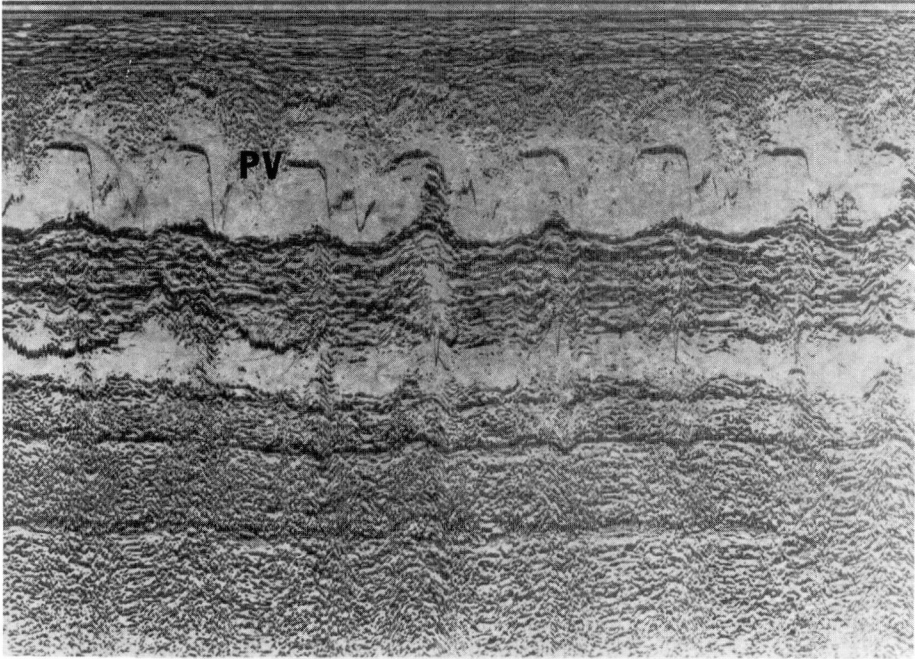


Fig. 8. Pulmonary valve echogram in a 14-month-old boy following surgical ligation of a patent ductus arteriosus. Pulmonary artery pressure before operation had been at a systemic level of 93/58. Pulmonary artery pressure was measured at operation at a level of 55 with a systemic level of 100. There is mid-systolic fluttering, early closure, and a RVPEP/RVET of 0.36. PV = pulmonary valve.

the pulmonary valve might be caused by vessel wall motion as well as by the effect of right atrial contraction when there is elevated right ventricular end-diastolic pressure and normal pulmonary artery pressure.

Chaotic fluttering of one leaflet of the pulmonary valve has been described in patients with infundibular pulmonary stenosis. We have noted chaotic fluttering of both leaflets of the pulmonary valve in patients with dextrotransposition of the great vessels and infundibular pulmonary stenosis. There has been a recent report of pulmonary valve fluttering and subpulmonic ventricular septal defect and we have also noted a similar case (*Fig. 10*).⁹

Thus, the pulmonary valve echogram

does not help the clinician distinguish mild pulmonary stenosis from a normal pulmonary valve echogram, but it does allow him to distinguish echocardiographically between mild and severe pulmonary stenosis based on the appearance of the "a" dip. If a patient has had a pulmonary valvotomy, the "a" dip may be increased even though there may be no significant valvular gradient. The echocardiogram is also helpful in differentiating valvular from subvalvular pulmonary stenosis. We have demonstrated chaotic fluttering of two pulmonary valve leaflets in subvalvular pulmonary stenosis, in addition to the fluttering of one leaflet previously described.⁹ We also agree with one recent report that a subpulmonic ventricular




Fig. 9. Pulmonary valve echogram in a 15-year-old boy with idiopathic hypertrophic subaortic stenosis and a 17-mm gradient across the pulmonary valve, after pulmonary valvotomy (54 to 17 mm gradient). Note the greatly increased "a" dip (15 mm). The opening of the valve appears normal. RVPEP/RVET ratio = 0.20. PV = pulmonary valve.

septal defect may cause pulmonary valve fluttering identical to that seen in infundibular pulmonary stenosis.¹⁹

Pulmonary valve postpulmonary artery banding

The effect of pulmonary artery banding on the pulmonary valve echogram has been reported. *Figure 11* demonstrates what we have found consistently in patients with pulmonary artery banding, namely, a greatly increased "a" dip and mid-systolic fluttering of the valve. These echoes could be misinterpreted as demonstrating severe valvular pulmonary stenosis; however, we have not seen mid-systolic flutter of the valve leaflets in valvular pulmonary stenosis. Perhaps this systolic fluttering reflects turbulence across the valve when the pressure distal to it is elevated. We have not demonstrated early systolic closure of the valve in these patients.

Pulmonary valve in complete transposition of the great vessels

The identification of the semilunar valves is particularly important in patients with transposition of the great vessels.^{4, 10, 12, 13-16} A posterior great vessel is located by transducer angulation superiorly and slightly leftward; the posterior wall of this great vessel is noted with base-to-apex scan to be in continuity with the anterior leaflet of the posterior atrioventricular (mitral) valve. An anterior great vessel is located by transducer angulation superiorly and to the patient's right; this great vessel lacks echo continuity with either the anterior or posterior atrioventricular valve.

A normal newborn has a relatively large right ventricular cavity and the outside diameter of the pulmonary artery (1 to 1.5 cm) is slightly larger than the outside end-diastolic diameter of the

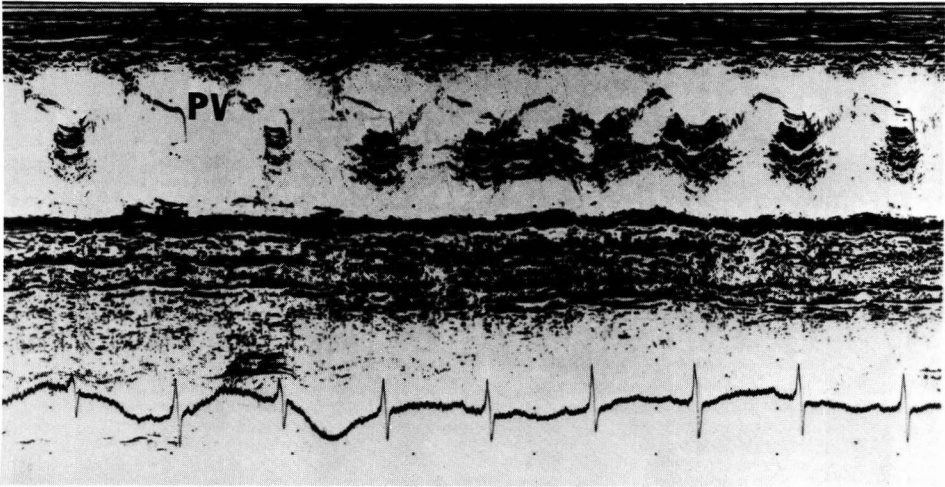


Fig. 10. Pulmonary valve echogram in a one-year-old white girl with a subpulmonic ventricular septal defect. Pulmonary artery pressure, 38/15; right ventricular pressure, 38/0-8; pulmonary resistance, 4 units. $RVPEP/RVET = 0.3$. There is coarse systolic fluttering of the valve. PV = pulmonary valve.




Fig. 11. Pulmonary valve echogram in a patient with complete arteriovenous canal after pulmonary artery banding. There is a greatly increased "a" dip with systolic fluttering of the valve. Pulmonary artery pressure distal to the band was normal. PV = pulmonary valve.

aorta (0.8 to 1.3 cm).^{2, 6} In normal newborn infants and adults, a pulmonary vascular resistance lower than systemic resistance may allow the pulmonary valve to close later than the aortic valve. Relating the echocardiographic semilunar valve closure to the onset of the QRS complex of the electrocardiogram

may allow echocardiographic identification of the semilunar valve.

When pulmonary vascular resistance is lower than systemic resistance, the QRS-to-closure interval of the posterior pulmonary valve may be longer than the anterior aortic valve. If this determination can be made, the examiner

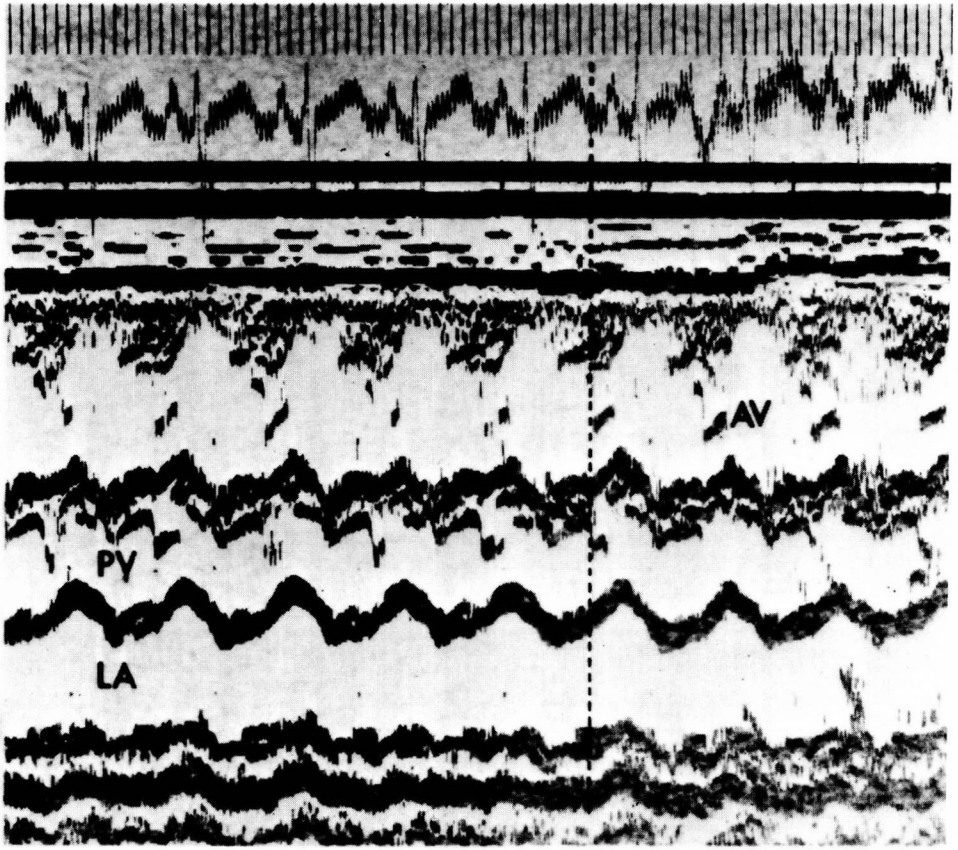


Fig. 12. Echogram of a term neonate with dextrotransposition of the great arteries. Closure times are identical. AV = aortic valve, PV = pulmonary valve, LA = left atrium, RVPEP/RVET ratio = 0.34.

can feel certain the patient has transposition. If the pulmonary vascular resistance is elevated, the QRS-to-closure intervals may be equal (Fig. 12). Both semilunar valves are often visualized simultaneously in the same scan in normal newborns, small infants, and patients with complete transposition of the great vessels.

Comment

We have reviewed the current literature on the pulmonary valve echogram to define pulmonary hypertension. We have redefined the echocardiographic

criteria for pulmonary hypertension based on the most consistent echocardiographic findings. We disagree with authors who recently suggested that the pulmonary valve echogram can be used to assess pulmonary vascular disease, since we do not think the pulmonary valve echogram or right ventricular systolic time intervals can be used to assess pulmonary vascular resistance.

We have shown the pitfalls in the interpretation of the pulmonary valve echogram in patients with pulmonary stenosis. The echocardiographic findings in patients after pulmonary valvo-

tomy and pulmonary artery banding can be misinterpreted to indicate severe pulmonary stenosis. In addition, echocardiographically, pulmonary infundibular stenosis can be confused with subpulmonary ventricular septal defect. We have reviewed the echocardiographic pitfalls encountered in assessing the pulmonary valve in patients with transposition of the great vessels.

Echocardiography of the pulmonary valve and the calculation of right ventricular systolic time intervals can be helpful in assessing congenital heart disease, but one must look critically at the noninvasive information in light of the clinical presentation of the patient.

Acknowledgment

I thank Ernesto Salcedo, M.D. and Gail Goldblatt for their assistance with *Figures 1 and 3*. I also thank Abigail Brogden, R. T. for her constructive criticisms and review of the manuscript.

References

1. Nanda NC, Gramiack R, Robinson TI, et al: Echocardiographic evaluation of pulmonary hypertension. *Circulation* **50**:575-581, 1974.
2. Hirschfeld S, Meyer R, Schwartz DC, et al: The echocardiographic assessment of pulmonary artery pressure and pulmonary vascular resistance. *Circulation* **52**:642-650, 1975.
3. Weyman AE, Dillon LC, Feigenbaum H, et al: Echocardiographic patterns of pulmonic valve motion with pulmonary hypertension. *Circulation* **50**:905-910, 1974.
4. Halliday H, Hirschfeld S, Riggs T, et al: Respiratory distress syndrome; echocardiographic assessment of cardiovascular function and pulmonary vascular resistance. *Pediatrics* **60**:444-449, 1977.
5. Riggs T, Hirschfeld S, Bormuth C, et al: Neonatal circulatory changes; an echocardiographic study. *Pediatrics* **59**:338-344, 1977.
6. Riggs T, Hirschfeld S, Fanaroff A, et al: Persistence of fetal circulation syndrome; an echocardiographic study. *J Pediatr* **91**:626-631, 1977.
7. Riggs T, Hirschfeld S, Borkat G, et al: Assessment of the pulmonary vascular bed by echocardiographic right ventricular systolic time intervals. *Circulation* **57**:939-947, 1978.
8. Weyman AE, Dillon JC, Feigenbaum H, et al: Echocardiographic patterns of pulmonary valve motion in valvular pulmonary stenosis. *Am J Cardiol* **34**:644-657, 1974.
9. Weyman AE, Dillon JC, Feigenbaum H, et al: Echocardiographic differentiation of infundibular from valvular pulmonary stenosis. *Am J Cardiol* **36**:21-26, 1975.
10. Solinger R, Elbl F, Minhas K: Echocardiography; its role in severely ill infants. *Pediatrics* **57**:543-563, 1976.
11. Godman NJ, Tham P, Langhord Kidd BS: Echocardiography in the evaluation of the cyanotic newborn infant. *Br Heart J* **36**:154-166, 1974.
12. Solinger R, Elbl F, Minhas K: Deductive echocardiographic analysis in infants with congenital heart disease. *Circulation* **50**:1072-1096, 1974.
13. Hagler DJ: The utilization of echocardiography in the differential diagnosis of cyanosis in the neonate. *Mayo Clin Proc* **51**:143-154, 1976.
14. Goldberg SJ, Allen HD, Sahn DJ: Pediatric and adolescent echocardiography. Chicago, Yearbook Medical Publishers, 1975.
15. Sahn DJ, Allen HD, Goldberg SJ, et al: Pediatric echocardiography; a review of its clinical utility. *J Pediatr* **87**:335-352, 1975.
16. Murphy KF, Kotler MN, Reichek N, et al: Ultrasound in the diagnosis of congenital heart disease. *Am Heart J* **89**:638-656, 1975.
17. Weyman AE: Pulmonary valve echo motion in clinical practice. *Am J Med* **62**:843-855, 1977.
18. Kerber PC, Maximov M: Determinants of pulmonic valve opening velocity; experimental echocardiographic studies. *Circulation* **54**: (Suppl II):II-61, 1976.
19. Glasser SP, Baucum RW Jr: Pulmonary valve fluttering in subpulmonic ventricular septal defect. *Am Heart J* **94**:3-5, 1977.