

# Monitoring arrhythmias and signs of intraoperative ischemia by electrocardiogram

Roger Dean White, M.D.

*Rochester, Minnesota*

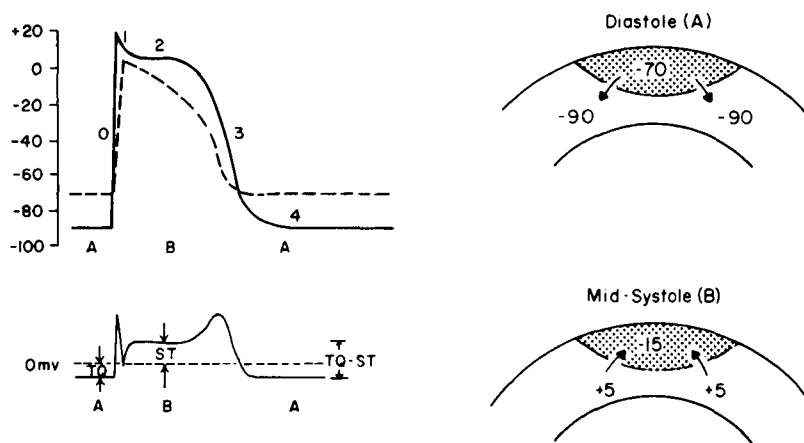
Electrocardiographic monitoring serves two critical roles during anesthesia and operation in patients with coronary artery disease. It is a qualitative source of information regarding myocardial oxygen supply/demand relationships by means of changes in the ST segment, and it is the means by which arrhythmias of any etiology can be immediately recognized and treated if necessary. Although ST-segment deviations are commonly appreciated to be accompaniments of acute myocardial ischemia or injury, it is not so commonly understood that arrhythmias also may be manifestations of acute ischemia, injury, or infarction. In the coronary care unit ventricular arrhythmias are well known to be expressions of underlying electrical instability invoked and sustained by myocardial ischemia or infarction. Thus the cardiac anesthesiologist must be aware that intraoperative myocardial ischemia, injury, or infarction may become evident by deviations in the ST segment in the appropriate lead or by the acute onset of ventricular ectopy,<sup>1</sup> or by both signs of underlying electrical changes precipitated by acute ischemia. The purpose of this paper is to review the current understanding of the electrophysiologic mechanisms involved in the evolution of ST-segment deviations and ischemia-induced ventricular arrhythmias. The emphasis will be on

electrophysiologic concepts rather than on recognition and treatment of the disorders themselves. This may provide the clinical cardiac anesthesiologist with further insight into mechanisms that generate the observed electrocardiographic abnormalities.

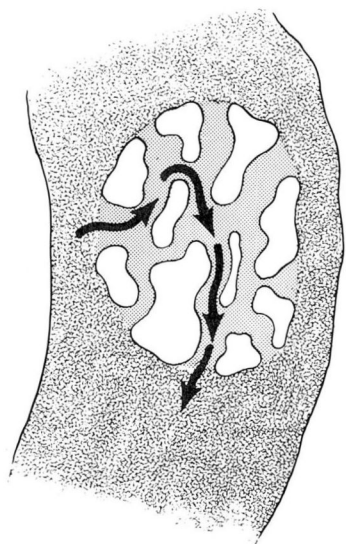
### Electrophysiologic events underlying ST-segment displacements

During acute myocardial ischemia the transmembrane potential of ischemic cells is altered as compared with normal cells.<sup>2-5</sup> During diastole (phase 4 of the action potential) acutely ischemic cells have a lower (less negative) resting transmembrane potential than normal cells. For example, although surrounding normal cells have membrane potentials at rest of  $-85$  to  $-95$  mV, ischemic cell potentials may be reduced to  $-60$  to  $-75$  mV. As a result of this

difference in potential or voltage, current flows from the ischemic to the normal tissue (*Fig. 1*). During systole (phases 2 and 3) the transmembrane potentials of ischemic cells become negative earlier than do those of the surrounding normal cells, because of either incomplete depolarization or early repolarization or both. Now the voltage gradient at the boundary between normal and ischemic tissue is reversed and current flows in the opposite direction. The flow of current during diastole causes the T-Q segment to be depressed in leads overlying the ischemic area. (The T-Q segment is from the end of the preceding T wave to the beginning of the next QRS complex.) During systole the flow of current is reversed and the ST segment in the same leads is elevated. Thus the event usually referred to as ST-segment elevation is bet-



**Fig. 1.** (Top left) Transmembrane potentials of ischemic (broken curve) and normal (solid curve) tissue. Numbers indicate phases 0 to 4. Phase 0 = initial rapid upstroke; phase 1 = phase of early rapid repolarization; phase 2 = plateau phase of slow repolarization; phase 3 = terminal phase of rapid repolarization; phase 4 = diastolic period. (Bottom left) Electrocardiogram recorded by an electrode overlying the ischemic tissue. The T-Q segment is located below the isoelectric line (broken) and the ST segment above. (Top right) Potential gradients existing at the boundary between normal ( $-90$  mV) and ischemic ( $-70$  mV) tissue during electrical diastole. (Bottom right) Potential gradients existing at the boundary between normal ( $+5$  mV) and ischemic ( $-15$  mV) tissue at mid-systole. Arrows indicate the direction of current flow (positive to negative) at the boundary. (Reprinted with permission from Holland RP, Brooks H. TQ-ST segment mapping; critical review and analysis of current concepts. *Am J Cardiol* 1977; 40: 110-29.)



**Fig. 2.** Schematic depiction of conduction through an ischemic/infarcted intramural zone of ventricular muscle. The white areas are islands of inexcitable, severely depressed tissue. The dotted areas within the ischemic zone are still excitable, though also depressed, and conduct the wave front at reduced conduction velocities. The ischemic zone is surrounded by normal muscle indicated by the wavy lines. The wave front propagates through the depressed area at reduced conduction velocity but is able to sustain itself and emerge to reenter surrounding normal myocardium. This represents a form of reentrant excitation.

ter understood as *the sum of T-Q depression and ST elevation*.<sup>2</sup> The TQ-ST segment deflection (a more electrophysiologically correct term than ST-segment deflection) is generated by the differences in potential and the subsequent flow of current arising at the boundary between normal and ischemic tissues.

There is substantial though not conclusive evidence that the reduction in transmembrane potential in cells in ischemic areas is brought about by the release of intracellular potassium ( $K^+$ ) from ischemic cells into the surrounding extracellular fluid.<sup>2,4</sup> Such a loss of intracellular  $K^+$  into the surrounding ex-

tracellular space will result in a lowering of resting membrane potential and reduction of action potential duration, the conditions that permit current to flow during systole and diastole and thus the inscription of the TQ-ST segment deflection.

### **Electrophysiologic alterations in ischemia causing ventricular arrhythmias**

As already discussed, acutely ischemic cells are partially depolarized (resting transmembrane potential less negative than normal). Depolarized areas are characterized by partial or even complete inactivation of the current normally responsible for phase O depolarization of cells in the His-Purkinje system and in ventricular muscle. Such inactivation, partial or complete, is associated with a reduction in conduction velocity and a tendency to unidirectional block of an advancing wave front. These are the prerequisite electrophysiologic conditions for reentrant excitation, which is probably the primary mechanism for ventricular ectopic activity during acute ischemia.<sup>5</sup> In this circumstance the wave front may enter an area acutely depressed by ischemia and encounter conduction block.<sup>6</sup> By a return route it can reenter and therefore reexcite normal tissue and cause ventricular ectopy if there is sufficient slowing of its conduction velocity in the ischemic area to permit recovery of excitability of surrounding normal tissue. A form of such reentrant excitation is shown in *Figure 2*. In this illustration the advancing wave front, e.g., from the sinus node, is able to enter the area of ischemia/infarction at one edge of the border zone. There is sufficient depression of conduction velocity in the ischemic zone to permit the wave front to engage recovered and thus excitable tissue upon its emergence from

the region of acute ischemia and infarction.<sup>6</sup> This reentering wave front can now propagate itself and be the cause of an ectopic depolarization. If this mechanism is sustained via such a reentrant pathway, ventricular tachycardia would result. Fractionation of the emerging wave front into multiple daughter "wavelets" could cause enough desynchronization of electrical activity to produce ventricular fibrillation.

Another possible source of ectopic discharge and therefore arrhythmias in acutely ischemic hearts is the flow of current between ischemic and normal zones.<sup>7</sup> The basis for such flow was already discussed (*Fig. 1*). Whenever there are significant differences in potential between adjacent areas of the myocardium, current can flow and therefore bring about ectopic depolarization. Acutely ischemic areas are characterized by the presence of cells with reduced membrane potential (*Fig. 1*). The flow of current from such areas into excitable areas with higher resting potential may generate ectopic depolarizations. In addition the duration of the action potential in acutely ischemic cells is shortened relative to that in normal cells so that there are differences in the rates of recovery of excitability.<sup>8</sup> This difference in recovery time is shown in the depiction of the normal and ischemic action potentials in *Figure 1*. Depolarizing current (boundary current) can flow from the normal to the ischemic zone because of these differences in action potential duration and therefore permit the propagation of reentrant wave fronts. The slow conduction velocity in the ischemic zone facilitates reentrant excitation by this mechanism, since it delays the impulse in the ischemic zone and therefore permits entry of the wave front into surrounding tissue that has regained its excitability.<sup>9</sup> This

form of reentrant activity is known as focal reexcitation.<sup>8</sup> It is evident that the electrical derangements brought about by acute ischemia can become manifest clinically not only as ST-segment changes but also as ventricular arrhythmias. Acute alterations in the electrophysiologic properties of ischemic cells, most importantly reduction in resting membrane potential and shortening of action potential duration, can bring about both types of electrocardiographic manifestations of underlying acute myocardial ischemia.

### Clinical correlates of these electrophysiologic events

Electrocardiographic monitoring permits rapid recognition and treatment of ischemia-induced TQ-ST segment deviations or ventricular ectopic activity or both. TQ-ST segment changes typically correlate with the anatomic location of the ischemia and can easily be missed if only one lead is used for monitoring. Ideally a left precordial lead, such as V<sub>5</sub>, and a limb lead such as lead II or III, are used.<sup>10</sup> A left precordial lead serves best to detect ischemic changes in the distribution of the left coronary artery, especially its left anterior descending branch, whereas II or III is more likely to detect inferior wall ischemia in the distribution of the right coronary artery.

Ventricular ectopy is not so lead-dependent for diagnosis, though sometimes changing leads is helpful in more precise delineation of the arrhythmia, e.g., in attempting to differentiate the origin of a wide-complex QRS tachycardia.

### Summary

Acute myocardial ischemia occurring intraoperatively is typically identified by displacement of the ST segment of

the electrocardiogram in the lead appropriate for the anatomic region to ischemia. Acute ischemia, however, can also give rise to ventricular ectopic activity, which can degenerate into lethal arrhythmias if not promptly recognized and treated. It is helpful for the cardiac anesthesiologist to be acquainted with current thinking on the electrophysiologic mechanisms that underlie both ST-segment displacements and ventricular ectopic activity when acute ischemia is the provocation. It is evident that both ST-segment deviations and ventricular ectopic activity can be caused by ischemia-induced changes in the electrophysiologic properties of affected cells, primarily reductions in membrane potential and in action potential duration. The common denominator in both forms of electrical abnormalities (ST changes and arrhythmias) may be the release of potassium from acutely ischemic cells.

## References

1. White RD. Drugs in cardiac supportive care. *Anesth Analg* 1976; **55**: 633-9.
2. Holland RP, Brooks H. TQ-ST segment mapping; critical review and analysis of current concepts. *Am J Cardiol* 1977; **40**: 110-29.
3. Ross J Jr. Electrocardiographic ST-segment analysis in the characterization of myocardial ischemia and infarction. *Circulation* 1976; **53** (suppl 1): I-73-I-81.
4. Johnson EA. First electrocardiographic sign of myocardial ischemia; an electrophysiologic conjecture. *Circulation* 1976; **53** (suppl 1): I-82-I-84.
5. Downar E, Janse MJ, Durrer D. The effect of acute coronary artery occlusion on subepicardial transmembrane potentials in the intact porcine heart. *Circulation* 1977; **56**: 217-24.
6. Wit AL, Bigger JT Jr. Possible electrophysiological mechanisms for lethal arrhythmias accompanying myocardial ischemia and infarction. *Circulation* 1975; **51** and **52** (suppl 3): 96-115.
7. Han J: The concepts of reentrant activity responsible for ectopic rhythms. *Am J Cardiol* 1971; **28**: 253-67.
8. Corr PB, Sobel BE: The importance of metabolites in the genesis of ventricular dysrhythmia induced by ischemia. I. Electrophysiological considerations. *Mod Concepts Cardiovasc Dis* 1979; **48**: 43-7.
9. Kupersmith J: Electrophysiological and antiarrhythmic effects of lidocaine in canine acute myocardial ischemia. *Am Heart J* 1979; **97**: 360-6.
10. Kaplan JA, Dunbar RW, Hatcher CR: Diagnostic value of the V<sub>5</sub> precordial electrocardiographic lead; a case report. *Anesth Analg* 1978; **57**: 364-7.