

Spectrum of M-mode echocardiographic findings in total anomalous pulmonary venous return

Douglas S. Moodie, M.D.

Department of Cardiology

The echocardiographic criteria suggestive of total anomalous pulmonary venous return (TAPVR) have been described as (1) findings of right ventricular volume overload (paradoxical septal motion and a dilated right ventricle) and (2) an echo-free space dorsal to the left atrium.¹⁻⁵ The classic echocardiographic criteria, however, have been challenged by recent reports as nonspecific and of limited usefulness in the infant group.^{2, 3, 6} As some infants with TAPVR are minimally cyanotic and have signs of right ventricular volume overload and congestive failure, others are critically ill at birth with pulmonary venous obstruction, severe cyanosis, and pulmonary edema, we believed it was important to describe the spectrum of M-mode echocardiographic findings related to the age and size of the patient, the source of the total anomalous pulmonary venous drainage, the pulmonary artery pressures, and the measurements of right- and left-sided cardiac chamber dimensions. We describe nine pediatric patients with TAPVR: six were beyond the newborn period with anomalous drainage above the diaphragm, and three were critically ill with TAPVR below the diaphragm in the newborn period. These nine cases demonstrate the spectrum of the echocardiographic findings present in this condition.

Patients and methods

The *Table* describes the various clinical aspects in our patients. There were nine patients, five females and four males in the age range of 20 hours to 12 years (mean, 2.5 years). Five patients were 2 years old or older and three were neonates. The sites of the TAPVR are listed in the *Table*. The site of the anomalous drainage was determined by angiography, and in some cases was confirmed at postmortem examination. Six patients, primarily in the older age group, had total anomalous drainage above the diaphragm. In four of the six, there was total pulmonary venous drainage to a left vertical vein. In one patient there was drainage to the right atrium, and in another to the coronary sinus. The three newborn infants had TAPVR to the liver or the hepatic portal system. Pulmonary artery pressures were recorded preoperatively via cardiac catheterization and are listed in the *Table*. Left ventricular systolic and end-diastolic dimensions, right ventricular end-diastolic dimensions, aortic dimensions measured in diastole, as well as left atrial dimensions measured in atrial systole were recorded as recommended by the American Society of Echocardiography.⁷ Echocardiographic measure-

ments of the right ventricle in diastole, the left ventricle in both systole and diastole, the aortic root in diastole, and the left atrium in systole were plotted according to the criteria described by Henry et al.⁸

Results

All six patients with TAPVR above the diaphragm demonstrated paradoxical septal motion (*Fig. 1*). Right ventricular end-diastolic dimensions were increased in all nine patients (*Figs. 1 and 2A*). Left ventricular end-systolic and end-diastolic diameters were in the normal or low-normal range in most patients, although in patient 6 both left ventricular measurements were below normal (*Fig. 2B and C*). Aortic root measurements were within the normal range (*Fig. 3A*). Left atrial measurements were either in the low-normal range or the atria were small (*Fig. 3B*). Two of the three patients in whom the left atrium was abnormally small had TAPVR below the diaphragm. *Figure 4A* (patient 1) shows a scan from the mitral valve to the aorta suggestive that the left atrium is abnormally small. However, when the left atrium is more clearly visualized (*Fig. 4B*) the left atrial dimension is normal. *Figure 5A* (patient 7) again demonstrates

Table. Clinical description of pediatric patients with TAPVR

Patient no.	Sex/age	Square surface area m ²	Site of total anomalous venous return	Pulmonary artery pressure mm Hg
1	M 4 mo	0.26	To coronary sinus	47/123
2	M 2 yr	0.50	To right atrium	33/17
3	F 23 mo	0.49	To left vertical vein	32/17
4	F 4 yr	0.52	To left vertical vein	42/16
5	F 12 yr	0.90	To left vertical vein	40/20
6	F 2 yr	0.45	To left vertical vein	46/11
7	M 1 day	0.24	To caudate lobe of liver	83 systolic
8	F 20 hr	0.18	To hepatic portal system	75/35
9	M 5 days	0.23	To the liver	95 systolic

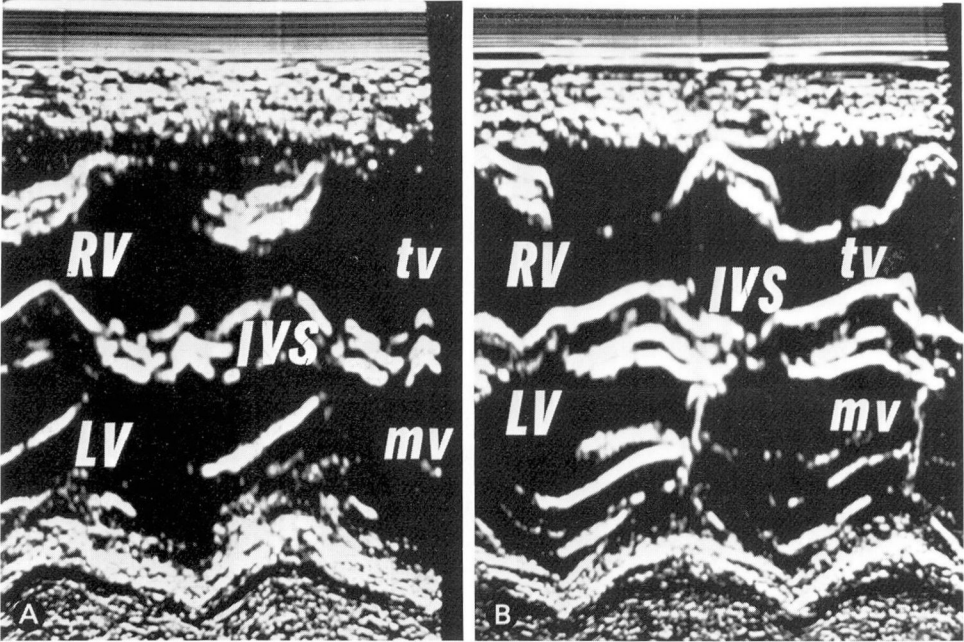


Fig. 1A. M-mode echocardiogram in patient 3 at the level of the left ventricular posterior wall demonstrating a dilated right ventricle with paradoxical septal motion in that the septum moves parallel to the left ventricular wall instead of toward the wall during systole. RV = right ventricle, LV = left ventricle, tv = tricuspid valve, mv = mitral valve, IVS = interventricular septum. B. M-mode echocardiogram in patient 5 demonstrating paradoxical septal motion as described in Figure 1A. The right ventricle is again noted to be dilated.

ECHOCARDIOGRAPHIC MEASUREMENT IN PATIENTS WITH TOTAL ANOMALOUS VENOUS RETURN

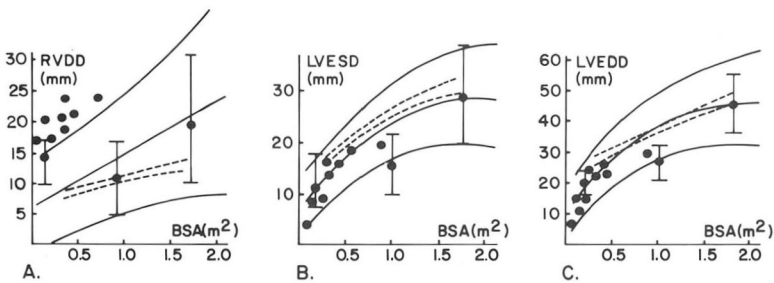


Fig. 2A. Right ventricular end-diastolic dimensions measured in millimeters compared to the actual square surface area of the patient. The results indicated enlarged right ventricular diastolic dimensions in all patients. B. Left ventricular end-systolic dimensions (LVESD) compared to the square surface area of the patient demonstrating normal to low-normal values. C. Left ventricular end-diastolic dimensions (LVEDD) again showing the values to be primarily in the normal range except for one patient who has an abnormally small left ventricle. The graphs are adapted from the normal values reported by Rogé et al.⁸

ECHOCARDIOGRAPHIC MEASUREMENT IN PATIENTS WITH TOTAL ANOMALOUS VENOUS RETURN

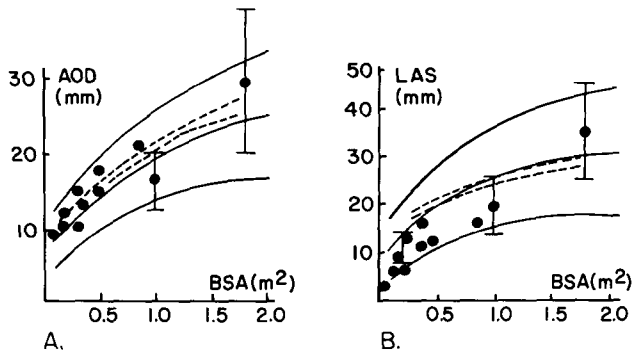


Fig. 3A. Aortic root end-diastolic measurements compared to the square surface area of the patient demonstrated a normal aortic root measurement in all patients. **B.** Left atrial systolic measurements compared to the actual square surface area of the patient demonstrated low-normal values in most patients with two patients who had a small left atrium.

a scan from the mitral valve to the aorta and left atrium, and again the scan is suggestive of an abnormally small left atrium. On better visualization of the left atrium and aorta (*Fig. 5B*), the left atrium is small compared to the aorta, and this left atrial measurement was the smallest of the group. The patient had TAPVR below the diaphragm. However, not all patients with TAPVR below the diaphragm had abnormally small left atrial measurements, either on mitral-aortic scan or on visualization of the left atrium and aorta. This is demonstrated in *Figure 6A and B* (patient 9).

In two patients studied we were able to visualize the common pulmonary venous chamber posterior to the left atrium. Patient 1 had TAPVR to the coronary sinus. The other patient had TAPVR to a left vertical vein, but the common pulmonary venous chamber (CPVC) was easily visualized (*Fig. 7*). Contrast echocardiography was not performed in any of the patients.

In three patients, right ventricular systolic time intervals were measured (*Fig. 8*). The RVPEP/RVET ratio was

recorded in all three newborn infants with TAPVR below the diaphragm, with values that ranged from 0.4 to 0.65 suggestive of significant pulmonary hypertension.⁹

Discussion

In our patients with TAPVR above the diaphragm, the echocardiographic findings were those of right ventricular volume overload, namely a dilated right ventricular chamber with paradoxical septal motion. Five of these six patients with classic right ventricular volume overload were 2 years old or older. The one younger patient had TAPVR to the coronary sinus. All of our patients had only slightly elevated pulmonary artery pressures and none in this group had pulmonary venous obstruction. Thus, our findings would agree with those of Paquet and Gutgesell¹ that in the older patient the echocardiogram suggests a volume-overloaded right side of the heart with a left-to-right shunt. In addition, we were able to visualize the common pulmonary venous chamber posterior to the aorta in two of our

patients: a 4-month-old infant with TAPVR to the coronary sinus, and a 23-month-old infant with TAPVR to a left vertical vein. Left ventricular end-

systolic and end-diastolic dimensions were normal to low normal in all patients. Aortic root dimensions were normal. Left atrial dimensions were low

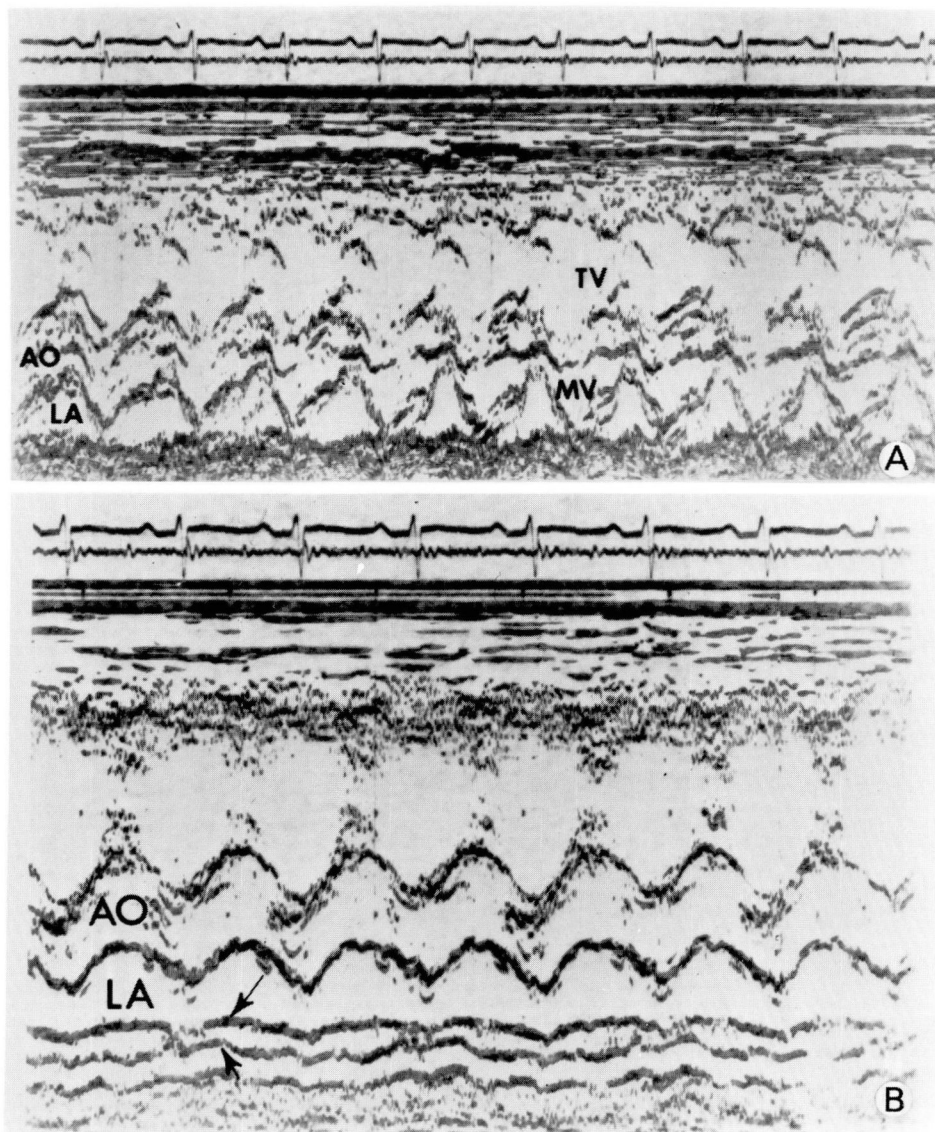


Fig. 4A. M-mode echocardiogram demonstrating a scan from the mitral valve to the aorta, again showing the marked enlargement of the right ventricle with compression of the mitral valve and left ventricle. On scan to the aorta, the left atrium appears small. AO = aorta, LA = left atrium, and other abbreviations as in *Figure 1*. **B.** M-mode echocardiogram showing normal left atrial and aortic dimensions. Arrows point to a linear structure posterior to the left atrium, which is the common pulmonary venous chamber that drained to the coronary sinus.

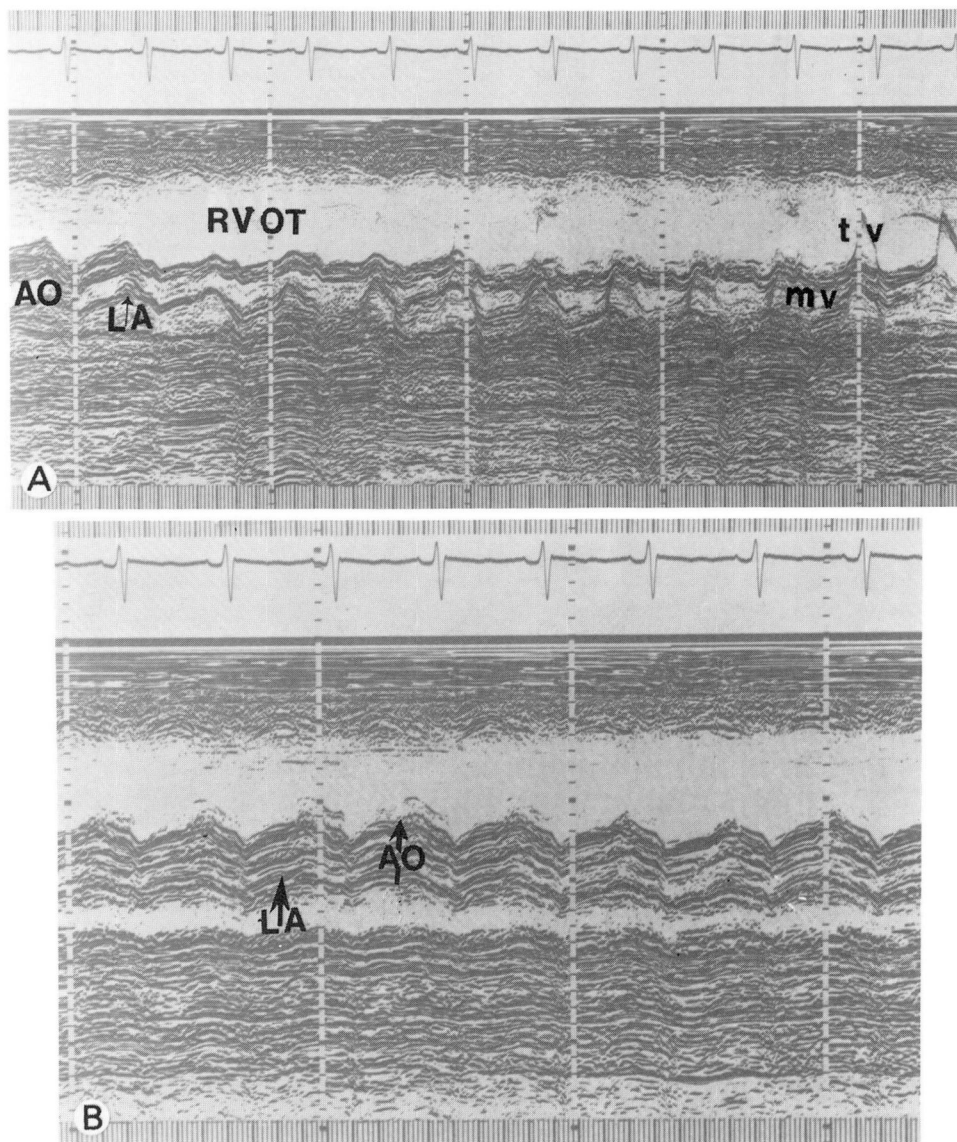


Fig. 5A. M-mode echocardiogram in patient 8 demonstrating the markedly dilated right-sided heart chambers with compression of the mitral valve, the left ventricle, and left atrium. RVOT = right ventricular outflow tract, and other abbreviations as in above *Figures*. **B.** Left atrial aortic root dimensions demonstrating a small atrium.

normal or small in all these patients.

Echocardiographic findings in the newborn infants with TAPVR were different from those in the older age group.

All three neonates had TAPVR below the diaphragm to the hepatic portal system. All these patients had normal septal motion. All had dilated right ven-

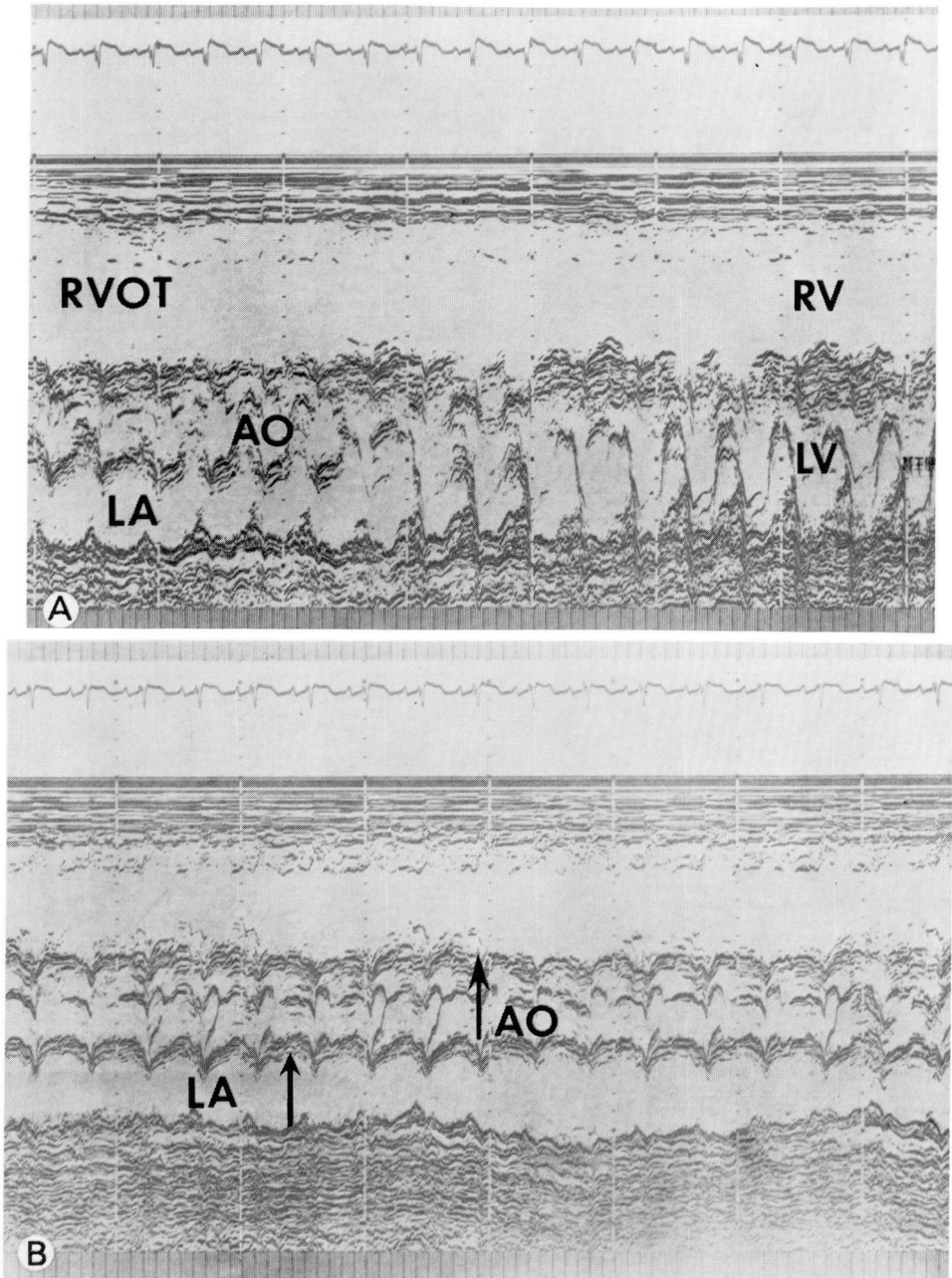


Fig. 6A. M-mode echocardiographic scan in patient 9 who had TAPVR below the diaphragm to the hepatic portal system. The right ventricle and right ventricular outflow tract are markedly dilated. The left atrium does not appear hypoplastic. Abbreviations as in above *Figures*. **B.** Left atrial aortic root M-mode echocardiogram in patient 9 showing a normal left atrium and aortic root diameter.

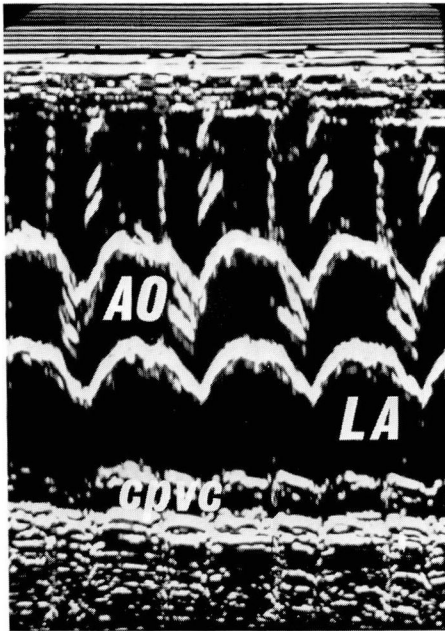


Fig. 7. Left atrial aortic root M-mode echocardiogram in patient 3 who had TAPVR to a left vertical vein. The left atrium is of normal size. The common pulmonary venous chamber (cpvc) can be seen posterior to the left atrium. Abbreviations as in above *Figures*.

tricles with echocardiographic evidence of pulmonary hypertension, in that the RVPEP/RVET ratio was markedly greater than 0.30. Pulmonary artery pressures recorded at catheterization were systemic or supersystemic and the pressures were twice those in the group with TAPVR above the diaphragm. Left ventricular end-systolic and end-diastolic dimensions were low normal in two of the three patients, and below normal in one patient. Aortic root dimensions were normal in all three patients. Left atrial dimensions were below normal in two of the three patients. Echocardiographic findings had to be interpreted with care in scanning from the mitral valve to the aorta; the left atrium could appear small (*Fig. 4A*).

However, with good definition of the anterior and posterior aortic wall, the left atrium could then be recorded more clearly and could appear more normal in size (*Fig. 4B*). In one of the infants (patient 9) (*Fig. 6A and B*), the left atrium aortic root ratio was normal, and there was no echocardiographic evidence of small left atrium or left ventricle even though that patient had the highest pulmonary artery pressures and severe pulmonary venous obstruction. It becomes clear in reviewing the echocardiograms that the left heart in patients with TAPVR, particularly with pulmonary venous obstruction below the diaphragm, is somewhat compressed and flattened by the markedly dilated right ventricle and right ventricular outflow tract (*Fig. 5A*). We agree with data of others¹⁰⁻¹³ that the left atrium in most patients with TAPVR echocardiographically appears to be of adequate size and would not likely be a limiting factor for operative success. In two instances in which the left atrium appeared smaller than normal, the left ventricular dimensions in systole and diastole were still in the low-normal range. Therefore, the left atrium may function as a mere conduit for left ventricular filling in this condition.

We also agree with others that in the newborn it is extremely difficult to use M-mode echocardiography alone to ascertain TAPVR below the diaphragm. Signs of right ventricular volume overload are lacking and the M-mode echocardiogram consists primarily of the findings of pulmonary hypertension with a dilated and hypertrophied right ventricle. We were not able to define an unusual echo posterior to the left atrium in our newborn infants.^{3,6} The echocardiographic findings in the newborn with TAPVR and our recent experience would suggest that the M-mode echo-

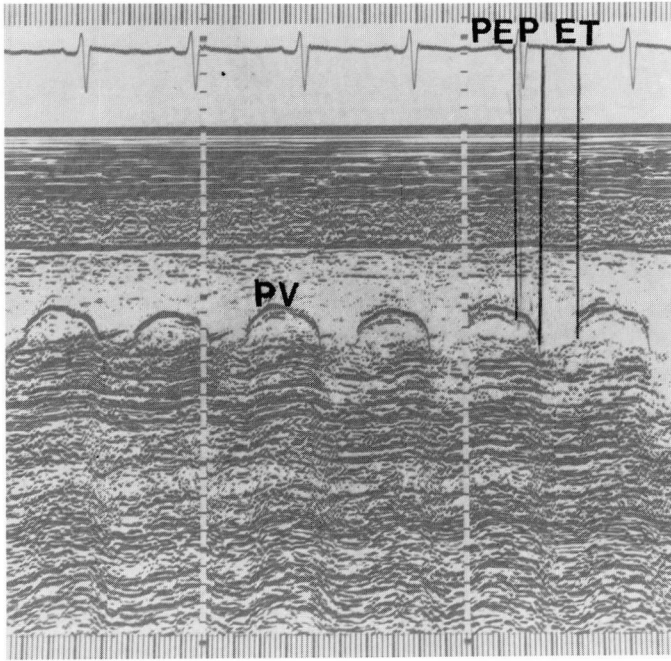


Fig. 8. Pulmonary valve echocardiogram in patient 8. The RVPEP/RVET ratio equals 0.70, suggestive of severe pulmonary hypertension. Normal RVPEP/RVET ratio = 0.30.

cardiogram is of limited use in the newborn with TAPVR below the diaphragm, and may easily lead to confusion when trying to differentiate this condition from persistent fetal circulation, since both conditions manifest echocardiographic findings of pulmonary hypertension.¹⁴ If the left atrium is small, one still cannot be conclusive about the diagnosis of TAPVR because in patients with persistent fetal circulation, the pulmonary venous flow may be reduced secondarily to severe pulmonary arteriolar vasoconstriction. Thus, the investigator must reassess the patient, since the echocardiographic findings do not appear specific in the newborn. Perhaps the two-dimensional echocardiogram will be more specific in the differential diagnosis of TAPVR in the newborn as recently reported by Sahn et al.¹⁵

Summary

The results of our study, which is the largest reported M-mode echocardiographic study in pediatric patients with TAPVR, demonstrate that the M-mode echocardiographic findings mirror the varied clinical spectrum of this disease. In the older patients who are acyanotic and have a left-to-right shunt, the echocardiographic findings are those of a right ventricular volume overload. In the newborn group, particularly in those with pulmonary venous obstruction with TAPVR below the diaphragm, the echocardiographic signs are those of pulmonary hypertension with a dilated right heart, and one may note a small-appearing left atrium. TAPVR will remain a challenge in the newborn. The M-mode echocardiographic findings are not specific in this

particular lesion. Perhaps newer techniques of echocardiographic imaging with the use of two-dimensional echocardiography will improve our diagnostic capabilities.¹⁵

References

1. Paquet M, Gutgesell H. Echocardiographic features of total anomalous pulmonary venous connection. *Circulation* 1975; **51**: 599-605.
2. Sassé L. Echo recordings in TAPVC. *Circulation* 1975; **52**: 527-8.
3. Sassé L. Interpreting the echocardiogram in TAPVC. *Circulation* 1976; **53**: 1041-2.
4. Orsmond GS, Ruttenberg HD, Bessinger FB, Moller JH. Echocardiographic features of total anomalous pulmonary venous connection to the coronary sinus. *Am J Cardiol* 1978; **41**: 597-601.
5. Aziz KU, Paul MH, Bharati S, Lev M, Shannon K. Echocardiographic features of total anomalous pulmonary venous drainage into the coronary sinus. *Am J Cardiol* 1978; **42**: 108-13.
6. Godman MJ, Tham P, Kidd BSL. Echocardiography in the evaluation of the cyanotic newborn infant. *Br Heart J* 1974; **36**: 154-66.
7. Sahn DJ, DeMaria A, Kisslo J, Weyman A. Recommendations regarding quantitation in M-mode echocardiography; results of a survey of echocardiographic measurements. *Circulation* 1978; **58**: 1072-83.
8. Rogé CLL, Silverman NH, Hart PA, Ray RM. Cardiac structure growth pattern determined by echocardiography. *Circulation* 1978; **57**: 285-90.
9. Hirshfield S, Meyer R, Schwartz DC, Korfhagen J, Kaplan S. The echocardiographic assessment of pulmonary artery pressure and pulmonary vascular resistance. *Circulation* 1975; **52**: 642-50.
10. Gersony WM, Bowman FO Jr, Steeg CN, Hayes CJ, Jesse MJ, Malm JR. Management of total anomalous pulmonary venous drainage in early infancy. *Circulation* 1971; **43** (suppl 1): 19-24.
11. Wukasch DC, Deutsch M, Reul GJ, Hallman GL, Cooley DA. Total anomalous pulmonary venous return; review of 125 patients treated surgically. *Ann Thorac Surg* 1975; **19**: 622-33.
12. Dillard DH, Mohri H, Hessel EA II, et al. Correction of total anomalous pulmonary venous drainage in infancy utilizing deep hypothermia with total circulatory arrest. *Circulation* 1967; **35 and 36** (suppl 1): 105-10.
13. Castaneda AR, Lamberti J, Sade RM, Williams RG, Nadas AS. Open-heart surgery during the first three months of life. *J Thorac Cardiovasc Surg* 1974; **68**: 719-31.
14. Fyfe D, Moodie DS, Gill CC. Persistent fetal circulation complicating total anomalous pulmonary venous return in the neonate. *Pediatrics*. In press.
15. Sahn DJ, Allen HD, Lange LW, Goldberg SJ. Cross-sectional echocardiographic diagnosis of the sites of total anomalous pulmonary venous drainage. *Circulation* 1974; **60**: 1317-24.