

Phase imaging: a new, noninvasive method for diagnosis, localization of accessory pathways, and serial assessment of therapy in patients with Wolff-Parkinson-White syndrome

A preliminary report

John Yiannikas, M.D.
Robert J. Eastway, D.O.

Department of Cardiology

William J. MacIntyre, Ph.D.

Department of Nuclear Medicine

James D. Maloney, M.D.

Department of Cardiology

Raymundo T. Go, M.D.
Sebastian A. Cook, M.D.
Bruno Sufka, B.S.

Department of Nuclear Medicine

Lon W. Castle, M.D.

Department of Cardiology

Myocardial activation patterns have been elegantly delineated by Durrer et al¹ who showed that ventricular activation, although not completely homogeneous, occurs earliest in the middle third of the left interventricular septum and latest in the basal regions of both ventricles and septum. Similarly, patterns of epicardial activation in patients with ventricular preexcitation with an accessory atrioventricular pathway of the Kent bundle type have been delineated in recent years in an attempt to localize these pathways. Wolff-Parkinson-White syndrome assumes its importance clinically because of the frequently associated paroxysms of tachycardia. Because of the now well-established role of surgical division of accessory atrioventricular pathways, precise localization of these pathways has become mandatory. However, localization of accessory atrioventricular pathways has been achieved utilizing very complex, time-consuming invasive preoperative and intraoperative electrophysiologic studies.

Fourier phase analysis of ^{99m}Tc-gated equilibrium radionuclide scans theoretically provides an opportunity to characterize patterns of myocardial movement by accurately demonstrating the timing of contraction between small segments of the myocardium. Fourier phase and amplitude analysis of

technetium cardiac scans has been shown to be an accurate method of assessing regional wall motion² and quantitating areas of dyskinesia in patients with left ventricular aneurysms.³ However, abnormalities of movement may also result from alterations in myocardial activation. Although the movement of the blood pool is a complex process involving many factors, the patterns of delayed electrical activation seen in left bundle branch block have been accurately assessed by Fourier phase analysis of ^{99m}Tc blood-pool scans.^{4,5}

Theoretically then, Fourier analysis of blood-pool scans may provide an ideal opportunity to localize areas of early activation in patients with accessory atrioventricular pathways via a simple, noninvasive method requiring no expertise in complex electrophysiologic techniques. This report describes our early experience in localization of accessory atrioventricular pathways utilizing phase imaging of radionuclide scans.

Materials and methods

The method to be described was applied to 4 patients representative of the spectrum of accessory atrioventricular pathways. Cases 2, 3 and 4 are presented because the location of the accessory pathway and its electrophysiologic participation in the paroxysms of tachycardia were documented by multielectrode catheter studies. The first patient is a 42-year-old man with no evidence of an accessory pathway. The second is a 32-year-old man with a right-sided accessory pathway. The third, a 19-year-old man, has a left-sided accessory pathway. The fourth patient is a 21-year-old man with a documented left-sided accessory pathway that conducts only in retrograde manner.

1. *ECG gated ^{99m}Tc blood-pool scans:* Each patient received 20 mCi of ^{99m}Tc intravenously. After equilibration, the patients were imaged in the anterior and 45 degree left anterior oblique (LAO) projections at rest, and during sinus rhythm. Imaging was accomplished with an Ohio Nuclear 120 series gamma camera equipped with a high-sensitivity parallel-hole collimator. The data were collected by an Ohio Nuclear microprocessor in the frame mode, dividing the cardiac cycle into a series of 16 images or frames on a 64 × 64 matrix. On completion of the study, the data were transferred to magnetic tape and processed by a Simis 4 Informathek computer.

2. *Fourier phase imaging:* Fourier analysis is a long-established mathematical technique by which any periodic function can be represented as the sum of component waves with different frequencies, each frequency having a specific amplitude and phase (*Fig. 1*). The cyclic nature of the cardiac cycle is ideally suited to this form of analysis, which can be used to transform the cardiac cycle time-activity curve from a ^{99m}Tc-gated cardiac blood-pool scan into its various harmonics, and the phase and amplitude of the dominant harmonic can be calculated (*Fig. 2*). The phase angle calculated gives the exact starting point of the derived harmonic sinusoidal

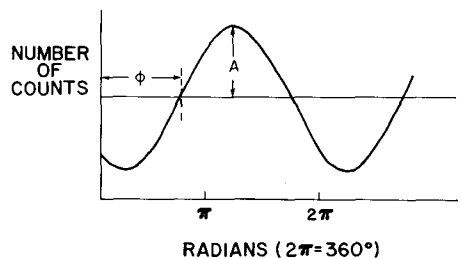


Fig. 1. Hypothetical derived dominant harmonic of Fourier series. ϕ = phase angle; A = amplitude.

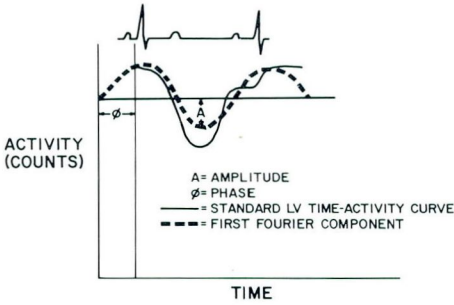


Fig. 2. Hypothetical gated blood-pool scan time-activity curve with derived first Fourier harmonic.

curve with reference to the R wave on the electrocardiogram (ranging from 0 to 360 degrees) (Fig. 2).

When applying this on a pixel-to-pixel* basis, a regional distribution of the relationship of movement between small areas of myocardium can be calculated. The greater the phase-angle difference between two areas, the greater the difference in the timing of contraction. Theoretically then, with this analysis, atria and ventricles can be separated as differently moving structures and the relationship of movement within the areas of ventricular myocardium can be characterized.

Prior to Fourier analysis, the tail end of the time-activity curves of each pixel was normalized by correcting for the reduced time in each of the late frames. This was necessary because in all frame-mode acquisitions, there is a diastolic falloff of counts prior to the R wave of the electrocardiogram because of the summation of some heartbeats with short cycle lengths. The temporal Fourier transform (see Appendix) was then applied to the individual pixel's time activity curves to derive the dominant (first) harmonic's phase angle. With this method, a phase angle (the R wave being the reference point for all phase

* Picture element.

angles) was derived for the first harmonic of the time-activity curves of each pixel. The phase image is then displayed by applying a color scale that extends through the entire spectrum of phase values (0-360 degrees) as shown in a normal case (Fig. 3). A color scale extending from 0 to 360 degrees gives an accurate visual display of the relationship of movement between structures whose phase-angle differences are very large (e.g., atria and ventricles). However, in order to appreciate small differences in movement within the ventricles, a flexible color scale was used to allow a finer angular resolution. Note the enhanced appreciation of phase-angle differences within the ventricles when the color scale changes from 0 to 360 degrees (Fig. 3) to 0 to 180 degrees (Fig. 4). Histograms were then created for the distribution of phase angles within each ventricle (X axis), and the number of pixels exhibiting these phase angles (Y axis). In each case, these histograms were compared for both the spectrum of

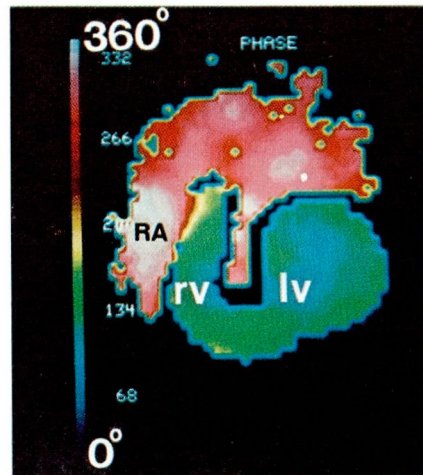


Fig. 3. Case 1. Left anterior oblique phase image, normal study. The color scale ranges from 0° to 360°. (RA = right atrium; rv = right ventricle; lv = left ventricle.)

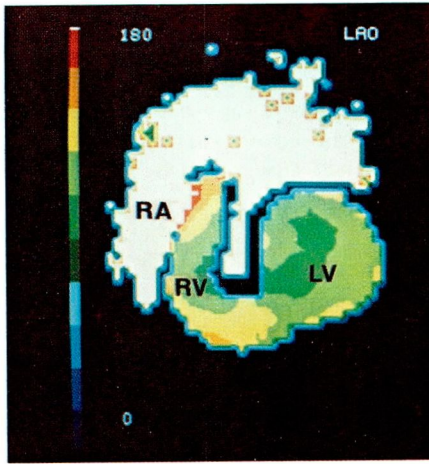


Fig. 4. Case 1. Left anterior oblique phase image, normal study. The color scale ranges from 0° to 180°.

phase angles and their earliest phase. Phase images were qualitatively inspected to decide the anatomical area of earliest and latest phase angles. The right ventricle was arbitrarily divided into right ventricular apex, right ventricular inflow, and right ventricular outflow areas. The left ventricle was divided into septal, posterobasal, and apical areas and the mean phase angles were calculated for each of these areas. The area of earliest phase angles (presumed area of earliest movement), the regions with the lowest mean phase angles, and the phase histograms were correlated with the location of the accessory atrioventricular pathway as determined electrophysiologically.

3. Electrophysiologic studies: Patients 2–4 underwent detailed electrophysiologic studies as previously described^{6,7}. Four or more multipolar electrode catheters were introduced via the right femoral vein and positioned in various places within the right atrium and right ventricle for both stimulation and recording. A coronary sinus catheter was inserted either through the right inter-

nal jugular or left median basilar vein. Both right and left atrial (coronary sinus) programmed pacing studies were performed. Eccentric atrial depolarization sequences were utilized to locate the accessory pathway when retrograde conduction occurred during either right ventricular pacing or orthodromic tachycardia.

Results

Electrophysiologic

Case 1. The history, physical examination, and chest radiograph revealed no evidence of organic heart disease. The resting electrocardiogram was normal.

Case 2. The resting electrocardiogram revealed preexcitation (*Fig. 5*). The accessory atrioventricular pathway was somewhat difficult to localize accurately because of the absence of retrograde conduction. Antegrade conduction over an extranodal accessory pathway was enhanced during right atrial pacing at progressively faster pacing rates. Pacing at various rates and sites within the coronary sinus revealed less preexcitation. Antidromic tachycardia (circus movement tachycardia with antegrade conduction over the accessory pathway and retrograde conduction over the His-AV node axis) was easily induced (*Fig. 6*). Antidromic tachycardia via a right-sided free wall accessory pathway was supported by a change to earlier activation of the right ventricular base, activation of the mid-right ventricular septum during the midportion of the QRS complex, and by left ventricular posterobasal activation during the terminal portion of the QRS complex. The sequence and physiology of retrograde VA conduction confirmed the participation of the His-AV node axis rather than an accessory pathway as the retrograde limb.

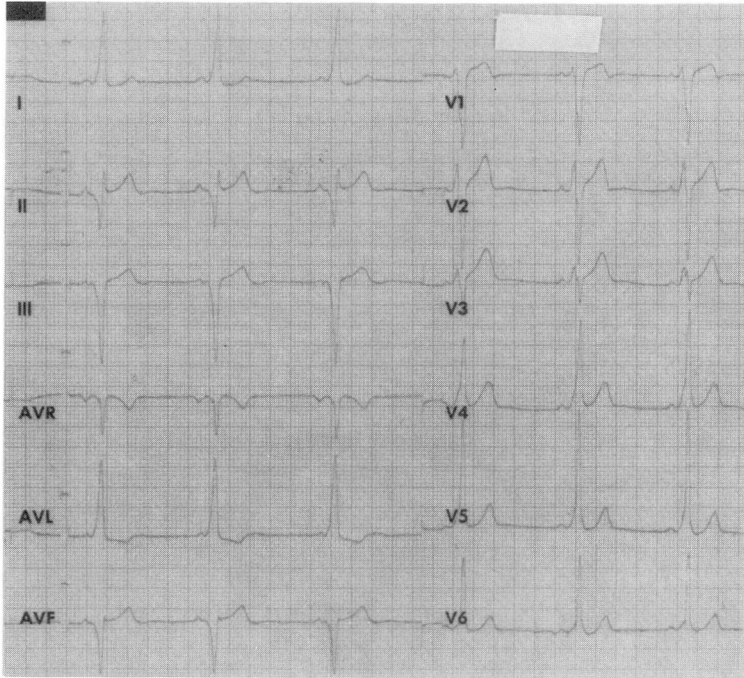


Fig. 5. Case 2. ECG indicates type B Wolff-Parkinson-White syndrome.

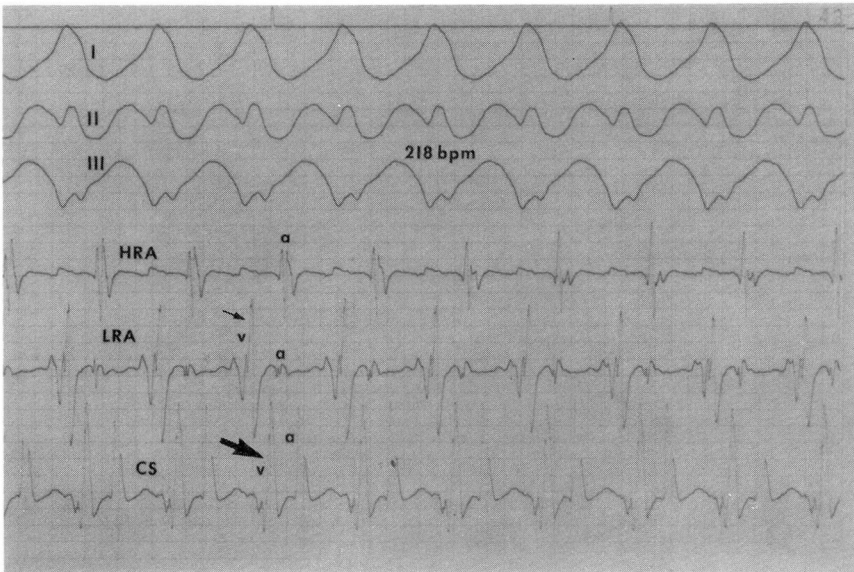


Fig. 6. Case 2. Recordings during episode of antidromic tachycardia. Recordings from above down are ECG leads I, II, and III, bipolar intracardiac electrograms from the high right atrium (HRA), low right atrium (LRA), and distal coronary sinus (CS). Note that mid-right ventricular septal activation (smaller arrow) occurs during the midportion of the QRS complex and that left ventricular posterobasal activation occurs much later in association with later phases of the QRS complex.

Case 3. The resting electrocardiogram demonstrated preexcitation (*Fig. 7*). Orthodromic tachycardia (circus movement tachycardia with antegrade conduction over the AV node-His axis and retrograde conduction over the extranodal accessory pathway) was easily induced by programmed atrial stimulation. Analysis of the simultaneous electrogram permitted identification of a retrograde eccentric atrial activation sequence with earliest activation localized to the proximal midcoronary sinus area (*Fig. 8*). Right ventricular pacing produced this same eccentric activation sequence typical of a left posterior para-septal accessory pathway.

Case 4. The resting ECG was normal but multiple episodes of exercise-induced narrow QRS complex tachycardia with rates in excess of 180 beats/min were documented. There was no evidence of antegrade conduction over

the accessory pathway either during prolonged ECG monitoring or electrophysiologic study. Retrograde conduction over an extranodal pathway as revealed by an eccentric atrial depolarization sequence was easily demonstrated during both orthodromic tachycardia and right ventricular pacing. Earliest atrial activation was recorded in the region of the distal coronary sinus confirming the presence of a left lateral accessory pathway (*Fig. 9*). Subsequent intraoperative mapping and successful surgical division of the accessory pathway further confirmed the accuracy of the preoperative electrophysiologic data.

Radionuclide

All patients had normal wall motion as assessed in both the anterior and LAO projections with use of regular gated cardiac scans. Ejection fractions

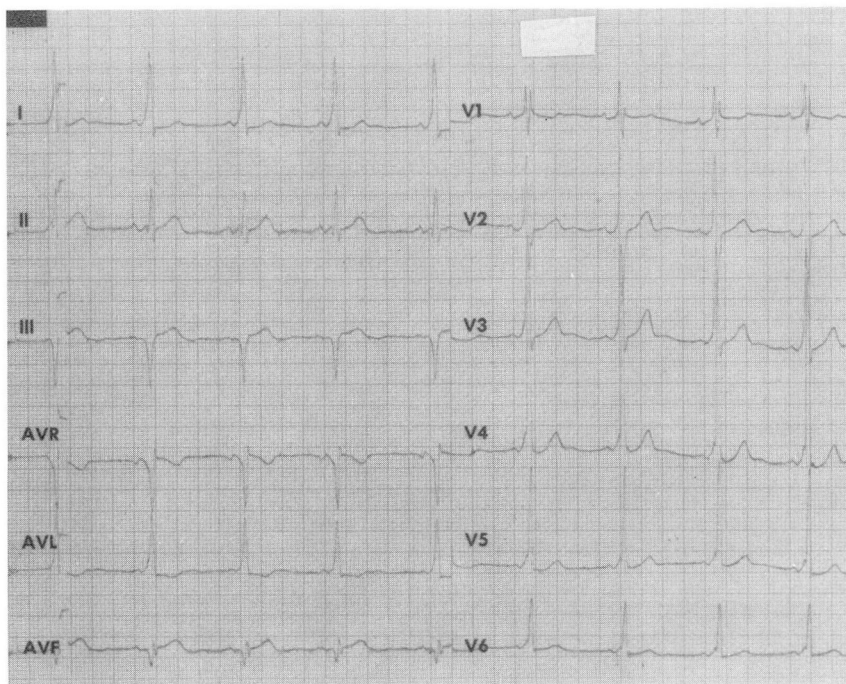


Fig. 7. Case 3. ECG indicates type A Wolff-Parkinson-White syndrome.

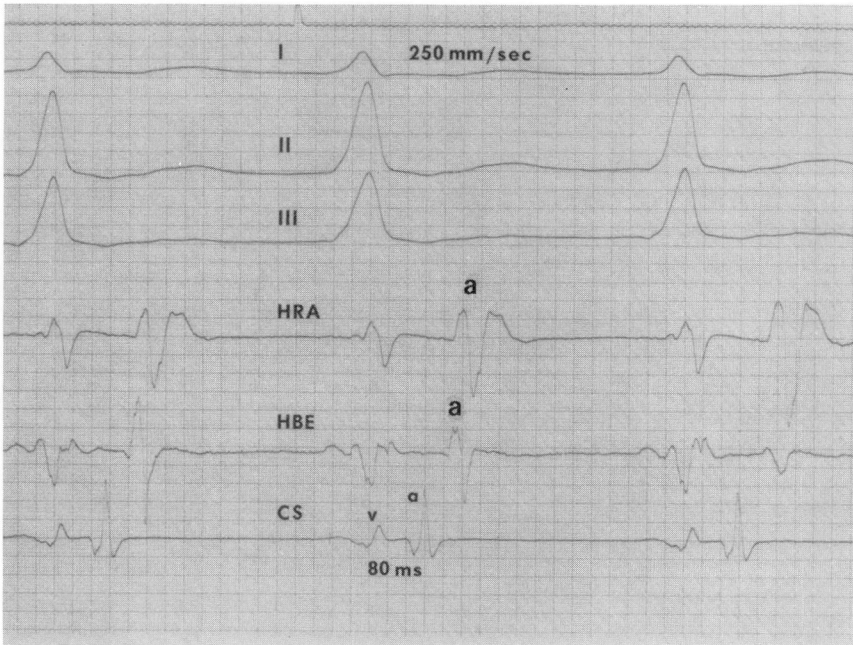


Fig. 8. Case 3. Recordings during orthodromic tachycardia. Recordings from above down are surface ECG leads I, II, and III, bipolar intracardiac electrograms from the high right atrium (*HRA*), His bundle region (*HBE*) and proximal coronary sinus (*CS*). Eccentric atrial activation with earliest depolarization in the proximal coronary sinus confirms the presence of a left posterior paraseptal pathway.

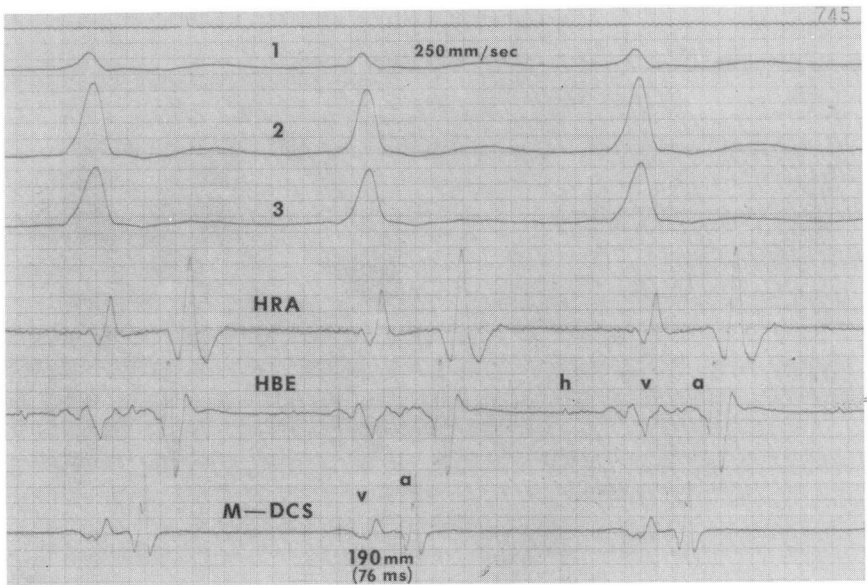


Fig. 9. Case 4. Orthodromic tachycardia. Recordings from above down are surface ECG leads I, II, and III, bipolar intracardiac electrograms from the high right atrium (*HRA*), His bundle region (*HBE*), and mid-distal coronary sinus (*M-DCS*). Earliest activation during the eccentric atrial activation sequence occurs in the mid-distal coronary sinus confirming the presence of a left lateral accessory pathway.

calculated in each case were within the normal range for our laboratory (50–65 percent).

Phase imaging

Case 1. The phase image generated in this patient (*Fig. 4*) shows the earliest phase angles along the interventricular septum and the latest in the basal regions of the right and left ventricles and the left ventricular free wall. In the phase histogram generated for the right ventricle (*Fig. 10*), phase angles range from 110 to 144 degrees. The histogram generated over the left ventricle shows a similar narrow peak of phase angles ranging from 110 to 156 degrees. The mean phase angles from each region are shown in the *Table*; the lowest mean phase angle (98 degrees) was seen in the septal region.

Case 2. The phase image generated in this patient shows a large, striking area of very early phase angles (shades of blue in *Fig. 11*) at the base of the right ventricle near the right atrium. This is in striking contrast to the latest phase angles seen in the same area in the patient in Case 1. The latest phase angles in this patient are in the base of the right ventricle, and in the antero-apical region of the left ventricle. The phase histogram generated over the

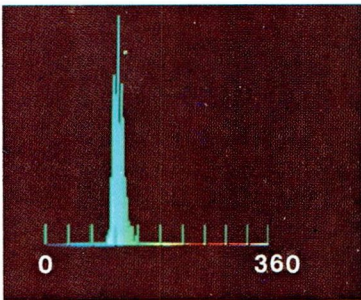


Fig. 10. Case 1. Phase histogram of the right ventricle. The X axis represents the calculated phase angles, range 0° to 360°. The Y axis represents the number of pixels.

Table. Mean phase angles within each ventricular region

	Right ventricle			Left ventricle		
	RVO	RVI	RVA	LVS	LVPB	LVA
Case 1	145	123	131	113	116	116
Case 2	130	83	111	137	139	157
Case 3	134	129	122	96	124	131
Case 4	117	120	116	117	122	129

RVO = Right ventricular outflow
 RVI = Right ventricular inflow
 RVA = Right ventricular apex
 LVS = Left ventricular septal
 LVPB = Left ventricular posterobasal
 LVA = Left ventricular apex

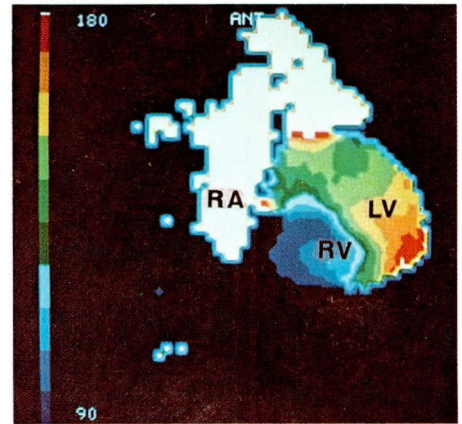


Fig. 11. Case 2. Phase image in the anterior view reveals a right-sided accessory pathway.

right ventricle (*Fig. 12*) shows phase angles ranging from 36 to 155 degrees with two distinct peaks. The phase histogram generated over the left ventricle shows a narrow peak similar to that in Case 1, with phase angles ranging from 120 to 158 degrees. The mean phase angles for each of these regions are seen in the *Table*; the lowest mean phase angle (72 degrees) was seen in the right ventricular inflow region.

Case 3. The earliest phase angles are seen in the basal portion of the interventricular septum and the basal portion of the left ventricle, the latest

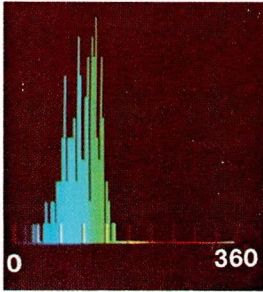


Fig. 12. Case 2. Phase histogram of the right ventricle. The X axis represents the calculated phase angles, range 0° to 360°. The Y axis represents the number of pixels.

being in the left ventricular apex and at the base of the right ventricle (*Fig. 13*). The phase histogram generated over the left ventricle demonstrated a range of phase angles from 40 to 144 degrees, with two distinct peaks. The phase histogram generated over the right ventricle showed a discrete peak with a range of phase angles from 110 to 144 degrees. The *Table* lists the mean phase angles for each region; the lowest mean phase angle (80 degrees) was seen in the left ventricular septal region near the base.

Case 4. The phase image generated for this patient showed the earliest activation in the interventricular septal region and the latest in the right ventricular base, the left ventricular apex and left ventricular free wall, similar to the normal phase image in Case 3. The phase histogram of the right and left ventricles revealed narrow peaks with phase angles ranging from 108 to 156 degrees and 108 to 144 degrees, respectively. The mean phase angles for each region are shown in the *Table*; the lowest mean phase angle (117 degrees) was in the left ventricular septal region.

Discussion

Since the introduction of Fourier phase and amplitude imaging by Adam et al⁸, its application has been directed

to localizing and measuring regions of abnormal myocardial movement in patients with coronary artery disease.^{2, 8} Until recently, little attention has been paid to its use in assessing patterns of myocardial activation. Swiryn et al⁵ have recently reported the application of phase imaging to patients with and without left bundle branch block. Characteristically, patients with normal ventricular activation showed a narrow range of phase angles on phase histograms with a mean value of 150 (± 24 degrees SD). Patients with left bundle branch block had wide, double-peaked histograms with delayed larger phase angles over the left ventricle. In a similar manner then, it would follow that if accessory atrioventricular pathways are conducting antegradely and activating portions of the myocardium earlier than normal, then movements in the blood pool should reflect this anomalous pattern in the same way that it appears to be reflected in left bundle branch block. Analysis of phase angles on a pixel-to-pixel basis allows a regional distribution of phase angles within the myocardium and hence indirectly relays information

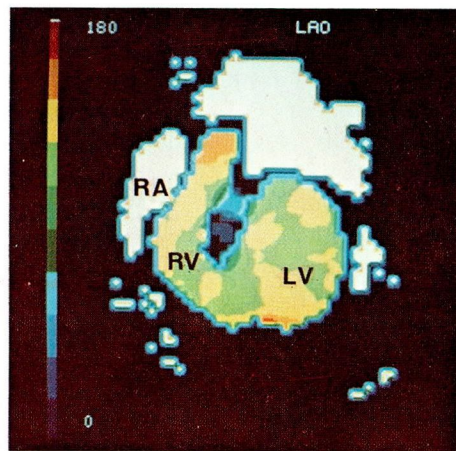


Fig. 13. Case 3. Phase image, LAO view. Note the early phase angles in the high septal region.

about the relationship of contraction between small areas of myocardium.

In our study, the two patients with preexcitation of the ventricles via antegrade conduction over the accessory pathways (Cases 2 and 3) had striking areas of early phase angles. Phase histograms showed double-peaked distribution similar to that seen in the studies with left bundle branch block, but the new peak had very early phase angles. Analysis of the mean phase angles within each region of each ventricle showed one area that contained significantly lower mean phase angles than all other regions. The anatomical location of these early phase angles coincided closely with the location of the accessory atrioventricular pathways as determined by electrophysiological studies. The pattern of myocardial blood-pool movement, as reflected by the phase images in these patients, bears a striking resemblance to patterns of the anomalous ventricular activation sequence seen in Wolff-Parkinson-White syndrome. Note the pattern of myocardial movement in the phase image in Case 2, an example of a right-sided accessory pathway (*Fig. 11*) and its similarity to a right-sided pathway as assessed by epicardial mapping (*Fig. 14*). In Case 1, a patient with a normal ventricular activation sequence, the pattern of blood-pool movement seen in the phase image (*Fig. 4*) conforms to patterns of normal epicardial activation (*Fig. 15*). In Case 4, a concealed accessory pathway was present that conducted only in retrograde manner.⁹ Hence, conduction proceeded normally down the AV node-His axis. Therefore, the pattern of blood-pool movement was expected to be normal, as in Case 1, which indeed it was.

There is some debate over which patients with Wolff-Parkinson-White syn-

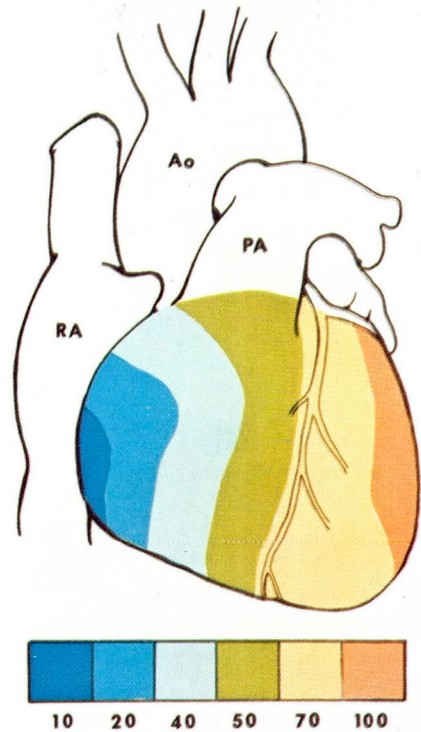


Fig. 14. Diagrammatic representation of the pattern of epicardial activation typical of a right-sided accessory atrioventricular pathway. (RA = right atrium; Ao = aorta; PA = pulmonary artery.)

drome should be studied electrophysiologically. Irrespective of varying opinions and differing patient populations, there are clearly subgroups of patients in which electrophysiologic studies are essential. Gallagher et al¹⁰ have described a protocol for the invasive electrophysiologic study of such patients. During a detailed electrophysiologic study, the answers to several important questions will determine what additional data should be obtained. First of all, does the patient indeed have preexcitation or is the abnormal QRS complex on the surface ECG related to the presence of congenital heart disease or some other form of conduction system disease? Secondly, is the ventricular

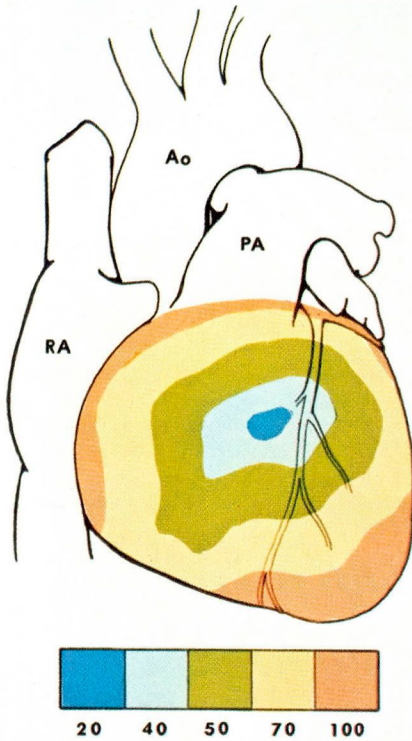


Fig. 15. Diagrammatic representation of the pattern of epicardial activation typical of patients with normal ventricular activation.

complex observed in the Wolff-Parkinson-White syndrome during sinus rhythm the result of fusion, with the initial portion of the QRS complex representative of earliest activation of the ventricles utilizing the accessory pathway, and the later portions of the QRS complex representative of later activation utilizing the AV node-His-Purkinje system? Thirdly, the location of the accessory pathway needs to be determined. Fourthly, the effective refractory period of the accessory pathway must be determined and, lastly, we need to know whether or not the accessory pathway is utilized during the patient's paroxysms of tachycardia.

From theoretical considerations as well as the initial clinical application

described above, Fourier phase imaging should define and localize areas of early activation. If more extensive studies demonstrate that this initial impression is valid, then phase imaging could address questions which previously have been answered only by invasive electrophysiologic study. Firstly, phase imaging may resolve the clinical dilemma as to whether the abnormal QRS complex is due to preexcitation or another conduction system abnormality. Secondly, phase imaging may be of value in various difficult electrophysiologic settings when attempting to localize accessory pathways. For instance, when an accessory pathway does not conduct retrogradely and circus movement tachycardia cannot be induced, the accessory pathway may be difficult to localize electrophysiologically. Septal and paraseptal pathways are frequently more difficult to delineate and localize accurately. Phase imaging may be of value in these settings. Similarly, multiple accessory pathways, particularly those located at distant sites, may be suggested by phase imaging. Additionally, prior to electrophysiologic study, this new, noninvasive, less time-consuming method may well have a role in the initial screening for Wolff-Parkinson-White syndrome and in further delineating the natural history of the disease. Finally, in addition to being an excellent tool for assessing the efficacy of drug therapy on the electrophysiologic properties of the accessory pathway, phase imaging should provide an excellent means of following patients who have undergone surgical division of the accessory pathway.

Appendix

If $f(t)$ represents the time-activity curve of a cyclic function, the Fourier

expansion of this function can be expressed as:

$$f(t) = \frac{A_0}{2} + \sum_{K=1}^{\infty} \left[a_K \cdot \cos\left(K \cdot \frac{2\pi}{N} \cdot t\right) + b_K \sin\left(K \cdot \frac{2\pi}{N} \cdot t\right) \right]$$

Where:

t = time
 K = the number of the harmonic
 N = number of points sampled in each beat (in our case 16)

$\frac{A_0}{2}$ = average of $f(t)$

i = discrete variable time (equivalent to t)

Calculation of coefficients a_K and b_K in the discrete case (where the variable is i instead of t) =

$$a_K = \frac{2}{N} \sum_{i=1}^N f(i) \cos\left((i-1) \frac{2\pi}{N} \cdot K\right)$$

$$b_K = \frac{2}{N} \sum_{i=1}^N f(i) \sin\left((i-1) \frac{2\pi}{N} \cdot K\right)$$

It happens that,

$$\begin{aligned} & a_K \cdot \cos\left((i-1) \frac{2\pi}{N} \cdot K\right) \\ & + b_K \cdot \sin\left((i-1) \frac{2\pi}{N} \cdot K\right) \\ & = \dot{A}_K \sin\left((i-1) \frac{2\pi}{N} \cdot K + \phi_K\right) \end{aligned}$$

Where \dot{A}_K = amplitude of the K th harmonic and ϕ_K = phase of the K th harmonic

$$\dot{A}_K = \sqrt{a_K^2 + b_K^2}$$

(in our case $\dot{A}_1 = \sqrt{a_1^2 + b_1^2}$)

$$\phi_K = \arctan\left(\frac{a_K}{b_K}\right)$$

(in our case $\phi_1 = \arctan\left(\frac{b_1}{a_1}\right)$)

Acknowledgment

We would like to thank Paula LaManna for technical assistance.

References

1. Durrer D, van Dam RT, Freud GE, Janse MJ, Meijler FL, Arzbacher RC. Total excitation of the isolated human heart. *Circulation* 1970; **41**: 899-912.
2. Walton S, Yiannikas J, Jarritt PH, Brown NJG, Swanton RH, Ell PJ. Phasic abnormalities of left ventricular emptying in coronary artery disease. *Br Heart J* 1981; **46**: 245-53.
3. Yiannikas J, MacIntyre W, Underwood D, Cook SA, Go RT, Loop FD. Prediction of improvement in left ventricular function following ventricular aneurysmectomy using Fourier phase and amplitude analysis of radionuclide scans (abst). *Am J Cardiol* 1982; **49**: 1045.
4. Links JM, Douglass KH, Wagner HN Jr. Patterns of ventricular emptying by Fourier analysis of gated blood-pool studies. *J Nucl Med* 1980; **21**: 978-82.
5. Swiryn S, Pavel D, Byrom E, et al. Sequential regional phase mapping of radionuclide gated biventriculograms in patients with left bundle branch block. *Am Heart J* 1981; **102**: 1000-10.
6. Svenson RH, Miller HC, Gallagher JJ, Wallace AG. Electrophysiological evaluation of the Wolff-Parkinson-White syndrome; problems in assessing antegrade and retrograde conduction over the accessory pathway. *Circulation* 1975; **52**: 552-62.
7. Wellens HJJ, Farre J, Ross D, Vanagt EJ, Bar FW. Preoperative localization of bypass tract(s) in the Wolff-Parkinson-White syndrome. In: Bircks W, Loogen F, Schulte HD, Seipel L, ed. *Medical and Surgical Management of Tachyarrhythmias*. Springer-Verlag, 1980, 94-105.
8. Adam WE, Tarkowska A, Bitter F, Stauch M, Geffers H. Equilibrium (gated) radionuclide ventriculography. *Cardiovasc Radiol* 1979; **2**: 161-73.
9. Holmes DR Jr, Hartzler GO, Maloney JD. Concealed retrograde bypass tracts and enhanced atrioventricular nodal conduction: an unusual subset of patients with refractory paroxysmal supraventricular tachycardia. *Am J Cardiol* 1980; **45**: 1053-60.
10. Gallagher JJ, Gilbert M, Svenson RH, Sealy WC, Kasell J, Wallace AG. Wolff-Parkinson-White syndrome: the problem, evaluation, and surgical correction. *Circulation* 1975; **51**: 767-85.