

Prolactin-secreting pituitary adenoma: occurrence following prenatal exposure to diethylstilbestrol

James R. Cunningham, M.D.

Department of Hematology and Medical Oncology

Gita P. Gidwani, M.D.

Department of Gynecology

Manjula S. Gupta, Ph.D.

Division of Laboratory Medicine

Paul M. Duchesneau, M.D.

Division of Radiology

O. Peter Schumacher, M.D.,
Ph.D.

Department of Endocrinology

Prenatal exposure to diethylstilbestrol (DES), a synthetic, nonsteroidal estrogen, substantially increases the risk of developing clear-cell adenocarcinoma of the vagina and cervix, and structural abnormalities of the vagina, cervix, and uterus.¹⁻⁴ Whether in utero exposure to the drug influences subsequent menstrual history and fertility is uncertain; two controlled prospective studies^{5,6} revealed conflicting results.

We report a prolactin-secreting pituitary adenoma in a young woman who had been referred for evaluation of amenorrhea, with a history of in utero exposure to DES. Evaluation of tumor sensitivity to dopaminergic influence and three-year follow-up during treatment with bromocriptine are described.

Case report

An 18-year-old woman was referred to the Cleveland Clinic in July 1979, for evaluation of amenorrhea. The patient's mother had taken a daily course of diethylstilbestrol prescribed by her obstetrician from the second through the ninth month of pregnancy because of a previous miscarriage. Records of dosage were not available. Pregnancy was otherwise unremarkable and ended at term by cesarean section. Growth and development were normal. Menses began at age 13, became irregular with frequent lapses of 2-3 months between periods, and stopped at age 16. Two courses of oral progesterone

prescribed by her family physician produced withdrawal bleeding, but failed to induce subsequent periods. One and a half years later, a third trial of progesterone was unsuccessful in producing withdrawal bleeding. The patient felt well, and had no previous hospitalizations or other illnesses. There was no history of use of oral contraceptives, anti-hypertensive medication, or tranquilizers. Two sisters, aged 13 and 21, were in good health and had normal menstrual periods. On physical examination both breasts were fully developed, from which small amounts of clear, colorless fluid could be expressed. External genitalia and pubic hair were Tanner Stage IV. On bimanual examination, the uterus was unstimulated and the adnexa were not enlarged. Culposcopic examination was abnormal, revealing a wide zone of ectopy extending over most of the exocervix. Within this erosion, multiple punctate areas of white epithelium were observed. Three small areas of hemorrhage were present on the vaginal wall. The remainder of the examination was normal.

Cervical mucus was fern-negative and lacked spinnbarkeit. Six Papanicolaou smears of the vagina and cervix disclosed no tumor cells.

Serum prolactin measured by radioimmunoassay was markedly elevated at 388 ng/ml. Serum luteinizing hormone by radioimmunoassay was 6.4 mIU/ml. Follicle-stimulating hormone was 13.1 mIU/ml. Serum estrogens were 7.0 ng/ml. Results of tests of thyroid and adrenal function were normal. A urine pregnancy test was negative.

Polytomographic examination of the sella turcica revealed moderate to marked enlargement on the left side with erosion of the left dorsum. Computed axial tomograms of the head demonstrated extension of the sella into the sphenoid sinus.

Following prolactin suppression and stimulation tests, bromocriptine (Parlodel), 2.5 mg orally, twice a day, was prescribed. Follow-up at 1, 2, and 3 years after diagnosis, with the use of sector scans of the sella turcica (*Fig. 1*) showed a decrease in size of the tumor from 12 × 12 mm in 1980 to 9 × 6 mm in 1982 (>50% reduction).

Serum prolactin level, measured three months after initiation of treatment, was reduced by approximately two thirds to 124 ng/ml. The patient has remained asymptomatic although menses have not yet resumed and serum estradiol levels remain below 10 pg/ml.

Methods

Four weeks after diagnosis, the patient was readmitted to the Cleveland Clinic Hospital. Stimulation and suppression tests of prolactin secretion were done over a 24-hour period with the patient at rest and fasting.

Samples of blood were taken through a heparin lock 15 minutes before, at the time of, and at regular intervals up to two hours after administration of (1) thyroid-releasing hormone protirelin (Thyponone), 400 µg intravenously for measurement of serum prolactin and thyroid stimulating hormone (TSH); (2) chlorpromazine (Thorazine), 25 mg, for measurement of serum prolactin; and (3) levodopa (Larodopa), 500 mg orally, for measurement of serum prolactin and growth hormone.

Assays

Serum prolactin, TSH, and growth hormone were measured with the use of modified double antibody radioimmunoassays.⁷⁻⁹

The lower limits of sensitivity of these assays for prolactin, TSH, and growth hormone were 1.0 ng/ml, 1.5 µU/ml, and 1.0 ng/ml, respectively. Normal ranges for women are: prolactin, 10.2 ± 4.7 ng/ml (SD); TSH, 2.8 ± 1.0 µU/ml (SD); growth hormone, 1-5 ng/ml.

Laboratory findings

The results of two tests of prolactin stimulation of suppression are shown in *Figure 2*.

Following the administration of lev-

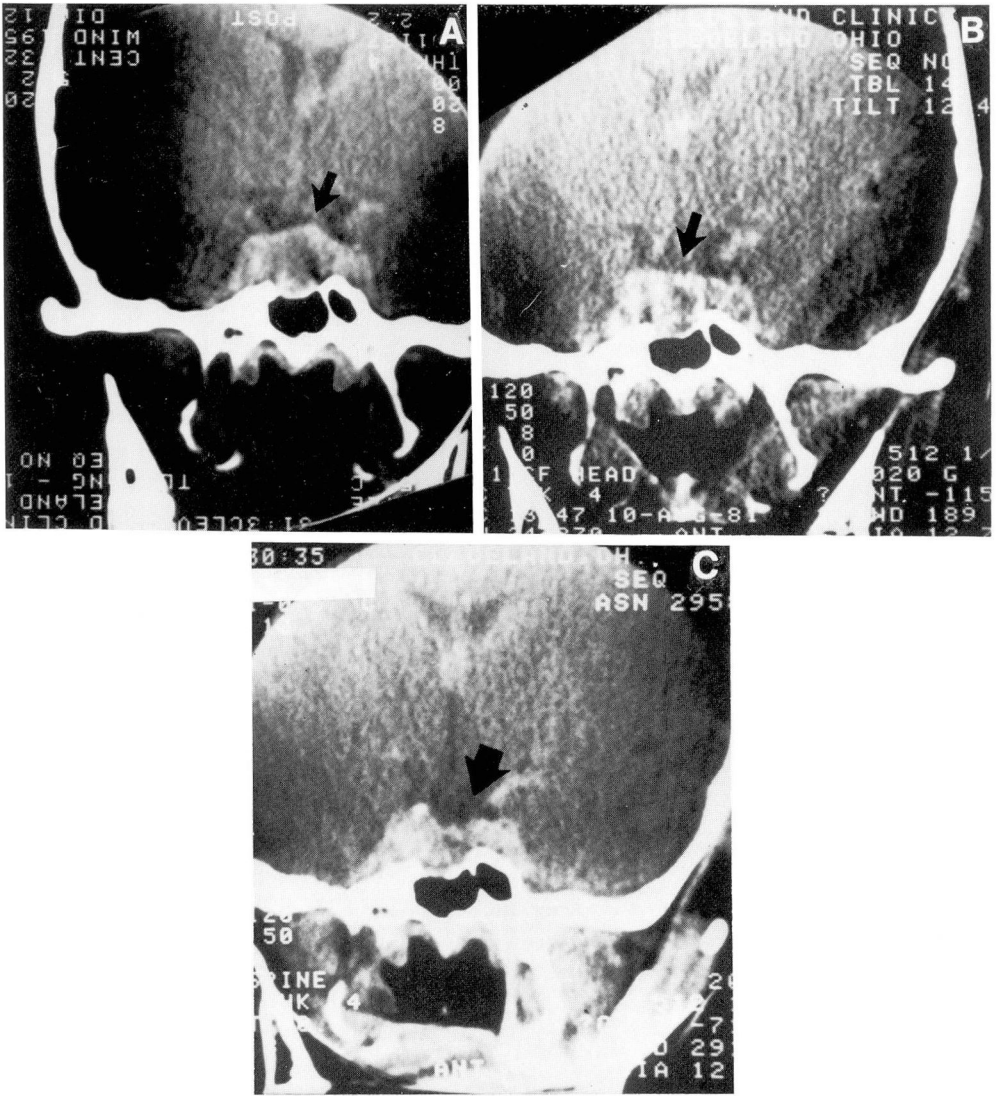


Fig. 1A-C. Sector CT scans of the sella turcica at 1, 2, and 3 years follow-up showing progressive decrease in size of the pituitary adenoma.

odopa, a prompt reduction in level of serum prolactin occurred to approximately 30% of basal level in 90 minutes. Measurement of growth hormone during the same period demonstrated a simultaneous two-fold elevation in serum levels (Fig. 2A).

Chlorpromazine augmented prolactin secretion by nearly 100% as shown

in Figure 2B. Elevation reached a peak in 90 minutes, but this effect, similar to that of levodopa, was not sustained beyond 120 minutes.

Prolactin secretion was less sensitive to thyrotrophin-releasing hormone (TRH) but produced a mean elevation in prolactin level of 16% over 90 minutes. Concomitantly, TSH levels in-

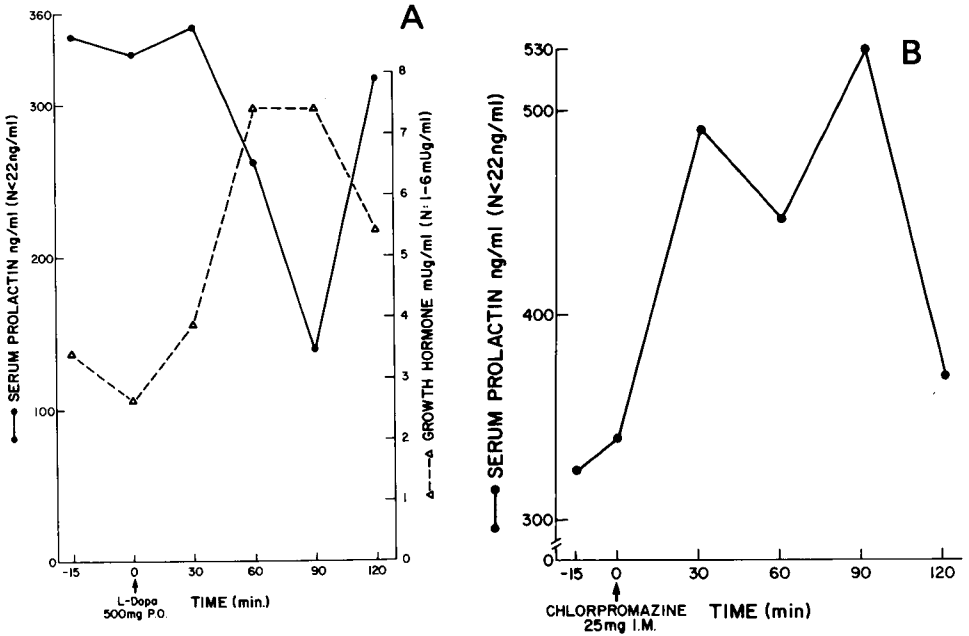


Fig. 2. Change in serum prolactin and growth hormone levels with time following the administration of levodopa (A) and chlorpromazine (B).

creased more than threefold after injection.

Discussion

In studies of rodent species, there is evidence linking estrogen to the development of prolactin-secreting pituitary adenomas when chronic exposure to DES regularly induces prolactinomas. Results of controlled studies have correlated such exposure to increase in serum prolactin level,¹⁰ pituitary prolactin and DNA synthesis,¹¹ and pituitary cell multiplication.¹²

The direct role of estrogen in pituitary tumorigenesis in animals has been suggested both by the demonstration of estrogen receptors in the cytosol of estrogen-induced prolactinomas¹³ and growth inhibition of a transplantable estrogen-induced prolactin-secreting rat pituitary tumor by the administration of the estrogen receptor blocking drug, tamoxifen.¹⁴

With the development of methods of increased sensitivity in detecting these lesions, suspicion has arisen that pituitary prolactinoma development in humans is associated with estrogen exposure. Since the initial report¹⁵ in 1966 of amenorrhea occurring after use of oral contraceptives, three studies of women with prolactin-secreting pituitary adenomas have shown a high frequency of use among these patients.¹⁶⁻¹⁸ Recently a retrospective case-controlled study of 20 women with hyperprolactinemia and pituitary tumors¹⁹ revealed the relative risk of tumor was 4.0 for patients using oral contraceptives, although this association has been disputed.²⁰ In addition, in a recent study high levels of estrogen-binding protein in the cytosol of pituitary adenomas recovered from transphenoidal surgery were found in most patients with hyperprolactinemia.²¹

In our patient, two major periods of estrogen exposure occurred. In utero,

endogenous levels of estrogen were supplemented by DES in pharmacological doses. Thirteen years later a second rise in endogenous estrogen levels began with the onset of menarche. If estrogen-sensitive lactotrophic cells within the pituitary expanded beyond normal from supraphysiologic levels of estrogen during pregnancy, it is conceivable that following menarche, reexposure to high estrogen levels may have provided enough stimulus for these cells to achieve autonomous growth.

The two-year history of oligomenorrhea that precedes the onset of amenorrhea supports this theory. This and the subsequent history of initially successful progesterone test results followed 18 months later by an unsuccessful test result, is consistent with the gradual development of hyperprolactinemia and hypogonadism that would be expected to accompany a slowly growing prolactinoma.

The results of stimulation and suppression tests employing levodopa and chlorpromazine suggested responsiveness of this tumor to dopaminergic influence. Bromocriptine, a dopaminergic agonist, was successful in reducing both serum prolactin levels and tumor size in this patient. This result is consistent with the experience of others.^{22, 23} Assessment of response to treatment in our patient was facilitated by sector computed tomographic scans, which provided accurate measurement of tumor.

References

- Herbst AL, Ulfelder H, Poskanzer DC. Adenocarcinoma of the vagina; association of maternal stilbestrol therapy with tumor appearance in young women. *N Engl J Med* 1971; **283**: 878-881.
- Herbst AL, Poskanzer DC, Robboy SJ, Friedlander L, Scully RE. Prenatal exposure to stilbestrol, a prospective comparison of exposed female offspring with unexposed controls. *N Engl J Med* 1975; **292**: 334-339.
- Mangan CE, Giuntoli RL, Sedlacek TV, et al. Six years' experience with screening of a diethylstilbestrol-exposed population. *Am J Obstet Gynecol* 1979; **134**: 860-865.
- Kaufman RH, Binder GL, Gray PM Jr, Adam E. Upper genital tract changes associated with exposure in utero to diethylstilbestrol. *Am J Obstet Gynecol* 1977; **128**: 51-57.
- Bibbo M, Gill WB, Azizi F, et al. Follow-up study of male and female offspring of DES-exposed mothers. *Obstet Gynecol* 1977; **49**: 1-8.
- Barnes AB, Colton T, Gundersen J, et al. Fertility and outcome of pregnancy in women exposed in utero to diethylstilbestrol. *N Engl J Med* 1980; **302**: 609-613.
- Sinha YN, Selby FW, Lewis UJ, Vanderlaan WP. A homologous radioimmunoassay for human prolactin. *J Clin Endocrinol Metab* 1973; **36**: 509-516.
- Mayberry WE, Gharib H, Bilstad JM, Sizemore GW. Radioimmunoassay for human thyrotrophin; clinical value in patients with normal and abnormal thyroid function. *Ann Intern Med* 1971; **74**: 471-480.
- Greenwood FC, Hunter WM, Glover TS. The preparation of ¹³¹I labelled human growth hormone of high specific radioactivity. *Biochem J* 1963; **89**: 114-123.
- Chen CL, Meites J. Effects of estrogen and progesterone on serum and pituitary prolactin levels in ovariectomized rats. *Endocrinology* 1970; **86**: 503-505.
- De Nicola AF, von Lawzewitsch I, Kaplan SE, Libertun C. Biochemical and ultrastructural studies on estrogen-induced pituitary tumors in F344 rats. *J Natl Cancer Inst* 1978; **61**: 753-763.
- Lee H, Davies IJ, Soto AM, Sonnenschein C. Estrogen induction of progesterone receptor and its relationship to cell multiplication rate in the rat pituitary tumor cell line C₂9RAP. *Endocrinology* 1981; **108**: 990-995.
- Attramadal A, Haug E, Naess O, et al. Specific binding of oestradiol induced prolactin secreting pituitary tumours in rats. *Acta Pathol Microbiol Scand* 1974; **suppl 248**: 21-31.
- Lamberts SW, Uitterlinden P, Zuiderwijk-Roest JM, Bons-van Evelingen EG, de Jong FH. Effects of a luteinizing hormone-releasing hormone analog and tamoxifen on the growth of an estrogen-induced prolactin-secreting rat pituitary tumor and its influence on pituitary gonadotropins. *Endocrinology* 1981; **108**: 1878-1884.
- Shearman RP. Amenorrhoea after treatment with oral contraceptives. *Lancet* 1966; **2**:

- 1110-1113.
16. March CM, Kletzky OA, Israel R, Davajan V, Mishell DR Jr. Amenorrhea, galactorrhea, and pituitary tumors; postpill and non-post-pill. *Fertil Steril* 1977; **28**: 346.
 17. Van Campenhout J, Blanchet P, Beauregard H, Papas S. Amenorrhea following the use of oral contraceptives. *Fertil Steril* 1977; **28**: 728-732.
 18. Sherman BM, Harris CE, Schlechte J, et al. Pathogenesis of prolactin-secreting pituitary adenomas. *Lancet* 1978; **2**: 1019-1021.
 19. Teperman L, Futterweit W, Zappulla R, Malis LI. Oral contraceptive history as a risk indicator in patients with pituitary tumors with hyperprolactinemia; a case comparison study of twenty patients. *Neurosurgery* 1980; **7**: 571-573.
 20. Coulam CB, Annegers JF, Abboud CF, Laws ER Jr, Kurland LT. Pituitary adenoma and oral contraceptives; a case-control study. *Fertil Steril* 1979; **31**: 25-28.
 21. Pichon MF, Bression D, Peillon F, Milgram E. Estrogen receptors in human pituitary adenomas. *J Clin Endocrinol Metab* 1980; **51**: 897-902.
 22. Baskin DS, Wilson CB. Bromocriptine treatment of pituitary adenomas. *Neurosurgery* 1981; **8**: 741-744.
 23. McGregor AM, Scanlon MF, Hall K, Cook DB, Hall R. Reduction in size of a pituitary tumor by bromocriptine therapy. *N Engl J Med* 1979; **300**: 291-293.