

## TREATMENT OF CENTRAL OR INTRACAPSULAR FRACTURES OF THE NECK OF THE FEMUR

JAMES A. DICKSON, M.D.

In discussing fractures of the upper end of the femur, it is very important to differentiate between intertrochanteric fractures and central or intracapsular fractures of the neck of the femur. In many of the large series of cases of fractures of the neck of the femur that have been reported, it has been shown that approximately 40 to 45 per cent are central fractures and that 55 to 60 per cent are intertrochanteric fractures. In intertrochanteric fractures, bony union may be expected if approximate anatomic apposition is maintained by casts or various forms of traction. In the central fractures of the neck of the femur, there has in the past been much doubt about securing osseous union. It is about the treatment of this group that I wish to direct my remarks.

Prior to 1904, it was considered that central or intracapsular fractures would not unite by osseous union, it being assumed that this type of fracture was essentially an attribute of old age. Stimson in his "Practical Treatise on Fractures and Dislocations" in 1910, stated "restoration of function is rarely to be attempted or even sought," and Pye in his book called "Surgical Handicraft" stated "the patient should be propped up in bed with the limb between sand bags. After about a month, the patient should be encouraged to use the leg as much as possible since union is not aimed at."

In 1904, Doctor Royal Whitman first described the abduction method of reduction and fixation by use of a plaster of paris spica and he demonstrated that osseous union could be secured. Obviously, the Whitman method was the first and possibly the greatest advance that had been made in the treatment of this fracture. By proper use of the Whitman treatment by abduction, the mortality rate from bed sores and static congestion of the lungs was greatly minimized. Although certain clinics reported that osseous union followed the use of the abduction treatment in as high as 65 per cent of the cases, reports of the Committee on Fractures of the American Orthopaedic Association in 1929, reviewing the results from several clinics, showed that osseous union was secured in only 50.4 per cent. This certainly left much to be desired, as a long confinement in a plaster cast was necessary before osseous union could be determined and often permanent restriction of movement of the hip and knee resulted.

Sufficient data have now been accumulated to prove that better results can be obtained by the use of internal fixation than by the closed reduction followed by prolonged rest in a spica cast. The operative treatment of fractures of the hip has constituted a very distinct advancement and

has been brought to our attention chiefly through the work of Smith-Petersen of Boston, Johansson of Gothenberg, Sweden, King of Melbourne, Australia, and others.

In 1925, Smith-Petersen introduced a three flanged nail which he placed through the neck of the femur by means of a wide exposure of the hip joint. Although this method of treatment obviously had many advantages, it was not adopted immediately as it was felt that this procedure was too formidable. At the time of introduction of this method, lateral roentgenograms of the hip were not available, so that rather an extensive exposure of the hip joint was necessary in order to insert the nail accurately. However, since lateral roentgenograms of the hip have been possible, a very definite advance has been made in the treatment of fractures in this region, as the nail can be inserted by the so-called "blind nailing" through a small incision over the trochanter.

Since the advent of adequate methods of roentgen study, many types of internal fixation have been used, such as multiple pins and screws, which have maintained position of the fracture until union has taken place. Probably, however, the most generally accepted method at the present time is the Smith-Petersen three flanged nail which gives adequate fixation, prevents rotation of the head, and allows impaction of the fragments, all of which are essential in procuring osseous union. Internal fixation has been used in several series where bony union has been procured in as high as ninety per cent of the cases.

In addition, probably one of the most important factors in procuring union is an accurate reduction, and it was not until lateral roentgenograms were available that we could be certain that the reduction was satisfactory. However, a perfect reduction is not all that is necessary. Immobilization in cases treated by the Whitman method, where it has been shown that a perfect reduction has been obtained, does not give the percentage of good results that are obtained where the Smith-Petersen nail has been employed. Unquestionably, treatment in the cast permits a certain amount of movement at the site of fracture and it must be that this more thorough immobilization with the Smith-Petersen pin, together with the degree of impaction that is obtained, brings about the more satisfactory results.

During the last year, we have used internal fixation in this type of fracture and our results have been most gratifying. By the method that we have adopted, the patient is placed on a fracture table and given avertin anesthesia supplemented with gas and oxygen. The good leg is fixed in flexion at a right angle to a standard attached to the table. This is done to facilitate the making of the lateral roentgenograms during the operation. The fractured hip is then reduced by the Lead-

## CENTRAL OR INTRACAPSULAR FRACTURES OF NECK OF THE FEMUR

better-Whitman method, using the palm heel test to make certain the fracture is completely reduced. The leg is then fixed in slight abduction and full internal rotation to the foot piece of the Hawley table. A lead marker is placed on the skin halfway between the pubis and the anterior superior spine, approximately over the head of the femur. Lateral and anteroposterior roentgenograms are taken to determine if a satisfactory reduction has been made. When this has been accomplished, an incision about three and one-half to four inches long is made on the outer side of the shaft, starting just below the trochanter. The shaft of the femur is exposed and, using the lower ridge of the trochanter as a guide, a small calibrated Steinman pin is inserted into the center of the shaft about one and one-half inches below this ridge. The position of the marker over the head of the femur is determined from the anteroposterior roentgenograms and the pin is directed toward the center of the head and inserted for a distance of about three and one-half inches. With the leg held in internal rotation, the neck of the femur is invariably parallel to the top of the operating table. Any variation from this position can be determined by the preliminary lateral roentgenogram. After the pin is inserted, additional roentgenograms, both anteroposterior and lateral, are taken to determine the position of the pin and, if this is found satisfactory, a Smith-Petersen nail is threaded over or alongside of the wire, depending upon the type of nail used. In some cases, we have nailed the hip without the guide, but it is my impression that there is a definite advantage in its use, as it prevents any tendency for the head of the femur to rotate during the insertion of the nail. The length of the nail that is required can be accurately determined by the length of the calibrated pin that is still protruding from the wound. Final roentgenograms, both anteroposterior and lateral, are taken to check on the position of the nail. When this is satisfactory, the fracture is impacted. A thorough impaction is important to bring the fragments closer together and aid in re-vascularization of the fracture line. It is very important that the direction of the nail be in a position of valgus so that the head fragment sits on the top of the pin. In this way, there will be no shearing force when the patient begins to take weight on the leg and there will be a tendency, if anything, for the head to thread down on the nail and further impact the fracture.

After the wound is closed, a plaster boot is applied, to which a board is fixed so that the foot is maintained in internal rotation.

The postoperative nursing care is quite readily managed as the patient invariably has no pain in the fractured hip. The patient can sit up with a back rest if necessary and can easily be turned and moved in bed for all nursing care. Some workers advocate getting the patient out of bed in a few days but this has seemed a little radical and expecting a little too much of the Smith-Petersen nail. At the end of three weeks,

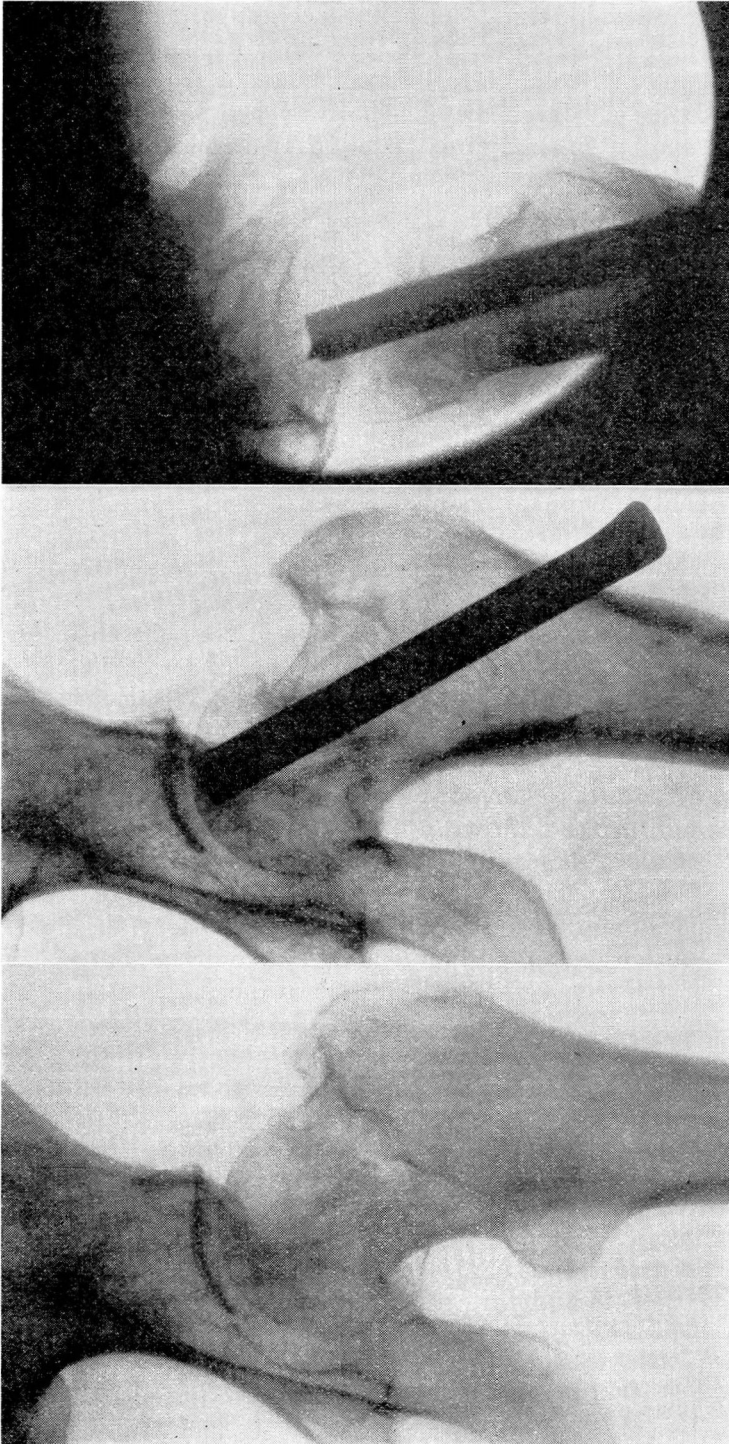


FIGURE 1: Patient 64 years of age.

A. Central fracture of neck of left femur.

B. and C. Anteroposterior and lateral roentgenograms taken 10 weeks after operation, showing nail in position and satisfactory union taking place. The nail was a little too long but this did not give rise to any inconvenience.

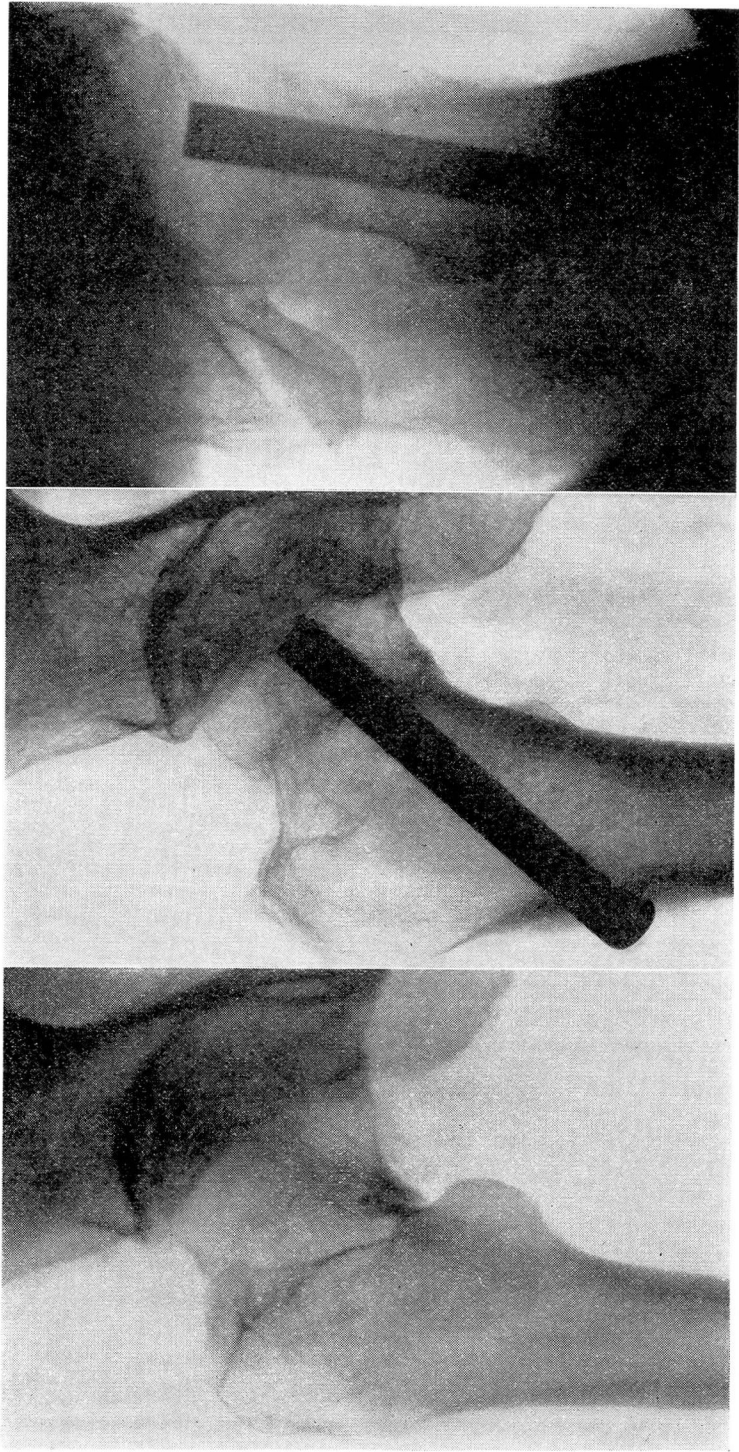


FIGURE 2: Patient 74 years of age.  
A. Central fracture of right hip.  
B. and C. Anteroposterior and lateral roentgenograms taken 6 months after operation, showing position of nail. Excellent union has taken place.

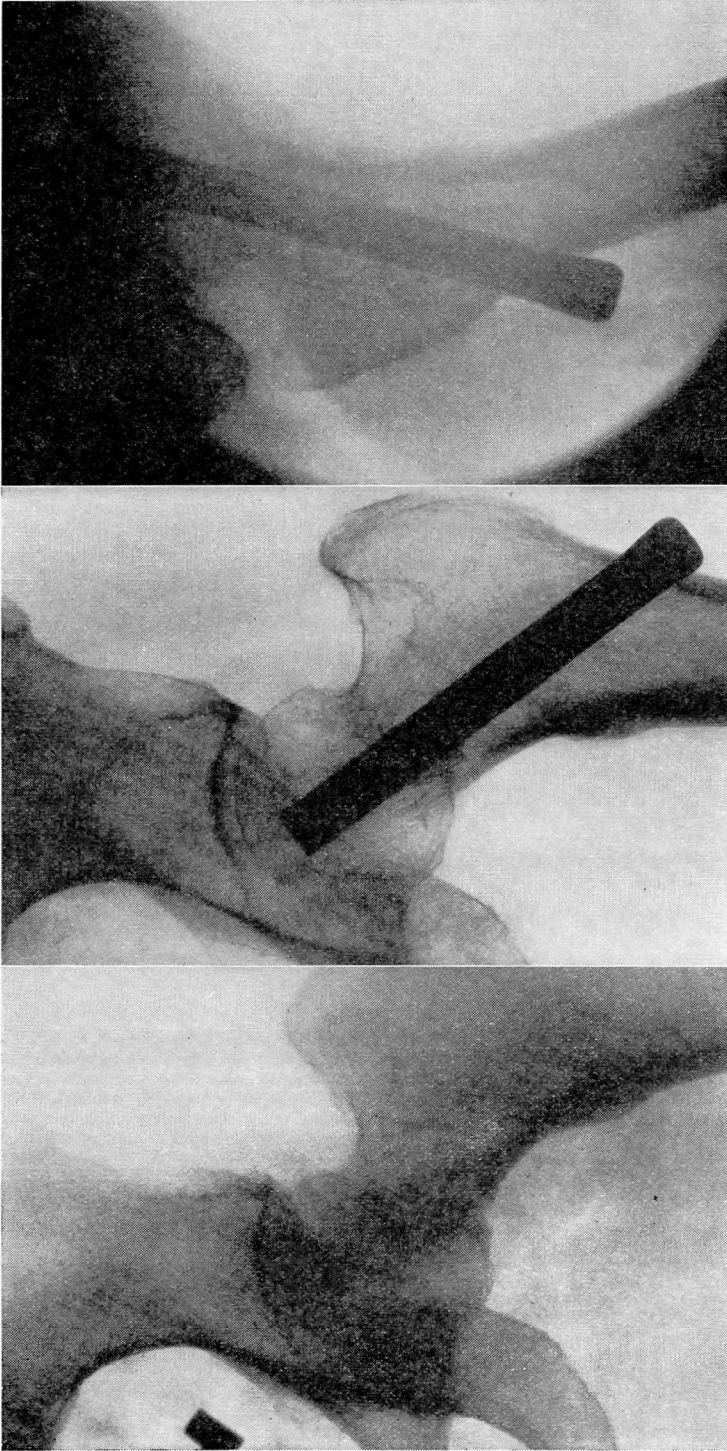


FIGURE 3: Patient 72 years of age.  
A. Reduction of central fracture of neck of left femur with lead skin marker in place, before insertion of calibrated guide.  
B. and C. Anteroposterior and lateral roentgenograms taken 5 months after operation, showing solid union of the fracture.

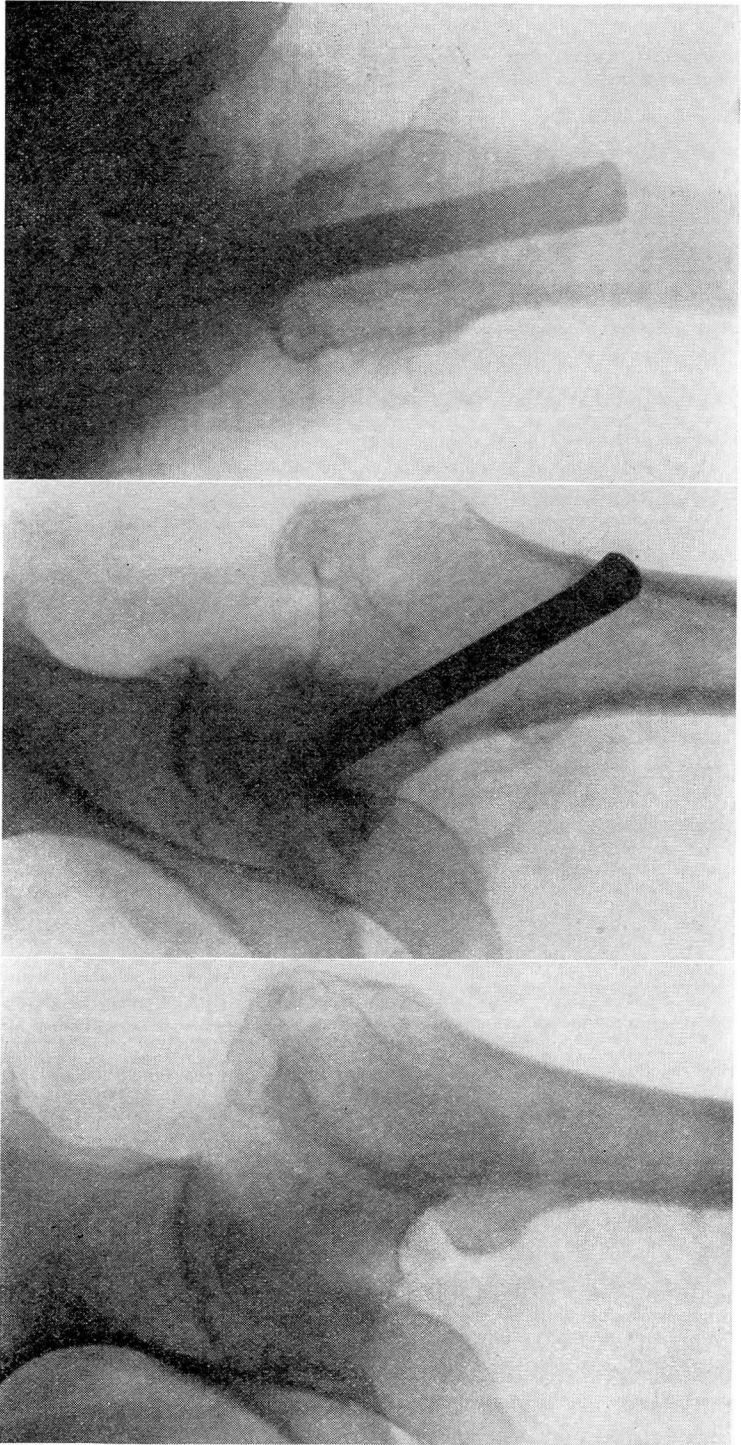


FIGURE 4: Patient 70 years of age.  
A. Central fracture of left femur.  
B. and C. Anteroposterior and lateral roentgenograms taken 7 months after operation, showing pin in position with firm bony union of the fracture.

the plaster boot is removed and the patient is encouraged to start exercises of the quadriceps and to increase voluntary motions of the hip and knee. In the seventh week, the patient is allowed to sit out of bed or over the edge of the bed so that the knee can be exercised. At the end of eight weeks, the patient is encouraged to walk and have weight bearing with the aid of a walker. Activity is increased from this stage, using crutches for a while and gradually discontinuing use of them entirely.

It would appear that satisfactory results from the operation depend upon a good reduction of the hip, the proper insertion of the nail, and thorough impaction of the fracture. It is extremely important that adequate facilities be available to carry out this procedure satisfactorily.

In regard to removal of the nail, this can be very readily done at any time after it is felt that the nail has performed its function and good bony repair has been procured. There would appear to be no urgency about its removal as we have seen no reaction about it and there has been no discomfort from leaving it in position.

During the last twelve months, we have used this method in 18 cases with the most encouraging results and, although it is as yet too early to assess the end results, 12 of the 18 have shown excellent bony union; the other 6 are still under treatment and appear to be healing satisfactorily. In this series, there have been no infections and no fatalities. The age of the patients has ranged from 64 to 80 years, the average age being about 73 years. The roentgenograms in four cases in this series are shown in Figures 1, 2, 3, and 4.

The advantages of the internal fixation over the Whitman abduction method—and these have been borne out in our experiences—would appear to be as follows:

1. There is a lessened mortality rate, due to the fact that complete immobilization is not necessary and the patient is confined to bed a shorter time.
2. There is a definite lessening of the period of hospitalization and cost of nursing care.
3. The patient can be out of bed in a few weeks without danger of dislodging the fragments for, at a certain stage, activity is helpful and weight bearing beneficial in producing an impaction. The position of the pin prevents a dislodgment of the fragments.
4. Stiffness about the involved hip and knee is very seldom seen when internal fixation is used.
5. It is only necessary to follow one or two of the cases to be convinced of the efficacy of this method of treatment. The patients' morale is so much better than when a cast is used. They are perfectly comfortable and can move about in the bed with ease and without pain.
6. The end results are far superior, increasing a fifty per cent chance of union to approximately ninety per cent.