

# DISSEMINATED, SUBCUTANEOUS, GUMMATOUS, ULCER- ATIVE SPOROTRICHOSIS (*S. schenckii-beurmannii*)

## *Report of a Case*

GEO. H. CURTIS, M.D.

Sporotrichosis was first reported in America in 1898, by Schenck<sup>1</sup>, who, with J. E. Smith, isolated the fungus from ulcerative gummatous lesions on the hand and arm and classified it as *Sporotrichum*. In 1912 de Beurmann<sup>2</sup> collected 200 cases from the world literature and published a comprehensive clinical, pathological, and bacteriological study of the disease. Since then many reports have appeared in the literature, among which Meyer<sup>3</sup> in 1915 recorded 82 cases in the United States. In his tabulation, there is one case of human and eight cases of horse infection occurring in Ohio. In 1926 Foerster<sup>4</sup> collected 148 cases, of which 130 occurred in the Mississippi and Missouri River Valleys. North and South Dakota, Wisconsin, Minnesota, Iowa, and Missouri present the greatest frequency of occurrence. Further search through the literature did not reveal additional cases of sporotrichosis reported from the State of Ohio.

Very frequently sporotrichosis is not recognized until it has progressed for many weeks or months. In this case, the diagnosis was made within twenty days after the appearance of the first lesion. Of further interest is the fact that no evidence or history of the portal of entry could be obtained. For these reasons it is believed that a report of this case would be of interest.

## REPORT OF CASE

A white minister, 54 years of age, came to the Clinic on November 3, 1937, with disseminated, subcutaneous nodules and cutaneous ulcers which had been present for fifteen days. The first lesion was noticed on the right hip. Within a few days, other lesions appeared in rapid succession over the entire trunk and extremities, and there was a nodule a little below and behind the right ear. The lesions seemed to appear in crops. The patient thought that he had two different diseases because some of the lesions seemed to be primarily cutaneous while others were much deeper. Within a week after its first appearance, a lesion on the inner side of the left knee had pointed and was lanced. The discharge was purulent and thick. The lesion showed no tendency to heal after a week, but continued to discharge. None of the lesions was tender or painful.

During August, the patient frequently went swimming in a creek and spent some time in his flower garden which did not contain any barberry bushes. His ministerial duties took him to a small church in the country but he did not come in close contact with horses, dogs, cats, etc. In October, about a week or ten days before the appearance of the first nodule, the patient noticed mild stiffness of the muscles and discomfort in the forearm and thighs but this was present only during activity.

The family, personal, and marital history was irrelevant.

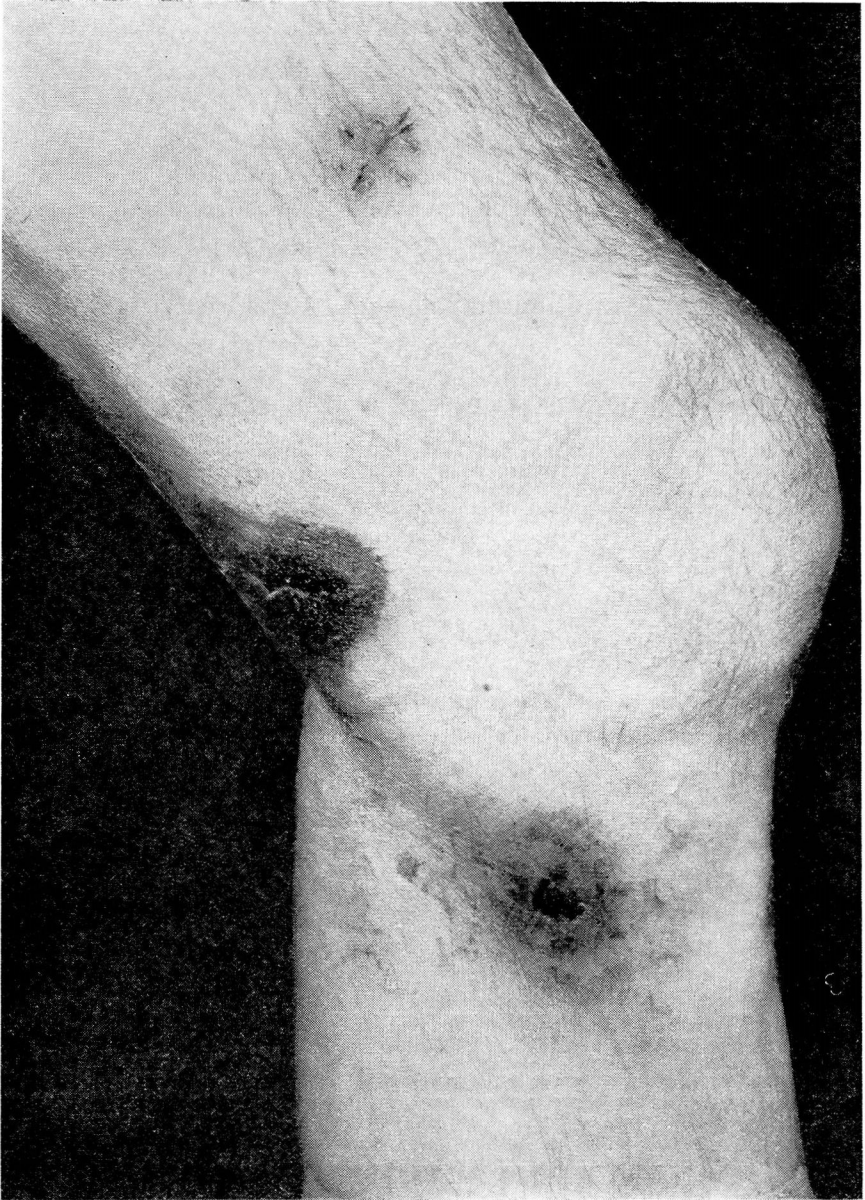


FIGURE 1: A cutaneous ulcer on the medial aspect of the left leg, from which *Sporotrichum* was isolated. The black area at the popliteal space is the site of a biopsy.

Physical examination showed a slender but well developed and well nourished white man of average height. Varicose veins of the legs and the skin lesions were the only abnormalities. A roentgen examination of the chest revealed normal lung fields and old calcified mediastinal nodes.

*Examination of the Skin:* Twenty-four subcutaneous and cutaneous lesions

## SPOROTRICHOSIS

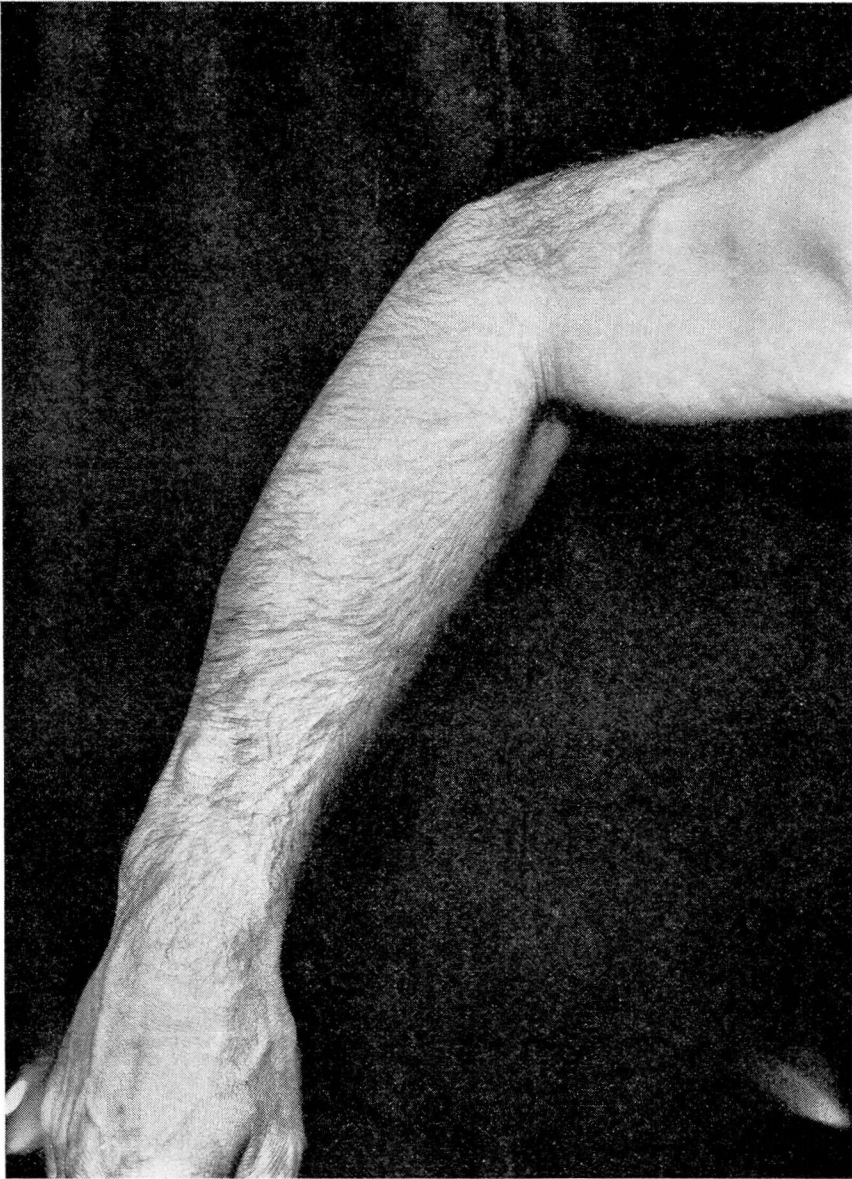

FIGURE 2: Subcutaneous nodules on the extensor surface of the right forearm and arm.

were disseminated bilaterally over the trunk and extremities, and there was one just behind and below the right ear. The subcutaneous nodules varied from the size of a pea to that of an English walnut. Some were freely movable while others seemed to be attached to the underlying fascia, and the epidermis above was normal in texture and color. Many of the nodules were elevated while others could be located only by palpation. The lesions were firm, irregular in shape, and not tender. Three nodules on the dorsum of the right

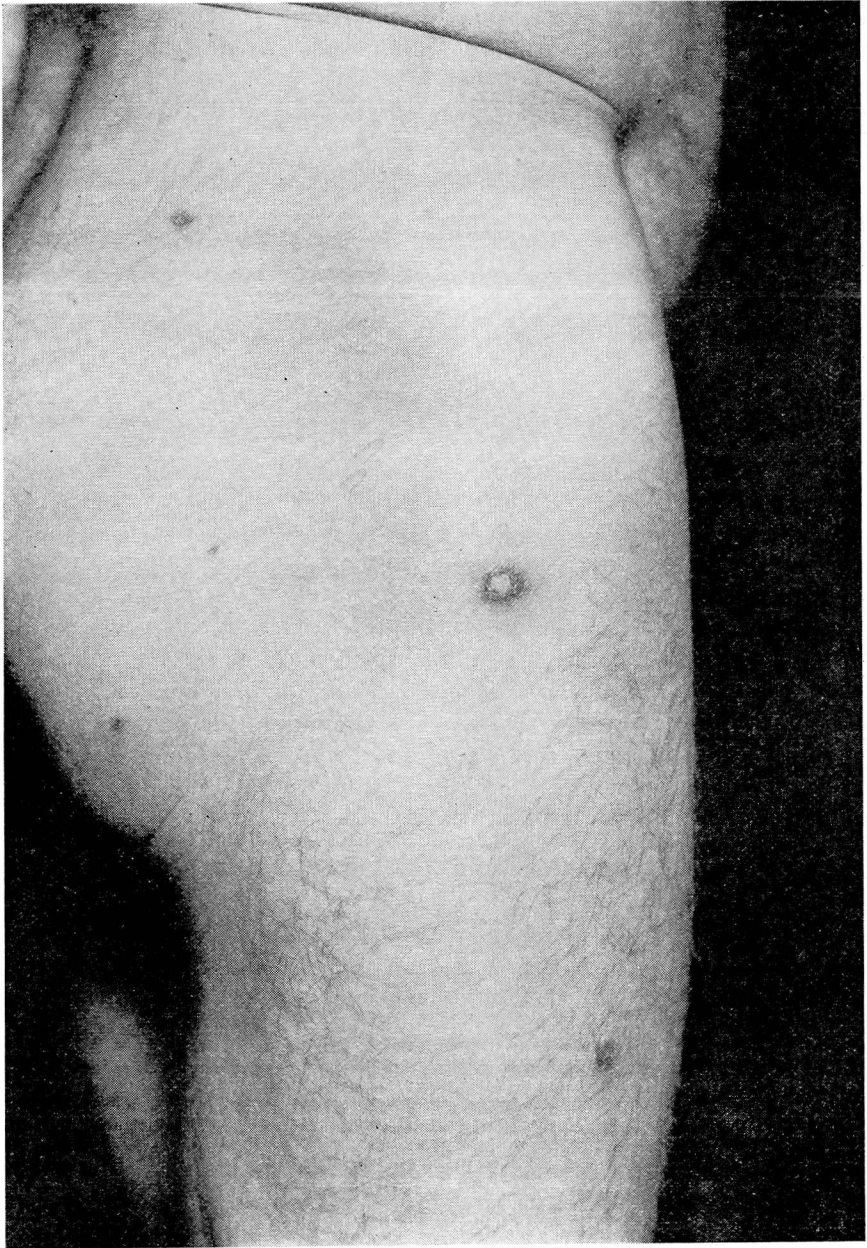


FIGURE 3: Superficial dermo-epidermis, scaling lesions on the right hip.

forearm were arranged in a somewhat linear fashion. Those lesions which involved the epidermis showed various stages of development, from beginning involvement of the epidermis which was of a slight pinkish color, to elevated, fluctuant, and pointing abscesses of a dull bluish-red color. A few of the smallest lesions, primarily involving the dermo-epidermis, were brighter red

## SPOROTRICHOSIS

in color and were covered with a thin crust. Some of these appeared to be involuting. One cystic lesion on the lateral margin of the right foot was slightly tender to palpation. The ulcer on the right knee, which resulted from lancing of the abscess, had a central opening about 0.5 cm. in diameter, leading into a larger cup-shaped cavity. The periphery was indurated and faded imperceptibly into normal tissue as did the discoloration (Figs. 1, 2, and 3).

**Laboratory Examination:** Examination of the blood showed 4,650,000 red cells, 8,250 white cells, and 11 gm. hemoglobin per 100 cc. (71 per cent) with the Haden-Hauser hemoglobinometer. Differential count showed neutrophils, 58 per cent; eosinophils, 5 per cent; lymphocytes, 24 per cent; monocytes, 13 per cent; color index, 0.76; icterus index, 3; and fasting blood sugar 86 mg. per 100 cc. of blood. The urine was normal. The Wassermann and Kahn tests of the blood gave negative reactions. Lumbar puncture revealed normal spinal fluid with negative Wassermann and colloidal gold reactions.

Intradermal tests with old tuberculin in dilutions of 1:10,000 and 1:1,000 gave negative results; dilution of 1:100 gave a weakly positive reaction (erythema 2 cm. in diameter).

Blood taken on four successive days and the spinal fluid were cultured in Sabourraud's medium. The inoculated mediums remained sterile during the observation period of four weeks.

No bacteria or fungi (spores) were found in smears of the pus aspirated from the lesions stained by Gram's, Wright's and Ziehl-Neelsen stains.

Cultures of the pus on Sabourraud's medium showed a growth after four days, as minute mycelia seen only by a hands lens. The following is a description of the mycelial growth.\*

**Description of Growth of *Sporotrichum schenckii-beurmannii*:** Growth appeared on the fourth day as small, moist, flat, grayish-white colonies, less than 1 mm. in diameter. They grew rapidly, soon developing a very fine, downy surface. As their size increased, there developed on the surface near the center a dark, gray-brown pigmentation, and the colony, which until that time had been quite flat, began to show bulging at the center. As growth continued, the pigmentation spread toward the periphery, leaving a smooth, gray or creamy halo surrounding the bulging, dark, crinkled, circular mass. In about ten days, the colony was 3 to 4 mm. in diameter, with a rough, dark surface and a smooth, light-colored edge. In profile, the colony resembled a cone with a decided apex extending two or more millimeters above the surface of the agar slope. At the end of three weeks, the mycelia had become a deep black in the center, while the periphery retained its creamy halo (Fig. 4). Figure 5 is a photomicrograph of the hyphae with conidia.

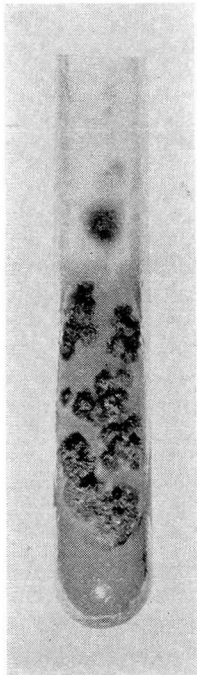

FIGURE 4: A culture tube showing mycelial growth on Sabourraud's media.

Histological examination was made of a pea-sized nodule with beginning abscess formation. The hematoxylin-eosin method was used for staining. The rete pegs of

\*The growth of the organism was followed by Mr. Alfred Reich of our clinical laboratories. The organism was identified as *S. schenckii-beurmannii* by Dr. Morris Moore, mycologist to the Barnard Free Skin and Cancer Hospital, St. Louis, Mo.

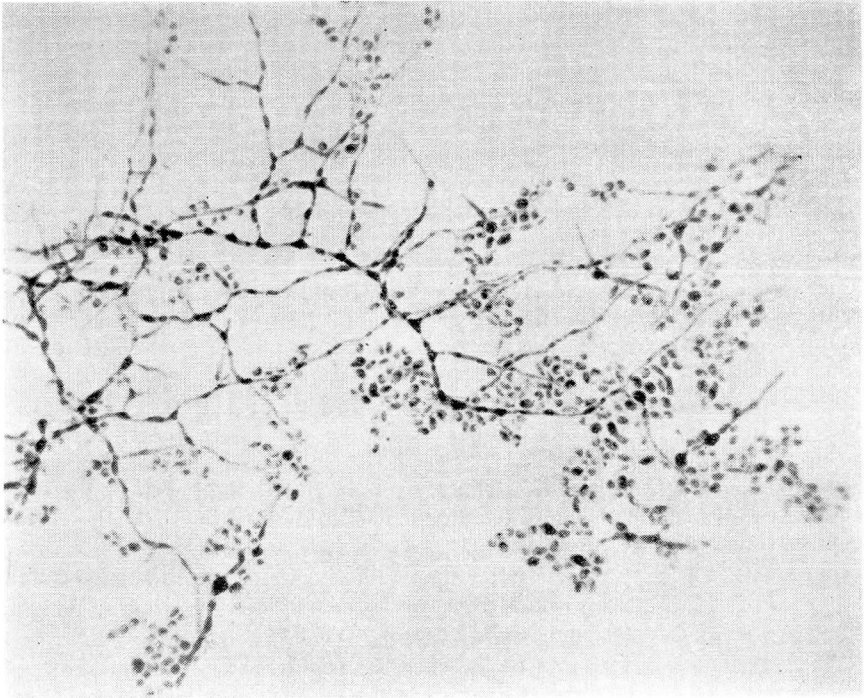


FIGURE 5: Photomicrograph of the hyphae showing the pear-shaped conidia situated along the sides and ends.

the epidermis directly above the abscess are somewhat elongated. A few mononuclear and polymorphonuclear cells are disseminated throughout the pickle cell layer. The horny layer appears normal. About the rete pegs and in the papillae is a moderate intercellular edema, mainly situated about dilated capillaries and arterioles. There is moderate infiltration in the papillae and upper corium, especially about the blood vessels, and this is composed of predominating mononuclear cells, a lesser number of polymorphonuclear cells, an occasional plasma cell, and a few scattered eosinophils. Toward the abscess, the infiltrate becomes more dense, the perivascular "cupping" more intense, and it dissects apart the connective tissue in large sheets along the vascular network. There is no tendency to encapsulation. Capillary proliferation may be seen in the peripheral and middle zones.

Roughly, a middle zone may be seen to be composed of a moderate proliferation of fixed tissue cells of epithelioid type. In one area there are two giant cells of the Langerhans type, but there is no definite tubercle formation.

Centrally, the edema and cellular infiltration, necrosis, and cellular debris are very marked. This is surrounded by frayed-out strands of connective tissue, the free ends of which show disintegration and necrosis. Several disintegrating coil glands are caught in the mass. The infiltrate is almost entirely made up of polymorphonuclear cells and their debris and a large number of eosinophils.

The histological picture is that of a granulomatous process involving the skin and subcutaneous tissue, with early abscess formation, combining the features of syphilis and tuberculosis to a moderate degree.

## SPOROTRICHOSIS

*Course:* At no time during the onset and course of the disease has the patient showed any toxic symptoms except for the mild aching of the muscles of the extremities. As soon as the diagnosis was confirmed by culture of the organism, the patient was given a saturated solution of potassium iodide by mouth, beginning with one gram daily in divided doses and rapidly increasing the dose to four grams daily. The patient tolerated four grams a day very well. The ulcerations and lesions that discharged through the openings made by the aspiration needle were dressed daily with a 5 per cent iodine ointment. Within a week after treatment was begun, a definite healing of the ulcers and involution of the subcutaneous nodules was in progress. After a month, the lesions had practically disappeared and no new ones had appeared. Treatment is to be continued for a month or six weeks after all signs of the lesions have disappeared.

### DIAGNOSIS

Since the diagnosis in this case was made and treatment was started early in the course of the disease, the differential diagnosis was limited to four possible conditions: Pyogenic infection, syphilis, tuberculosis (tuberculosis colliquativa), and other mycotic infections.

The principal features in the differential diagnosis suggested in this case may be listed in the following manner:

1. The appearance of bilaterally disseminated subcutaneous and cutaneous lesions in rapid succession, suggesting a hematogenous distribution in a healthy person.
2. Absence of a history of previous infection or portal of entry.
3. Indolent evolution of the lesions with minimal inflammatory signs and symptoms simulating cold abscesses.
4. Normal hemogram except for the 5 per cent eosinophilia.
5. Repeatedly negative blood Wassermann and Kahn reactions.
6. Repeatedly negative blood cultures.
7. Negative tuberculin test except in strong concentration.
8. Absence of pyogenic organisms in smears and cultures of the pus.
9. Guinea pig inoculation negative for tubercle bacillus.
10. Abundant growth of *Sporotrichum* from the pus on Sabourraud's medium.

In furunculosis, the lesions have a predilection for the back of the neck, axillae, groins, inside of the thighs, and buttocks. Although subcutaneous and cutaneous, the lesions usually mature rapidly and present all the signs of acute inflammation, point, and discharge within a week. If "blind" boils occur, the pain and tenderness, color and evolution are more prominent than in sporotrichotic lesions. *Staphylococcus albus* is almost always present in smears and cultures. A furuncle usually presents a core that is not present in sporotrichotic

lesions. The regional adenopathy of furunculosis is rare in sporotrichosis.

Pyemia is a much more serious disease which usually follows a previous infection such as thrombophlebitis, pneumonia, infections of the upper respiratory and accessory respiratory tract and presents symptoms of toxemia and signs of septicemia. The causative organism is usually recovered from the blood stream and cutaneous abscesses. Moderate to severe anemia and leukopenia are usually manifested but with a marked increase in the number of polymorphonuclear leukocytes. Eosinophilia is extremely rare. The evolution of the cutaneous abscesses is similar to that of furunculosis.

Due to the fact that the diagnosis was made early in this case, there was only a superficial resemblance to the late lesions of syphilis, i.e., nodular cutaneous, and gummatous syphiloderm. There was no history of previous syphilitic infection in the patient. The Wassermann and Kahn tests gave negative reactions and remained so even after a month of administration of potassium iodide. The lesions of syphilis tend to be localized by trauma to the scalp, face, elbows, buttocks, and legs and are asymmetrical and very rarely disseminated. These lesions tend to ulcerate and enlarge by peripheral occurrence of new nodules forming serpiginous, scalloped, horseshoe or letter S patterns with a dull red or "ham" color and punched-out edges. This evolution usually occupies a period of months while the sporotrichotic gumma evolves in a matter of weeks. The ulcers of the latter disease are "crater" or cup-shaped with overhanging edges, of a brighter red or more livid color, and do not tend to enlarge. If the syphilitic lesions are situated over or involve a nerve trunk or nonelastic site, there is a tendency to pain of varying degree, while lesions of sporotrichosis are usually not as painful, if situated in similar locations.

This form of sporotrichosis resembles scrofulous gummata (tuberculosis colliquativa) more closely than any other scrofulous form of cutaneous tuberculosis, more specifically the very rare disseminated type of subcutaneous tuberculosis colliquativa. Children are more frequently affected than adults and a focus from which hematogenous dissemination occurs is usually found. In adults, the sites of predilection are the face, neck, areas over bony projections and epiphyseal regions, although lesions may occur anywhere in the subcutaneous tissue. The evolution of the gumma requires several months before it reaches the skin and ulcerates. The lesions are often painful and the overlying skin is of livid red or purplish color. The center shows signs of regression while, at the periphery, the inflammatory zone is more prominent. The edges are thin, frayed out, undermined, and irregular in outline. The base is dirty and granular, and the discharge is purulent and thin.



## SPOROTRICHOSIS

Tests of the skin with tuberculin usually give strongly positive reactions and in most instances tubercle bacilli are demonstrated in smears or by guinea pig inoculation. Histologically, the usual picture of tubercles is almost always in evidence.

The chief mycoses, occurring in the Middle West, that must be differentiated from sporotrichosis are actinomycosis and blastomycosis. First and most important, these are differentiated by finding the organisms in smears and on culture. The finding of the sulphur granules in the discharge establishes the diagnosis of actinomycosis, while the presence of budding, double-contoured, yeast-like organisms in the tissues and pus designates blastomycosis. *Sporotrichum* is rarely and most difficulty found in the pus, while luxuriant growth on culture is the rule. In blastomycosis and actinomycosis, the multiple subcutaneous and cutaneous lesions are secondary to a primary focus of systemic or visceral origin. Their evolution is more rapid than that of sporotrichotic lesions, and the individual lesions enlarge by peripheral extension of miliary abscesses.

### GENERAL CONSIDERATIONS

*Etiologic and Mycological Aspects:* Sporotrichosis is a subacute or chronic disease due to the vegetable fungus of the genus *Sporotrichum*. The disease is primarily a cutaneous and subcutaneous infection but it may be systemic as no organ or tissue is immune. The principal organism producing human infection is *S. schenckii-beurmannii*. The description given elsewhere is brief but may be found in more detail in special articles<sup>5,6</sup>. The organism is best grown on Sabourraud's medium consisting of peptone 1 per cent, glucose 4 per cent, agar 1.5 per cent, distilled water 100.0 cc. The pus aspirated from the abscesses under aseptic conditions is inoculated into the media and growth appears in from 4 to 10 days.

Infection in humans may occur by inoculation of the spores on vegetable matter and plants into a wound or abrasion or from animals, fur, bites, etc., and may be transmitted from man to man by direct contact with the pus or vectors.

*Clinical types of the disease:* The disease may be divided into the following four types:

1. **Localized lymphangitic:** This is the most commonly encountered type in America and is characterized by an initial infection through trauma on the exposed parts, usually the hands, which is the sporotrichotic chancre. From a few days to several weeks following the appearance of the chancre, the disease extends along the regional lymphatics with formation of thickened vessels and subcutaneous gummas which ulcerate.

2. Disseminated, subcutaneous, gummatous type: This variety is most frequently met with in France and is manifested by disseminated, painless, subcutaneous nodules that evolute to involve the skin in from 3 to 6 weeks. In the untreated patient, new lesions continue to appear indefinitely. These lesions rarely ulcerate spontaneously unless traumatized.

3. Disseminated ulcerative: The lesions of this type evolute as in the preceding variety but primarily involve the skin and ulcerate spontaneously. Types 2 and 3 most often resemble syphilis and tuberculosis.

The case presented in this report represents a combination of the preceding two forms as noted by the presence of deep subcutaneous nodules and superficial dermo-epidermic nodules and ulcerations. Hematogenous dissemination has not been demonstrated in these types.

4. Systemic: In this type, there may be involvement of the mucous membranes of the upper alimentary and respiratory tracts, the muscles and glands, the bones and joints, especially the tibia, epididymis, lungs, gastro-intestinal tract, and cerebrospinal system. The symptomatology is governed by the various systems involved.

#### TREATMENT

Potassium iodide is practically specific for the disease. It is usually administered orally as a saturated solution. The dosage begins with 15 drops daily and rapidly ascends to tolerance and continues at a dosage just below tolerance for about six weeks after all visible clinical signs of the disease have subsided. If intolerance to oral administration occurs, iodine in the form of Lugol's solution, tincture of iodine, or sodium iodide may be given orally, intravenously, or by rectum. When given orally, tolerance may be materially enhanced by small doses of tincture of belladonna.

Local treatment of the abscesses and ulcerations consists of daily irrigation with Lugol's solution, moist compresses, or ointments containing iodine up to 5 per cent. Surgery is usually contraindicated. Superficial roentgen therapy hastens the involution and absorption of the subcutaneous and cutaneous lesions.

#### SUMMARY

A case of disseminated, subcutaneous, gummatous, ulcerative sporotrichosis is reported. It is believed that this is the second case of human infection reported in the literature as occurring in Ohio. The first case was reported in 1911 and recorded by Meyer<sup>3</sup> in 1915. The diagnosis in our case was suspected within 15 days and confirmed by culture within 20 days after the appearance of the first lesion. The disease responded rapidly to treatment with potassium iodide and,

## SPOROTRICHOSIS

although the elapsed time is too short to determine the ultimate course of the disease, it is felt that a permanent cure will be obtained.

### REFERENCES

1. Schenck, B. R.: On refractory subcutaneous abscesses caused by fungus, possibly related to the sporotricha, Johns Hopkins Hosp. Bull., 9:286-290, 1898.
2. de Beurmann, L.: On sporotrichosis, Brit. M. J., 2:289-296, (July-December) 1912.
3. Meyer, K. F.: The relation of animal to human sporotrichosis; studies on American Sporotrichosis III, J.A.M.A., 65:579-585, (August 14) 1915.
4. Foerster, H. R.: Sporotrichosis; an occupational dermatosis, J.A.M.A., 87:1605-1609, (November 13) 1926.
5. Jacobson, H. P.: Fungous Diseases; a Clinicomycological Text, Springfield, Ill., Charles C. Thomas, 1932.
6. Lawless, T. K.: The diagnosis of sporotrichosis, Arch. Dermat. & Syph., 22:381-388, (September) 1930.