

TREATMENT OF UNUNITED FRACTURES OF THE NECK OF THE FEMUR

Report of Two Cases

JAMES A. DICKSON, M.D.

I have previously reported our experience and the results we have secured in the treatment of fresh fractures of the neck of the femur, pointing out the advantages of the use of the Smith-Petersen nail¹. At this time I wish to draw attention to two cases of nonunion of the neck of the femur treated by means of bone grafts and the Smith-Petersen nail because they exemplify the excellent results that can be anticipated from this method.

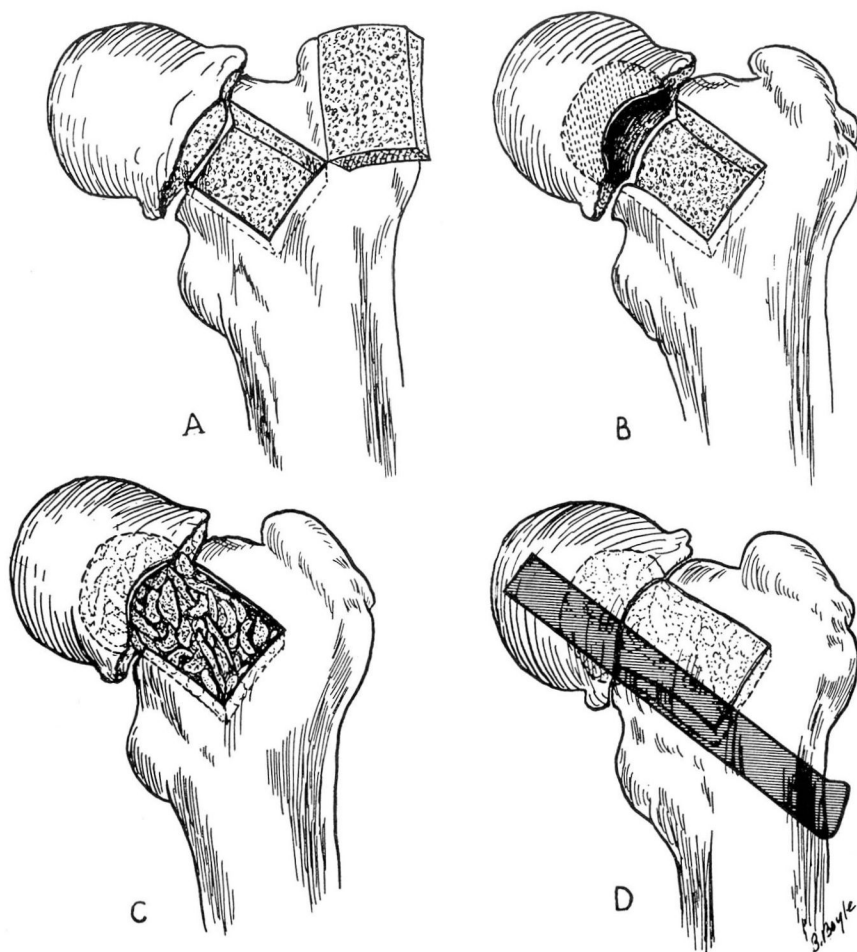


FIGURE 1: A, B, C and D: Drawings showing steps in operation by use of grafts of bone chips and Smith-Petersen nail.

The following is a brief resumé of the operation that was used in these two cases.

The neck of the femur was exposed by the usual Smith-Petersen incision, the fracture was explored, and any necessary improvement in position was carried out. A window was made in the front of the neck of the femur (Fig. 1A) to facilitate the curettement and removal of all the scar and fibrous tissue from the fractured ends of the bone. This curettement was carried up into the head of the bone (Fig. 1B). Through this window, the cavity so formed was thoroughly packed with bone chips procured from the tibia or the crest of the ilium (Fig. 1C) and the window was replaced. A guide wire was then inserted as in an acute fracture and when a satisfactory position was obtained and confirmed by roentgen examination, a Smith-Petersen nail was driven over the guide wire and the fracture thoroughly impacted (Fig. 1D).

The results have been so gratifying that I feel confident that the use of grafts and fixation with the three flanged nail are going to be of great value in the treatment of these fractures which have proved so disappointing in the past when only medullary grafts were used.

REPORT OF CASES

Case 1: The patient was a woman, 65 years of age, who in April, 1936, received a central fracture of the neck of the left femur. This was treated by means of a Steinmann pin through the lower end of the left femur and traction which was continued for a period of twelve weeks. Union did not take place and when she came under my care May 9, 1938, she was having a great deal of pain and the fracture had not united (Fig. 2).

On June 1, 1938, more than two years after the time of the original fracture, the open reduction was carried out. Under avertin and gas anesthesia, the hip joint was exposed, using the Smith-Petersen approach. The surfaces of the fracture were then freshened, removing all the old scar tissue and the cavity was packed with bone chips according to the technic described previously. The fragments were nailed into position and impacted with a Smith-Petersen pin.

The postoperative treatment was practically the same as is used in the management of acute central fractures of the neck of the femur except that this patient was given a longer period of bed rest before weight bearing was permitted. She was not allowed up in her walker until after the eighth week.

Figure 3 shows firm, bony union at the end of twelve weeks.

Case 2: This patient, a woman 66 years of age, received a comminuted intertrochanter fracture of the neck of the left femur in November, 1936. She was first treated in a cast, and roentgenograms taken

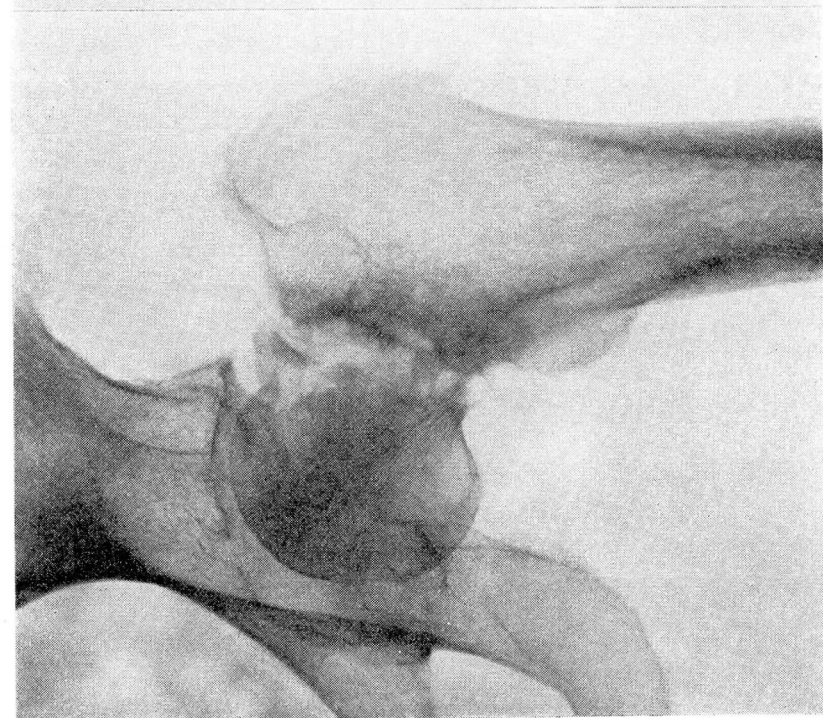


FIGURE 2: Case 1. Roentgenogram showing ununited fracture before operation.

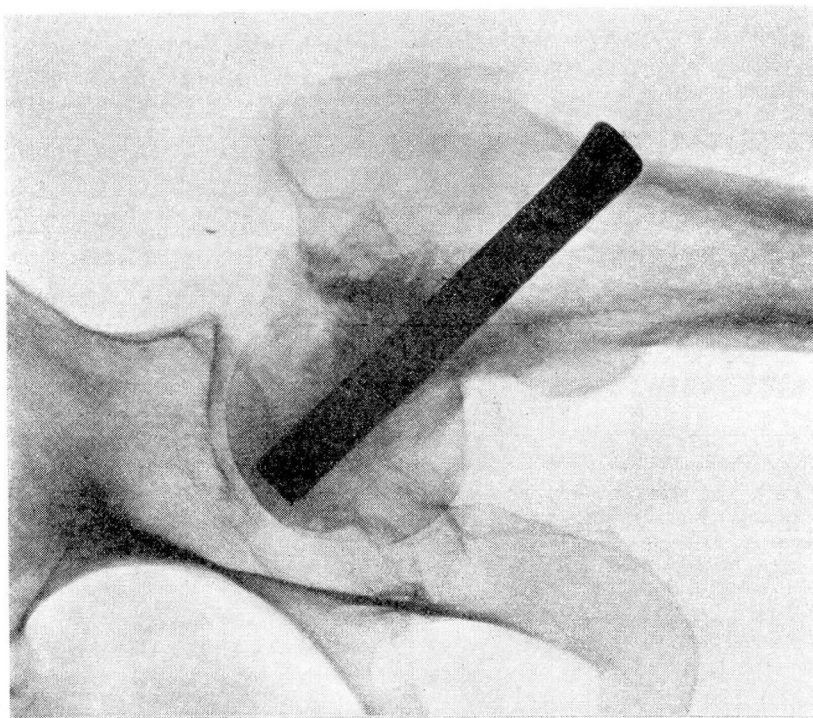


FIGURE 3: Case 1. Roentgenogram showing result 12 weeks after operation.

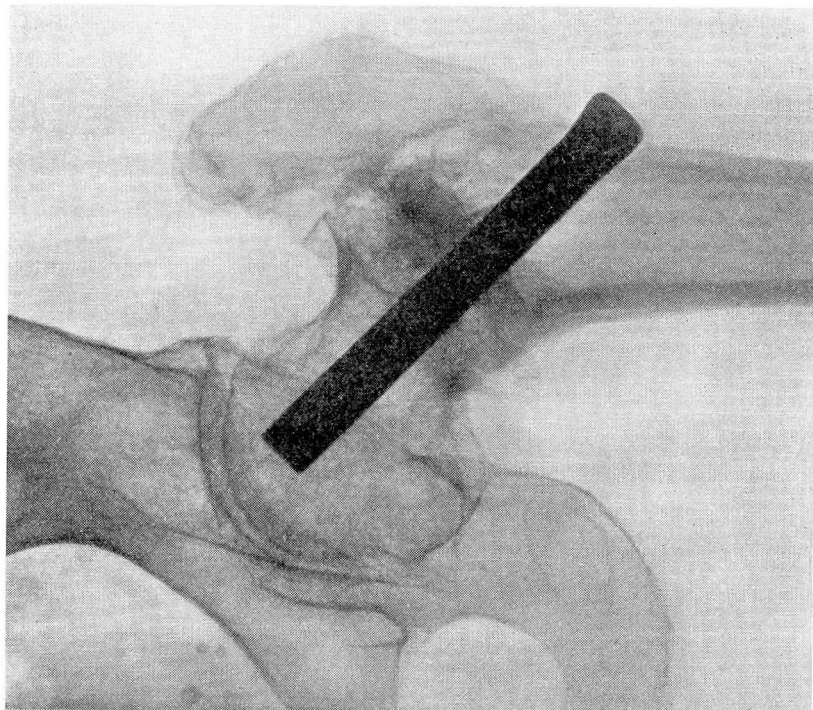


FIGURE 5: Case 2. Roentgenogram showing result 12 weeks after operation.

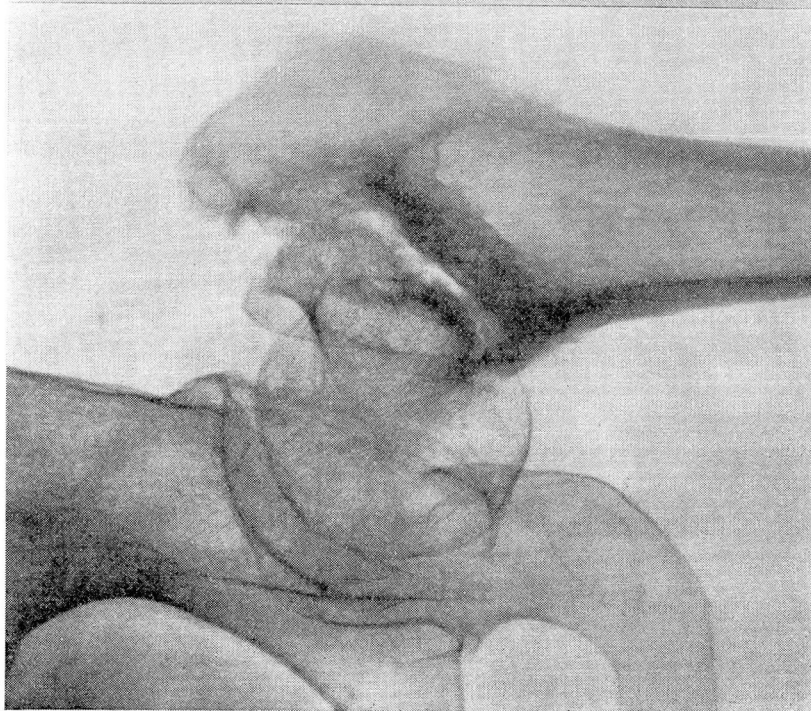


FIGURE 4: Case 2. Roentgenogram showing ununited fracture before operation.

TREATMENT OF UNUNITED FRACTURES OF THE NECK OF THE FEMUR

at that time showed that fairly satisfactory reduction was obtained. The cast was kept on for twelve weeks after which she wore a Thomas walking caliper. Ultimately, however, a marked coxa vara with nonunion developed. The nonunion persisted and when she came under my care on April 9, 1938—18 months after the fracture had occurred—there was considerable backward angulation and displacement at the site of the fracture, with nonunion (Fig. 4).

On June 2, under avertin and gas anesthesia, an open operation for reduction of the fracture was carried out. The surface of the fracture were freshened, bone chips were inserted, and the fracture was secured by means of a Smith-Petersen nail. Due to the fact that this was an intertrochanteric fracture it was felt advisable to give the added protection of a cast. Convalescence was uneventful.

Figure 5 shows the result at the end of twelve weeks. The fracture is well healed with excellent bony union and good position.

COMMENT

These two cases demonstrate the possibilities in the treatment of ununited fractures of the neck of the femur. A most important factor is the early recognition of a developing nonunion as better results can be secured in cases in which operation is performed before extensive atrophy of the bone has occurred. In cases suitable for this treatment it is obvious that the end results would be much superior to the various reconstruction operations that have been used in the past. I feel confident that if this procedure were used in those cases where it is evident that nonunion is developing, much time, pain, and disability might be saved the patient. In the cases shown, it is apparent that at least a year to a year and a half of disability might have been saved these patients if operation had been performed earlier. This type of operation, preferably done early in a beginning nonunion, will also lessen the number of reconstruction operative procedures necessary to obtain stable functioning hips.

REFERENCE

1. Dickson, James A.: Treatment of central or intracapsular fractures of the neck of the femur, *Cleveland Clin. Quart.*, 5:41-48, (January) 1938.