

## Dermatology Feature

Kenneth J. Tomecki, M.D.,  
Section Editor

# Angiosarcoma of the face: report of a case

L. Stephen Kish, M.D.<sup>1</sup>  
Kenneth J. Tomecki, M.D.<sup>1</sup>  
Wilma F. Bergfeld, M.D.<sup>2</sup>

**A 78-year-old man with a one-year history of facial swelling had histologically proved angiosarcoma of the face, an uncommon, aggressive malignancy of the skin. Physicians should be aware of this tumor and its presentation.**

**Index terms:** Angiosarcoma • Skin, neoplasms  
**Cleve Clin Q** 50:38-40, Spring 1983

Angiosarcoma (synonyms: angioendothelioma, hemangioendothelioma, hemangiosarcoma, lymph-angiosarcoma) is an uncommon, aggressive neoplasm. In this report we describe a man whose primary complaint at the time of evaluation was chronic, progressive facial swelling.

### Case report

A 78-year-old white man was in good health until December 1980, when an asymptomatic small nodule developed on the left cheek that was initially diagnosed as a cyst. By March 1981, the "cyst" had enlarged and new smaller nodules appeared on the right side of the face and around the mouth. For the provisional diagnosis of "hives" and "sclerodermoid changes," he received topical and systemic steroids without improvement. He was then referred to The Cleveland Clinic Foundation where he was first seen in November 1981. There were no apparent associated or predisposing factors and there was no personal or familial history of any other or similar skin disease. The rest of the patient's medical history was unremarkable.

Physical examination revealed an elderly man in no apparent distress with discrete and confluent, poorly demarcated, red to purple, hardened (woody) plaques that infiltrated the entire face, with prominence around the periorbital areas and nose.

<sup>1</sup> Department of Dermatology.

<sup>2</sup> Departments of Dermatology and Pathology.

Submitted for publication in November 1982; accepted in December 1982.

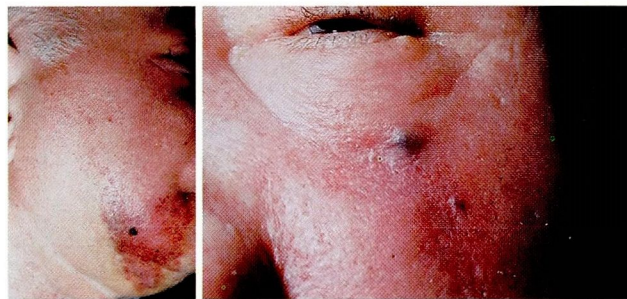Two dark papules were present within the plaques on both cheeks (*Figs. 1 and 2*). The infiltration prevented optimal opening of the eyes and mouth. The remainder of the physical examination, including that of the lymph glands, was unremarkable. Laboratory data, including complete blood count with differential, serologic test for syphilis, SMA-18 chemistry profile, and urinalysis, were either negative or normal. Chest roentgenogram and electrocardiogram were normal.

Microscopic examination of the darkly pigmented papules and plaques on the cheek demonstrated a diffuse nodular replacement of the dermis and subcutaneous tissue by an extensive proliferation of anastomosing dilated vascular channels lined by plump cuboidal, pleomorphic endothelial cells. Other areas contained confluent sheets of cuboidal to polygonal cells characterized by large hyperchromatic nuclei with prominent nucleoli and abundant cytoplasm (*Figs. 3 and 4*).

Palliative chemotherapy with doxorubicin, cyclophosphamide, vincristine, and dacarbazine was unsuccessful, and the man died three months later. There was no autopsy.

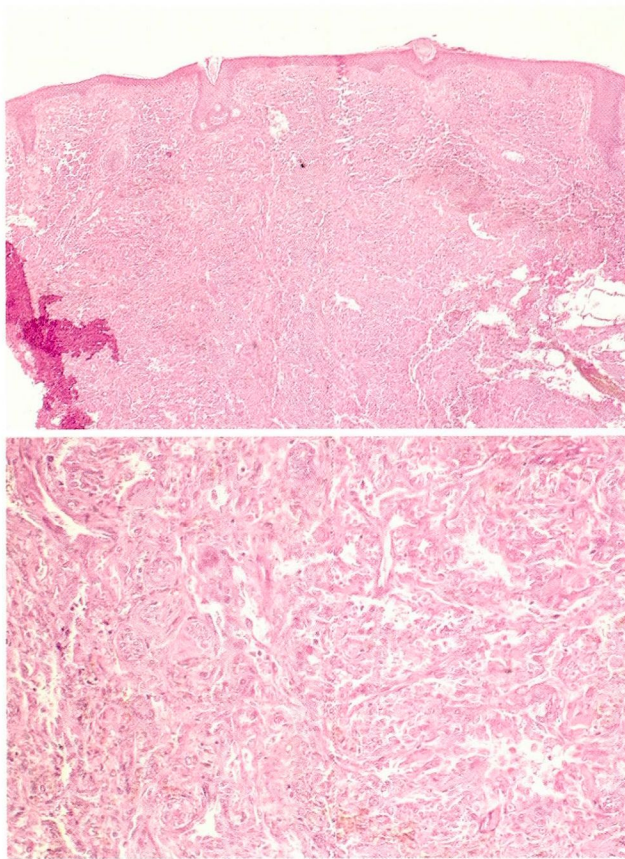
### Comment

The history of progressive facial swelling in an elderly man with the presence of poorly demarcated, indurated, vascular plaques on the head established the diagnosis of angiosarcoma in our patient; micro-



**Figure 1.** Poorly demarcated, purple plaque with dark papule on right jawline.

**Figure 2.** Close-up of papules and plaque on left cheek.



**Figure 3.** Angiosarcoma. Diffuse, nodular endothelial proliferation is seen (magnification,  $\times 10$ ).

**Figure 4.** Angiosarcoma. Note extensive proliferation of anastomosing, dilated vascular channels lined by atypical endothelial cells (magnification,  $\times 40$ ).

scopic examination of the skin biopsy specimen confirmed the diagnosis.

Angiosarcoma is an uncommon, highly malignant tumor of endothelial origin, which may arise in any organ of the body, but more frequently in mammary glands, liver, bones, striated muscles, and skin. It is more common in men (2:1 ratio) without racial predilection. It affects persons of all ages, but more commonly occurs in the elderly with the head as the most common site. There are no known predisposing factors, and sunlight and trauma are probably non-contributory.<sup>1</sup> Livingston and Klemperer<sup>2</sup> reported the first case of cutaneous angiosarcoma in 1926. Others have provided extensive reviews of the subject.<sup>1, 3-5</sup>

Cutaneous angiosarcoma of the head and neck usually presents as a nodule or localized swelling on the scalp or hairline. Initial symptoms are nonspecific and significant discomfort usually develops after the tumor is well established. The tumor insidiously evolves into ill-defined, often multicentric,

indurated, flesh-colored or violaceous nodules and plaques. The accurate diagnosis of angiosarcoma may escape detection for one or two years by which time most tumors measure 5 cm or more in diameter.<sup>1</sup> Common erroneous diagnoses for a developing angiosarcoma include urticaria/angioedema and/or bacterial or fungal infection.<sup>1,5</sup>

The classic histology of angiosarcoma usually reveals the presence of anastomosing vascular channels lined by pleomorphic endothelial cells. With the presence of large confluent sheets of tumor cells and few vascular channels, histologic diagnosis may be difficult without the use of electron microscopy and immunohistochemistry. Immunohistochemical staining for factor VIII-related antigen, an endothelial marker, has been used by Burgdorf et al<sup>6</sup> to identify malignant endothelial cells in well-differentiated portions of the neoplasm.

The prognosis of cutaneous angiosarcoma of the head and neck is poor. Only 2 of 13 patients described by Hodgkinson et al<sup>5</sup> survived more than five years; 6 died within one year after diagnosis. Of 17 cases reported by Maddox and Evans,<sup>1</sup> only 2 patients survived more than five years; 9 died within 18 months after diagnosis. Delayed presentation of the patient to the physician, misdiagnosis, reluctance to biopsy suspicious areas, frequent local recurrence after surgical excision, and early metastases (both lymphatic and hematogenous to lymph glands, lung, and liver) contribute to the high mortality of this tumor. Recommended therapy for angiosarcoma at this time is complete surgical resection when possible.<sup>1,5</sup> Although conclusive data do not exist for the evaluation of adjunctive radiation therapy and chemotherapy, Hodgkinson et al<sup>5</sup> recommend wide-excision removal of primary tumor with lymph node resection followed by wide, high-dose radiation therapy to the primary site and neck (if cervical nodes are involved). For palliation, radiation (x-ray or electron beam) and/or chemotherapy may be helpful.<sup>1,5</sup>

Although angiosarcoma is rare, the physician should include this neoplasm in the differential diagnosis of chronic facial swelling. Early diagnosis of this tumor and prompt surgical resection, if possible, are critical and may provide the best opportunity for successful therapy.

## References

1. Maddox JC, Evans HL. Angiosarcoma of the skin and soft tissue. *Cancer* 1981; **48**:1907-1921.
2. Livingston SF, Klemperer P. Malignant angiomas; with reference to the question of sarcoma due to roentgen ray. *Arch Pathol* 1926; **1**:899-910.

3. Knight TE, Robinson HM Jr, Sina B. Angiosarcoma (angioendothelioma) of the scalp; an unusual case of scarring alopecia. *Arch Dermatol* 1980; **116**:683-686.
4. Rosai J, Sumner HW, Kostianovsky M, Perez-Mesa C. Angiosarcoma of the skin; a clinicopathologic and fine structural study. *Hum Pathol* 1976; **7**:83-109.
5. Hodgkinson DJ, Soule EH, Woods JE. Cutaneous angiosarcoma of the head and neck. *Cancer* 1979; **44**:1106-1113.
6. Burgdorf WHC, Mukai K, Rosai J. Immunohistochemical identification of factor VIII-related antigen in endothelial cells of cutaneous lesions of alleged vascular nature. *Am J Clin Pathol* 1981; **75**:167-171.