

Mitral annulus calcification: clinical implications¹

Marcello Mellino, M.D.²
Ernesto E. Salcedo, M.D.

M-mode echocardiographic features of 53 patients with mitral annulus calcification (MAC) are presented with an initial clinical analysis. Direct measurement of the thickness of the calcification is described as a new technique to define the severity of this process, possibly with a prognostic value as well. Moderate to severe degree of MAC (>5 mm average thickness) was found in 69.7% of patients, all without history of rheumatic heart involvement, and only one had chronic renal failure. Detailed electrocardiographic observations showed the presence of conduction disturbances in 53.6%; 6 patients with 3° atrioventricular block and 3 with sick sinus syndrome and widespread conduction disturbances required permanent pacemaker. Electrophysiologic study of 7 patients demonstrated a significant prevalence of involvement of the conduction system below the proximal His bundle, the region more directly in contact with the calcified annulus. We believe that this quantitative method of evaluating patients with MAC is of value for noninvasive, more complete clinical study of this disease.

Index terms: Mitral valve, calcification • Mitral valve, ultrasound studies
Cleve Clin Q 50:6-10, Spring 1983

Several clinical and echocardiographic studies have demonstrated a significant prevalence of mitral annulus calcification (MAC) in patients more than 60 years of age.¹⁻⁷ This degenerative nonrheumatic process may have important clinical implications, being in close contiguity with the atrioventricular (AV) node and the His bundle system. The "sphincter action" of the mitral annulus necessary to prevent functional insufficiency of the mitral valve structure can be affected as well^{3,6} with variable degrees of mitral regurgitation, and left ventricular and left atrial enlargement.⁵ In this study we have

¹ Department of Cardiology, The Cleveland Clinic Foundation. Submitted for publication in February 1982; revision accepted December 1982.

² Present address: 2609 Franklin Blvd., Cleveland, OH 44113.

retrospectively reviewed 53 cases of MAC diagnosed by M-mode echocardiography; their clinical and electrocardiographic findings are presented, and some echocardiographic features are discussed.

We also present electrophysiologic data in a group of patients with symptomatic conduction problems. Although such data are derived from a small and highly selected group, we believe that patients with MAC and symptomatic conduction problems often need pacemakers because of direct damage of the conduction system at the level of the His bundle.

Materials and methods

Patients: Fifty-three patients were evaluated by M-mode echocardiography, mostly because of systolic murmurs localized to the cardiac apex or to the left lower sternal border. None had a history of rheumatic heart disease. Clinical records were analyzed in relation to documented history of congestive heart failure (New York Heart Association functional class III or IV), angina pectoris, cardiac arrhythmias, and other relevant clinical diagnoses. Electrocardiographic data were obtained in all patients. All had posteroanterior and lateral chest roentgenograms. Cinefluoroscopic data were available in 14 patients who underwent cardiac catheterization. Seven patients had an electrophysiologic study of the His bundle because of history or findings suggestive of conduction problems.

Echocardiography: M-mode echocardiography was done in all patients with a Picker-Echoview 80C echocardiograph, with a 2.25 MHz, 1.3-cm medium focus transducer. The echocardiographic diagnosis of MAC was made when a dense band of echos was seen in the region behind the posterior mitral leaflet,

anterior to the posterior left ventricular wall and moving parallel to the latter. A sweep from the left ventricular cavity toward the aortic root typically showed abrupt disappearance of these echos (*Figure*). The thickness of the MAC was measured in millimeters at its point of best evidence behind the mitral valve, and an average value was recorded for each patient.

Electrophysiologic study (EPS): The patients were studied in the nonsedated state before and after administration of 1 mg of atropine sulfate intravenously. Informed consent was obtained from each patient. A bipolar catheter was introduced percutaneously via a femoral vein and positioned across the tricuspid valve for His bundle recording. A second bipolar catheter introduced percutaneously from the same region was used for right atrial recording and pacing. Electrocardiographic leads I and aV_F were recorded simultaneously by means of a multichannel oscilloscopic photographic recorder (Electronics for Medicine, Minneapolis, Minnesota) at paper speeds of 100 mm/sec. A-H interval representing conduction time from the right atrium through the AV node to the His bundle was measured (normal range in adults, 45–110 msec). H-V interval representing conduction time from the proximal His bundle to the ventricular myocardium was measured from the earliest His bundle deflection to the earliest onset of ventricular activation recorded from the surface ECG leads or the ventricular electrogram in the His bundle recording. Normal H-V interval in adults was considered to be 35 to 55 msec. Maximum sinus node recovery time (SNRT) was measured following overdrive suppression with right atrial pacing at progressively shorter

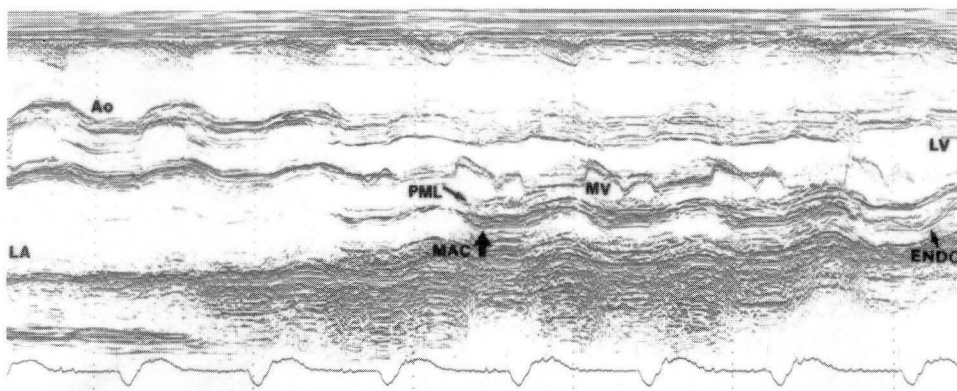


Figure. Mitral annulus calcification demonstrated with a sweep from the aortic root to the left ventricular cavity.

AO = aortic root; LA = left atrium; IVS = intraventricular septum; MV = mitral valve; AL = anterior leaflet of mitral valve; PML = posterior leaflet of mitral valve; LV = left ventricular cavity; MAC = mitral annulus calcification; ENDO = endocardial surface of posterior left ventricular wall.

cycle lengths, allowing two minutes pacing at each attempt. The time interval between the last pacing spike and the following sinus escape complex was measured, reflecting the degree of depression of SA node automaticity. Maximum SNRT of more than 1500 msec was considered abnormal. Incremental atrial pacing was then accomplished, analyzing the functional properties of the AV conduction system. End points were the onset of 2° or 3° AV block with decreasing cycle lengths.

Results

Of 53 patients, 39 were females and 14 were males, with a F/M ratio of 2.8:1. Mean age was 70.2 ± 9 years (range, 55–80 years) for the males and 70.6 ± 8.4 years (range, 50–91 years) for the females. *Table 1* shows the prevalence of congestive heart failure, diabetes mellitus, chronic renal failure, systemic hypertension, and bacterial endocarditis. In most of the patients (92.5%) a significant systolic murmur was detected before echocardiographic diagnosis of MAC, even though in only one patient was this diagnosis suspected clinically at the time of the initial evaluation.

The fluoroscopic and radiographic results presented in *Table 2* show a significant discrepancy between fluoroscopic and radiographic sensitivity in regard to the diagnosis of MAC. *Table 3* presents the electrocardiographic findings, with particular emphasis on conduction disorders, present in 53.6% of cases. Our echocardiographic analysis allowed us to define four groups of patients on the basis of severity of MAC (*Table 4*). A more detailed analysis showed a tendency toward progressively more severe degree

Table 1. Clinical features of the 53 patients

Diagnosis	Number of patients	Percent
Congestive heart failure	17	32
Diabetes mellitus	13	24
Chronic renal failure	1	2
Systemic hypertension	18	34
Bacterial endocarditis	1	2
Hypercalcemia (>10.5 mg/100 ml)	1	2

Table 2. Fluoroscopic and radiographic results

	Number of patients	Percent
Fluoroscopy	18/53	34
MAC on fluoroscopy	15/18	83
Chest roentgenogram	53/53	100
MAC on chest roentgenogram	1/53	2

Table 3. Electrocardiographic findings

ECG findings	Number of patients	Percent
Normal EKG	12/53	22.7
Abnormal EKG	41/53	77.3
Conduction problems	22/41	53.6
CLBBB	7/41	17.0
CRBBB	3/41	7.3
LAHB	4/41	9.6
1°–2° AV block	2/41	4.8
3° AV block	6/41	14.5
Atrial fibrillation	14/41	34.1
PVC	4/41	9.7
Remote infarct	7/41	17.0

CLBBB = complete left bundle branch block, CRBBB = complete right bundle branch block, LAHB = left anterior hemiblock, PVC = premature ventricular contraction.

Table 4. Extent of mitral annulus calcification (MAC) as defined by direct measurement of the echocardiographic thickness

MAC	Number of patients	Percent
Minimal (1–3 mm)	4	7.6
Mild (3–5 mm)	12	22.6
Moderate (5–8 mm)	18	33.9
Severe (≥ 8 mm)	19	35.8

Table 5. Thickness of mitral annulus calcification (MAC) in males and females

	Number	MAC (mm)
Males, yr		
50–60	3	5.3 ± 2.9
60–70	3	7.3 ± 4.0
>70	8	7.2 ± 2.9
Total	14	7.2 ± 3.3
Females, yr		
50–60	7	7.1 ± 2.4
60–70	10	7.3 ± 2.3
>70	22	7.4 ± 2.8
Total	39	7.2 ± 2.6

of MAC with increasing age (*Table 5*). The mean MAC was 7.2 ± 2.6 mm.

Fifteen patients underwent cardiac catheterization with coronary arteriography; 7 patients (46.7%) demonstrated significant coronary atherosclerosis (>50% luminal obstruction in at least one of the four main epicardial coronary vessels) and 5 had evidence of aortic stenosis, 3 of whom underwent aortic valve replacement (5.6% of the entire group).

Nine patients (17%) required a permanent demand pacemaker because of symptomatic bradyarrhythmias. In 7 of them, complete EPS data were obtained (*Table 6*). The A-H interval ranged from

80 to 100 msec (91 ± 7 msec); the H-V interval ranged from 45 to 120 msec (65 ± 24 msec). Patients with 3° AV block (nos. 1, 3, 4 and 5) had a significantly prolonged H-V interval compared with the 3 patients (nos. 2, 6, and 7) with a diagnosis of sick sinus syndrome (78 ± 25 msec versus 48 ± 9 msec).

The mean MAC of this group was not significantly different from the mean value of the entire group studied (7.1 ± 3.2 mm versus 7.2 ± 2.6 mm).

Discussion

The validity of the echocardiographic demonstration of MAC, compared with fluoroscopic detection has been demonstrated by several previous studies.^{1,7,8} When typical echocardiographic features are demonstrated,^{2,4} this diagnosis is well accepted.

The echocardiographic quantification of the severity of MAC has not been clinically utilized so far. A direct correlation between the amount of calcium present and the degree of MAC seen by echocardiography would be of great clinical importance. Such correlation would necessarily imply echocardiographic study of patients subsequently undergoing autopsy or heart surgery; however, no such study is available.

We have attempted to define the amount of calcification of the mitral annulus seen by M-mode echocardiography; our initial results agree with other studies^{9,10} that suggested a higher prevalence of MAC among elderly women.

Previous studies suggested that such prevalence could be accounted for by considering the higher

incidence of rheumatic mitral valvular disease among females,^{5,11} but more recently a predominantly nonrheumatic etiology has been demonstrated for most patients with MAC.^{3,12} Eight of the initial group of 61 patients with definite MAC were excluded because of evidence of rheumatic mitral stenosis. MAC can be associated with rheumatic valvular disease and possibly be a late feature of that destructive process as it involves the mitral structure. The relative prevalence of such an association has not been clearly defined. Schott et al,⁷ in their group of 41 patients with MAC, found 13 with rheumatic heart disease (32%) and 28 with nonrheumatic degenerative annular calcification. The mean age of the patients with rheumatic MAC was significantly lower (56 ± 8 years) than that of the remaining patients, suggesting that such patients could constitute a separate group within the spectrum of MAC. Interestingly, the group of patients with chronic renal failure (32%) had a significantly lower mean age than the group with normal renal function (63 ± 15 years versus 73 ± 10 years).

Fulkerson et al³ found a 14% incidence of mitral valve prolapse among 80 patients with MAC; their mean age was significantly lower (64 versus 75 years) than that of patients without mitral valve prolapse.

These observations suggest that MAC is a degenerative, gradual aging process that involves mostly females, usually becoming apparent after the sixth and particularly the seventh decade of life. Different conditions such as rheumatic valvular disease, mitral valve prolapse and chronic renal failure (the latter perhaps through alteration of the PTH and calcium metabolism¹³) seem to accelerate such a process which could then develop earlier.

Of our patients, 69.7% were found to have MAC of more than 5 mm thickness. Recent data¹⁴ demonstrate a significant correlation between MAC of more than 5 mm in thickness and congestive heart failure, conduction problems, aortic valve sclerosis or stenosis and atrial fibrillation, supporting the hypothesis that such noninvasive evaluation of MAC could be utilized to select patients more at risk for future onset of such complications.

A possible association between MAC and coronary atherosclerosis has been previously suggested¹⁵. An interesting possibility could be an increased tendency towards calcific processes in these patients. We have found a remarkable prevalence of both coronary atherosclerosis (often with coronary calcification) and calcific aortic valve sclerosis or stenosis. No alterations of calcium metabolism were apparent in our patients.

In a recent study of 65 patients with MAC, 23

Table 6. Electrophysiologic findings in 7 patients with MAC, conduction disturbances and permanent pacemaker

Diagnosis	A-H Interval (N = 45-110 msec)	H-V Interval (N = 35-55 msec)	Abnormal findings during His bundle study
1 3° AV block	80	70	2:1 AV block below His
2 SSS	100	45	Abnormal SNRT
3 3° AV block	90	65	3° AV block
4 3° AV block	—	120	3° AV block
5 Intermittent AV block	90	55	Intermittent 3° AV block
6 SSS	90	60	2:1 AV block (below His) with atrial pacing at 150 BPM
7 SSS	100	40	Documented asystole

SNRT = Sinus node recovery time, SSS = sick sinus syndrome.

demonstrated significant conduction disturbances and 4.6% required a permanent pacemaker.¹⁶ A similarly high prevalence of symptomatic conduction problems has been demonstrated by previous studies.^{3,17} We have found atrioventricular and/or bundle branch conduction disturbances in 22 of our patients. Nine patients needed a permanent pacemaker (6 had complete AV block and 3 had evidence of sick sinus syndrome). EPS available in 7 patients showed a prolonged H-V interval in 4 when compared with the other 3 patients in whom sick sinus syndrome was initially diagnosed. Prolonged H-V interval is frequently demonstrated in patients with chronic bifascicular and trifascicular block.¹⁸

Markedly prolonged H-V interval (more than 75 msec) is likely associated with higher risk for sudden death or complete AV block, even though prognosis of such patients is more closely dependent on the underlying presence of coronary atherosclerosis and ischemic congestive cardiomyopathy.¹⁸ The fact that the mean MAC thickness of the 9 patients who received a permanent pacemaker was not significantly different from that of the rest of the patients could be attributed to the small number included in the EPS group with a wide variation of MAC, which ranged from 3 to 13 mm. These data confirm the increased prevalence of significant conduction problems at or below the His bundle with consequent complete AV block. This might be related not only to the amount of calcification present but also to its localization. A more medial distribution could more likely damage the nearby conduction system. Two-dimensional echocardiographic study of this disease could be of great advantage in identifying patients more at risk for development of symptomatic conduction disturbances. Sporadic autopsy reports¹⁹ have demonstrated disruption of the conduction system due to this mechanism, but no electrophysiologic data are available.

This study supports previous clinical and electrocardiographic observations in patients with MAC. M-mode echocardiography is a relatively new and useful tool in the evaluation of these patients. Information obtained by ultrasound could go beyond a mere descriptive diagnosis and be utilized also as a direct measure of the extent of the calcific process.

Data on larger groups of patients with MAC undergoing EPS are necessary in order to confirm our hypothesis relating to the onset of symptomatic severe conduction disorders in such patients. Our initial electrophysiologic observations, as well as other recent reports,^{14,16,17,20} indicate that the echocardiographic quantification and localization of MAC could be useful for selection and close follow-

up of patients more likely to suddenly develop complete AV block.

References

1. D'Cruz IA, Cohen HC, Prabhu R, Bisla V, Glick C. Clinical manifestations of mitral annulus calcification, with emphasis on its echocardiographic features. *Am Heart J* 1977; **94**:367-377.
2. Dashkoff N, Karacuschansky M, Come PC, Fortuin NJ. Echocardiographic features of mitral annulus calcification. *Am Heart J* 1977; **94**:585-592.
3. Fulkerson PK, Beaver BM, Auseon JC, Graber HL. Calcification of mitral annulus—etiology, clinical association, complications and therapy. *Am J Med* 1979; **66**:967-977.
4. Gabor GE, Mohr BD, Goel PC, Cohen B. Echocardiographic and clinical spectrum of mitral annular calcification. *Am J Cardiol* 1976; **38**:836-842.
5. Korn K, DeSanctis RW, Sell S. Massive calcification of the mitral annulus—a clinicopathological study of fourteen cases. *N Engl J Med* 1962; **267**:900-908.
6. Simon MA, Liu SF. Calcification of the mitral valve annulus and its relation to functional valvular disturbance. *Am Heart J* 1954; **48**:497-505.
7. Schott CR, Kotler MN, Parry WR, Segal BL. Mitral annular calcification; clinical and echocardiographic correlations. *Arch Intern Med* 1977; **137**:1143-1150.
8. Mellino M, Salcedo EE. Fluoroscopy and echocardiography in patients with mitral annulus calcification (Abstracts p 41). Third International Cardiovascular Congress Arizona Heart Inst., Feb 1981.
9. Pomerance A. Pathological and clinical study of calcification of the mitral valve ring. *J Clin Pathol* 1970; **23**:354-361.
10. Pomerance A. Pathology of the heart with and without cardiac failure in the aged. *Br Heart J* 1965; **27**:697-710.
11. Epstein BS. Comparative study of valvular calcification in rheumatic and non-rheumatic heart disease. *Arch Intern Med* 1940; **65**:279-287.
12. D'Cruz I, Panetta F, Cohen H, Glick G. Submitral calcification or sclerosis in elderly patients; M mode and two dimensional echocardiography in "mitral annulus calcification." *Am J Cardiol* 1979; **44**:31-37.
13. Jain M, D'Cruz I, Kathpalia S, Goldberg A. Mitral annulus calcification as a manifestation of secondary hyperparathyroidism in chronic renal failure. *Am Heart Assoc (Abstracts)* 1980; **3**:133.
14. Mellino M, Salcedo EE, Lever HM, Vasudevan G, Kramer JR. Echographic-quantified severity of mitral annulus calcification; prognostic correlation to related hemodynamic, valvular, rhythm, and conduction abnormalities. *Am Heart J* 1982; **103**:222-225.
15. Roberts WC, Perloff JK. Mitral valvular disease. *Ann Intern Med* 1972; **77**:939-975.
16. Zonerach S, Zonerach O, Patel M. Conduction disturbances in patients with calcified mitral annulus diagnosed by echocardiography. *J Electrocardiology* 1979; **12**:137-139.
17. Nair CK, Runco V, Everson GT, et al. Conduction defects and mitral annulus calcification. *Br Heart J* 1980; **44**:162-167.
18. McAnulty JH, Rahimtoola SH, Murphy E, et al. Natural history of "high risk" bundle-branch block. *N Engl J Med* 1982; **307**:137-143.
19. Bertolatus JA, Ridolfi RL, Hutchins GM. Complete heart block caused by calcific mitral annulus fibrosus. *Johns Hopkins Med J* 1974; **135**:199-203.
20. Nair CK, Sketch MH, Desai R, Mohiuddin SM, Runco V. High prevalence of symptomatic bradyarrhythmias due to atrioventricular node-fascicular and sinus node-atrial disease in patients with mitral annular calcification. *Am Heart J* 1982; **103**:226-229.