

# Contact dermatitis to knee patch adhesive in boys' jeans: a nonoccupational cause of epoxy resin sensitivity

James S. Taylor, M.D.<sup>1</sup>  
Wilma F. Bergfeld, M.D.<sup>1</sup>  
Jere D. Guin, M.D.<sup>2</sup>

Three cases of eczematous dermatitis of the knees are reported in three children who had been wearing Sears, Roebuck and Co. Toughskin® and/or Roughhouser® jeans with knee patches for several months. All had strong positive patch tests to epoxy resin (Epon® 825) from the standard screening patch test tray and to pieces of the knee patches. Although Sears initially denied that "epoxy resin" was present in the knee patch adhesive, it was later confirmed that 4,4-isopropylidene diphenyl epichlorohydrin (Epon® 828) was present. In 2 of the 3 patients patch-tested to Epon® 828, results were positive, one test at a concentration of 1:20,000. The epoxy resin had been added to the knee patch adhesive as an adhesion promoter. Sears has now substituted a nonepoxy adhesive for the knee patch of their jeans.

**Index terms:** Dermatitis, clothing • Dermatitis, contact • Epoxy resins

**Cleve Clin Q** 50:123-127, Summer 1983

<sup>1</sup> Department of Dermatology, The Cleveland Clinic Foundation. Submitted for publication 15 Feb 1983; accepted 30 March 1983.

<sup>2</sup> Address: 804 S. Berkley Rd., Kokomo, IN 46901. Clinical Assistant Professor, Department of Dermatology, Indiana University School of Medicine. As of 1 June, Dr. Guin will be professor and chairman, Department of Dermatology, The University of Arkansas School for Medical Sciences, Little Rock, AR.

Clothing may produce irritant or allergic reactions that appear clinically as eczematous, petechial, urticarial, or pigmented eruptions.<sup>1,2</sup> Allergic eczematous contact dermatitis from fabric is usually due to dyes or synthetic resin finishes.<sup>1</sup> To our knowledge, dermatitis has never been reported from epoxy resin applied by a clothing manufacturer. We report three cases of allergic contact dermatitis from epoxy resin in the knee patch adhesive of certain types and sizes of boys' jeans sold by Sears, Roebuck and Co.

## Materials and methods

Standard dermatological history and examination were

performed. Patch testing was conducted according to the methods recommended by the Task Force on Contact Dermatitis of the American Academy of Dermatology.<sup>3</sup> The patch test unit was the A1 test<sup>®</sup> and the tape used was Scanpore.<sup>®</sup> Patch tests were occluded for 48 hours, removed by the patient, and read at 72 hours using a scale of 1+ to 3+.

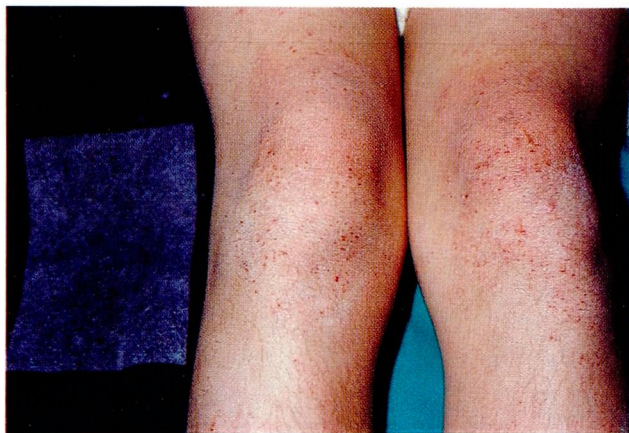### Case reports

**Case 1.** An 11-year-old boy was referred by his pediatrician to the Cleveland Clinic in March 1981 with a 1½-year history of persistent dermatitis of the legs, especially prominent on the knees. His face, trunk, and arms were spared. Therapy with antihistamines and topical corticosteroids controlled the dermatitis only temporarily. He had a long history of asthma, recurrent otitis media, and sinusitis. For two years, he had frequently worn Sears Toughskin<sup>®</sup> and Roughhouser<sup>®</sup> jeans of various colors (blue, brown, cranberry, and tan). There was no history of allergy to dyes, rubber, adhesives, or medications. Certain brands of soap irritated his skin.

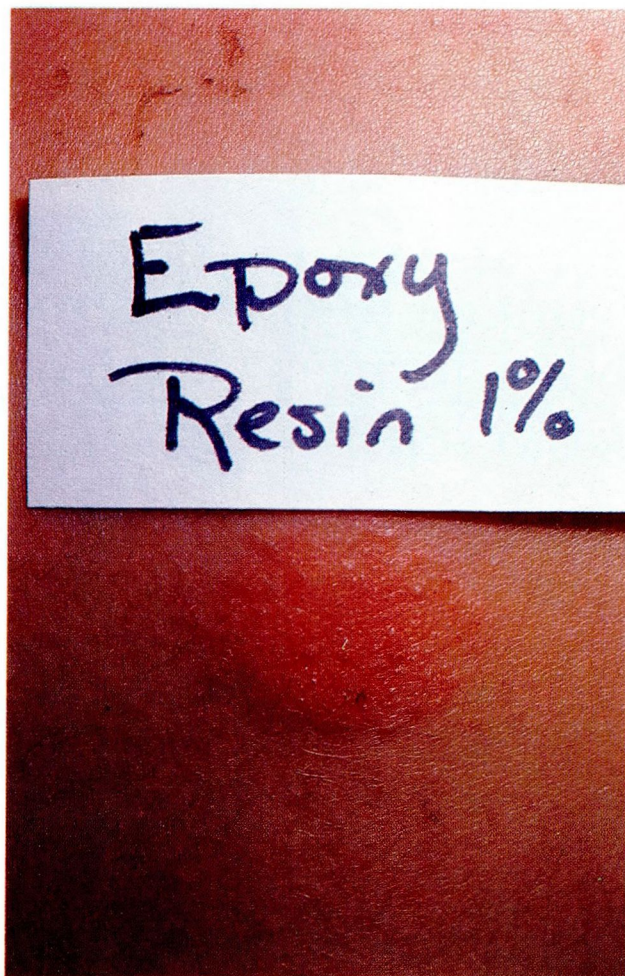On physical examination, there was a dry, patchy, eczematous eruption on the knees and generalized asteatosis of the legs, both anteriorly and posteriorly (*Fig. 1*).

Initial patch testing was performed with the standard screening tray of the American Academy of Dermatology.<sup>3</sup> Material was taken from the pant legs and knee patches of four pairs of Sears Toughskin<sup>®</sup> and Roughhouser<sup>®</sup> jeans, clothing finishes, and miscellaneous chemicals. There were 2+ reactions to epoxy resin [1% petrolatum (pet)] (*Fig. 2*) and each of the four pieces of knee patch material. There were 1+ reactions to mercaptobenzothiazole (1% pet), propylene glycol [10% aqueous (aq)], and 1,3-butanediol (20% aq). Patch tests were negative to all other substances including the pant leg material from the four pairs of jeans and the clothing finishes.

Further patch testing in July 1981 showed a strong 3+ reaction to the epoxy resin, Epon<sup>®</sup>828 (0.5% pet), and negative patch tests to a new knee patch supplied by Sears. The dermatitis resolved promptly following changing to jeans without knee patches and application of betamethasone valerate ointment 0.1%. There had been no recurrence



**Figure 1.** Eczematous dermatitis of the knees (patient 1) and knee patch on the inside of the pant leg.



**Figure 2.** Positive patch test to epoxy resin (Epon<sup>®</sup>825) (patient 1).

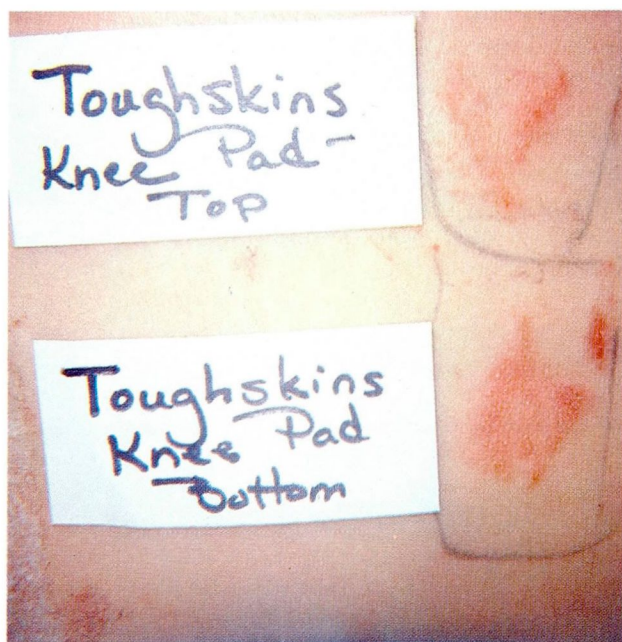
of the dermatitis when the patient was seen four months later.

**Case 2.** A nine-year-old boy was referred to the Department of Dermatology at the Cleveland Clinic from the Department of Pediatrics for a knee and thigh eruption of one year's duration. The dermatitis cleared partially in the summer, but never entirely in spite of intermittent treatment with topical corticosteroids and oral antihistamines and antibiotics. The eruption always began on the knees. There was no history of eczema or atopy; however, his mother had had asthma and his sister eczema. He was allergic to penicillin. For more than one year, he had worn several pairs of Sears Toughskin<sup>®</sup> jeans. There was no history of allergy to dyes, rubber, topical medications, or adhesives.

Physical examination revealed a patchy, eczematous dermatitis with excoriations on both knees but sparing other areas.

Patch testing with the standard screening tray of the American Academy of Dermatology<sup>3</sup> gave a 2+ reaction to epoxy resin (1% pet). Simultaneous testing with the materials from both sides of the knee patch was 2+ positive (*Fig. 3*). Patch tests were negative to material from the pant legs





**Figure 3.** Positive patch tests to both sides of the knee patch (pad) (patient 2).

of the jeans, mercaptobenzothiazole, and other miscellaneous chemicals including propylene glycol and 1, 3-butanediol.

The dermatitis resolved promptly following changing brands of jeans and application of 1% hydrocortisone cream. Follow-up inquiry in March 1983 revealed no recurrence of the dermatitis with avoidance of the Toughskin® jeans.

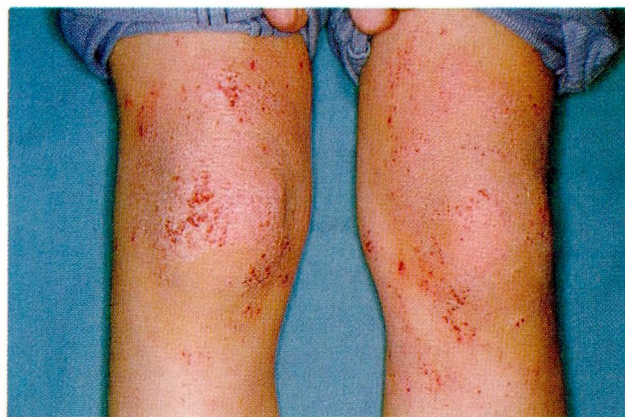**Case 3.** A seven-year-old boy presented to a private dermatologist (JDG) in Kokomo, Indiana in February 1981 with an eczematous eruption on the knees of one month's duration.

There had been no recent purchases of clothing and six days out of seven he wore one of four pairs of Toughskin® jeans. These were regularly laundered and excess detergent was removed because of a chronic problem with dry skin. Overbathing had been carefully avoided during the winter months and particularly following the onset of the eruption for this reason. As a baby, the patient had had numerous episodes of irritation on the face and around the mouth. Treatment with 10% Crotamiton cream was not found beneficial. There was no history of contact dermatitis, allergy to dyes or adhesives, or exposure to unusual adhesive materials. The patient and maternal grandfather have prominent allergic rhinitis.

Physical examination revealed a patchy, eczematous eruption of the dorsal surface of the knees with sparing of other areas (Fig. 4).

Patch testing was done with the American Academy of Dermatology standard screening patch test series<sup>3</sup> as well as to material removed from the knee patches of one pair of Toughskin® jeans. All tests were negative except for epoxy resin (1% pet) and the knee patch material, both of which produced spreading 2+ reactions at 72 hours.

The condition responded promptly following avoidance of Toughskin® jeans and 24-hour occlusion with betamethasone valerate cream 0.1%, twice in a 72-hour period.



**Figure 4.** Patchy eczematous dermatitis of the knees (patient 3).

In March 1981, Sears indicated that there was no "epoxy resin" in Toughskin® jeans. However, on further inquiry concerning the other two patients, they responded that the adhesive was not, strictly speaking, an epoxy resin but contained epichlorhydrin, known to be an allergen.

Later patch testing was performed with the adhesive epoxy resin (Epon®828). A patch test with 0.005% Epon®828 in white petrolatum was negative at 72 hours. The next higher concentration, 0.05%, was applied and produced a 2+ reaction at 72 hours. By that time, the previous test to the lower concentration (0.005%) was also positive.

## Discussion

To our knowledge, these are the first reported cases of allergic contact dermatitis from epoxy resin applied to fabric in its manufacture. Sjorberg et al<sup>4</sup> described contact dermatitis from clothing contaminated with epoxy resin from tools used to connect epoxy-containing cables. Dermatitis developed on the thigh of a worker at the site of contact with the trouser pocket and persisted for three months after he stopped working with epoxy resin.

After we identified the knee patch adhesive as the probable cause of dermatitis in these children, on inquiry Sears identified the manufacturer and included a form letter for such inquiries (personal communication: letter from Nemechek FL; Sears, Roebuck and Co, Chicago, Illinois; May 11, 1981). It stated that certain Sears boys' jeans knee patches may have caused slight irritation in some children with sensitive or atopic skin. It further stated that Sears would begin using a new knee patch tested and proved to cause no skin reaction on children who had shown a reaction to the original knee patch.

The incriminated knee patch was used on denim Western-styled Toughskin® jeans, sizes 2-6X, 8-16, and Husky Plus; denim Western-styled Roughhouser® jeans, sizes 8-16 and Husky Plus.



**Table.** Components of allergenic knee patch adhesive

Raw material	Trade name
Magnesium oxide	Maglite D®
Calcium carbonate	Atomite®
Carbon black	Regal®300
Chlorosulfonated polyethylene	Hypalon®LD 999
Chlorosulfonated polyethylene	Hypalon®45
Titanium dioxide	Ti Pure LW®
Polyethylene glycol	Carbowax®4000
Diisodecylphthalate	DIDP®
4,4-Isopropylidene/diphenyl epichlorohydrin	Epon®828

Correspondence with the adhesive manufacturer identified 4,4-isopropylidene diphenyl epichlorohydrin, an epoxy resin, as one of the components (*Table*) (personal communication: letter from Fosgate CM; Haartz-Mason Inc.; Watertown, Massachusetts, May 28, 1981). Between 1976 and 1980 the basic elastomers in the adhesive were the chlorosulfonated polyethylenes Hypalon® LD999 and Hypalon®45 by Dupont. Previously, a Dupont neoprene-based adhesive was used, but was found to be destroyed by the new petroleum-based spray-and-wash cleaners. The current knee patch containing a polyvinyl chloride (PVC)-based adhesive has been in use since 1980. In laboratory tests of mechanical resistance to abrasion, the Hypalon® knee patch containing the epoxy resin was three times more resistant than the current PVC patch.

Rolls of fabric for the patch were supplied to Haartz-Mason, Inc. by the manufacturer of the jeans, most recently, Texas Apparel Company. After the adhesive was applied, the rolls were returned to Texas Apparel who cut the patches and vulcanized them to the inside of the pant leg with heat and pressure. The raw fabric had first been bleached and treated with finishing chemicals. The adhesive became the filling between the pant shell and the knee patch (personal communication: telephone conversation with Sieber WE; Haartz-Mason Inc, November 30, 1981). Epon®828 was present in the adhesive in a concentration of 3% to 4% and served as an adhesion promoter.

Initial patch testing by Dunlap on behalf of Sears demonstrated positive patch tests to the knee patch (personal communication: letter from Dunlap FE; Chicago Heights, Illinois; June 5, 1981). However, attempts to obtain the chemical components were unsuccessful at that time. Based on these tests, Sears subsequently con-

tracted with a new adhesive supplier who formulated the current PVC-based adhesive.

As of May 1981, the epoxy resin-containing adhesive was still present in some jeans sold by Sears. Rather than withdrawing these jeans from the market, Sears provided inquirers with information to identify the jeans with the new PVC, nonepoxy resin-containing adhesive. These contained the code letters DB on the joker tickets sewn into the pocket seam and the permanent size label sewn inside the fly.

The dermatitis was initially reported to dermatologists by Vail in June 1980.<sup>5</sup> During the preceding two winters he had seen several prepubertal boys with a distinctive pruritic, dry, follicular papular dermatitis on the knees and lower anterior thighs. Most had an atopic background and all wore Sears Toughskin® jeans regularly. Bland topical therapy and avoidance of the jeans cleared the dermatitis.

In August 1980, Hadler et al<sup>6</sup> reported that patch tests with the knee patch material were negative. They identified a problem from iron-on knee patches. However, in our conversations with Haartz-Mason Inc., the company denied selling these adhesives for use on iron-on patches.

Occupational and nonoccupational contact dermatitis from epoxy resin and its related chemistry have recently been discussed.<sup>7-11</sup> Many industrial epoxy resins are reported to evoke sensitivity, including those in varnishes, paints, laminated plastics, glues, and electrical insulation. Fregert<sup>11</sup> states that frequent unexplained reactions to epoxy resin at routine patch testing suggest sensitization from the nonworking environment from two main sources: hobby glues and residues of unhardened resin on coated objects. He has identified unhardened epoxy resin oligomers with a molecular weight of 340, the sensitizing portion of epoxy resin, on sign boards, bottle caps, film cassettes, metal packages, brass doorknobs, etc, and epoxy-sensitive people have shown positive patch test reactions to these objects. He postulates that most individuals have been sensitized from other sources such as glues. The amounts of unhardened resin remain sufficient to at least elicit dermatitis in sensitized individuals.

The knee patch used by one of our sensitive patients was analyzed in March 1982 by Sigfrid Fregert, M.D. (personal communication: letter from the Department of Occupational Dermatology, University Hospital, Lund, Sweden, March

22, 1982). He found no unhardened epoxy resin.<sup>12</sup> However, in view of the positive patch test to a piece of another knee patch in our patient (with negative results in 20 control patients), batch variations may exist and unhardened epoxy is likely to have been present.

Although our patients were not tested to all components of the adhesive, the case for Epon®828 as the cause of the dermatitis is conclusive. Positive patch tests for epoxy resin are unusual in children. The epoxy resin in the standard screening tray<sup>3</sup> is Epon®825, which produced strong positive reactions in all three patients. Tests on the two who returned for further patch testing with Epon®828, were both positive; one test at a concentration of 1:20,000 (0.005%) was positive. Patient 1 was patch-test positive to mercaptobenzothiazole, propylene glycol and butanediol; however, these substances were not present in the knee patch adhesive and were not contributory to the dermatitis. Our patients had never developed dermatitis on the knees before wearing the Sears jeans and the eruption resolved promptly with avoidance of the jeans.

In conclusion, several points should be emphasized about our patients. The cause of the dermatitis was covert to the patients but obvious to the examining physicians. These cases are prime examples of the value of patch testing with the standard screening tray instead of only "aimed" patch testing with the overtly suspected object. These cases also illustrate the difficulty in obtaining accurate and complete information from

commercial sources, especially when several companies are involved. Familiarity with generic and trade names is essential.

### Acknowledgment

The technical assistance of Mrs. Dorcas H. Burlingame in patch-testing patients 1 and 2 is greatly appreciated.

### References

1. Fisher AA. Contact Dermatitis. 2nd ed. Philadelphia: Lea & Febiger, 1973.
2. Cronin E. Contact Dermatitis. Edinburgh: Churchill Livingstone, 1980.
3. Task Force on Contact Dermatitis. The role of patch testing in allergic contact dermatitis. Evanston, Illinois: American Academy of Dermatology, 1982.
4. Sjoberg K, Tegner E, Fregert S. Sensitization to epoxy resin from contaminated pocket. Contact Dermatitis Newsletter 1973; **13**:356.
5. Vail JT. Dermatitis from Toughskin jeans. The Schoch Letter 1980; **30** (June):16.
6. Hadler WR, Grande DW, Vydareny JR. Toughskin jeans. The Schoch Letter 1980; **30** (Aug):23.
7. Mathias CG. Penetrating effects of epoxy resin systems. Occup Health Saf 1981; (May) **50**:42-44, 59.
8. Fisher AA. Epoxy resin dermatitis. Cutis 1976; **17**:1027-1028, 1041.
9. Andersen KE. Cutaneous reaction to an epoxy-coated pacemaker. Arch Dermatol 1979; **115**:97-98.
10. Foussereau J, Benezra C, Maibach HI. Plastic materials. In: Occupational Contact Dermatitis—Clinical and Chemical Aspects. Copenhagen: Munksgaard, 1982: pp 216-237.
11. Fregert S. Epoxy dermatitis from the non-working environment. Br J Dermatol 1981; **105** (suppl 21):63-64.
12. Fregert S, Trulsson L. Simple methods of demonstration of epoxy resins of bisphenol-A type. Contact Derm 1978; **4**:69-72.