

# Hyaluronic acid synthesis in fibroblasts of pretibial myxedema<sup>1</sup>

C. William Hanke, M.D.<sup>2</sup>  
Wilma F. Bergfeld, M.D.  
Marcelle N. Guirguis, M.D.<sup>3</sup>  
L. James Lewis, Ph.D.<sup>4</sup>

**Hyaluronic acid production by fibroblasts from skin lesions of pretibial myxedema (PTM) and also from normal control skin was studied in tissue culture. Normal control fibroblasts produced increased amounts of hyaluronic acid when serum from patients with PTM was used to supplement the tissue culture medium. Further increases in hyaluronic acid synthesis were noted when PTM fibroblasts were incubated with normal human serum, and when PTM fibroblasts were incubated with serum from patients with PTM. These results suggest that a serum factor is operative in patients with PTM, and that this serum factor can influence the production of hyaluronic acid in both normal controls and PTM fibroblasts. This increased production of hyaluronic acid by fibroblasts may be a major factor in the pathogenesis of PTM.**

**Index terms:** Hyaluronic acid • Skin, diseases  
**Cleve Clin Q 50:**129-132, Summer 1983

The dermatological manifestation of Graves' disease usually affects the dorsum of the leg and has been called localized or pretibial myxedema (PTM). PTM is a component of Graves' disease that also includes diffuse thyrotoxic goiter and exophthalmos. Fifty percent of cases of PTM occur during active hyperthyroidism, and 50% after treatment of hyperthyroidism.<sup>1</sup> PTM occurs in 0.5% to 4.3% of cases of Graves' disease, and also has been seen in Hashimoto's thyroiditis and primary hypothyroidism.<sup>2-4</sup>

The three clinical variants of PTM include (1) the common sharply circumscribed type with nodules on the dorsum of the legs and toes, (2) the diffuse type with nonpitting edema on the dorsum of the legs and feet, and (3) the rare

<sup>1</sup> Department of Dermatology, The Cleveland Clinic Foundation. Submitted for publication March 1983; accepted April 1983.

<sup>2</sup> Dr. Hanke is now associate professor of dermatology, Indiana University School of Medicine, Indianapolis, IN.

<sup>3</sup> Tissue Culture Research Laboratory, The Cleveland Clinic Foundation.

<sup>4</sup> Deceased.

elephantiasic type with verrucous nodules and extreme enlargement of the affected extremities.<sup>5,6</sup>

The skin lesions of PTM are yellow-brown or erythematous plaques and nodules, usually on the dorsum of the legs and rarely on the thighs, abdomen, and upper extremities.<sup>7</sup> PTM may resolve totally or continue indefinitely with exacerbations and remissions.

Skin biopsy specimens from PTM lesions show a thickened dermis with replacement of the mid-dermal collagen by a band of amorphous basophilic material.<sup>8</sup> The material stains positively with the colloidal iron method and digests with hyaluronidase, which identifies the material as acid mucopolysaccharide (glycosaminoglycans).

Sisson<sup>9</sup> has reported that plaques of PTM contain 6–16 times more hyaluronic acid than normal control skin. Cheung et al<sup>10</sup> have noted increased hyaluronic acid synthesis in tissue culture by fibroblasts from the pretibial areas of patients with PTM and also in normal control pretibial skin.

This study was designed to evaluate the effects of a serum factor on hyaluronic acid synthesis by PTM fibroblasts and by normal fibroblasts in tissue culture.

## Materials

**Subjects:** Skin biopsy specimens were obtained from the leg lesions of two patients with PTM.

Patient 1, a 44-year-old white man, had a six-year history of Graves' disease, severe exophthalmos, and severe PTM. The long-acting thyroid stimulator (LATS) showed a 1750% level (normal, 80% to 120%) by the mouse bioassay method.<sup>11,12</sup>

Patient 2, a 54-year-old woman, had a three-year history of Graves' disease, mild periorbital edema, and moderate PTM. The serum LATS level was 1307% by the mouse bioassay method.

Skin biopsy specimens from the PTM lesions in both patients showed a bandlike deposition of gray-white material and increased numbers of fibroblasts in the mid-dermis on staining with hematoxylin and eosin. Colloidal iron stains and digestion by hyaluronidase identified the material as hyaluronic acid.

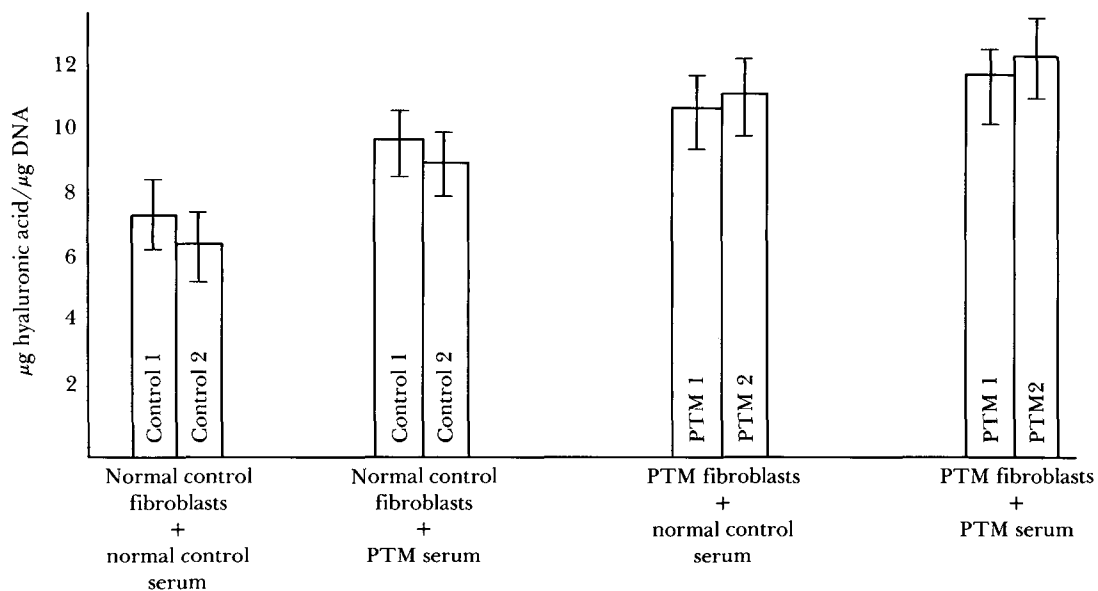
**Control fibroblasts:** Skin biopsy specimens were obtained from the pretibial areas of 3 healthy male patients aged 29, 36, and 41 years, respectively.

**Control serum:** Control serum was obtained from normal healthy individuals without evidence of acute or chronic skin disease.

**Pretibial myxedema serum:** PTM serum was obtained from patients 1 and 2 described in this report.

## Methods

The skin biopsy specimens from PTM and control patients were collected aseptically, washed with sterile phosphate-buffered saline,



**Figure.** Hyaluronic acid synthesis by cultured fibroblasts from the pretibial area of PTM patients and healthy normal control subjects. The vertical bars represent the standard deviation of four determinations. PTM serum = autologous serum from each of two patients with PTM.

minced into 1-mm<sup>2</sup> pieces and cultured in 75-cm<sup>2</sup> Falcon flasks. The tissue was fed LJL medium supplemented with 10% fetal calf serum and incubated at 37°C in an atmosphere of 5% carbon dioxide and 95% air.<sup>13</sup> Fibroblasts began to sprout from the explants approximately 10 days after explantation.

When the monolayer reached confluency, the cells were removed with trypsin and passed into clean 75-cm<sup>2</sup> flasks. Normal control fibroblasts from the scalp and PTM fibroblasts were grown in parallel. Fibroblasts from the 6th to the 10th passage were placed in 100-mm Petri dishes. Hyaluronic acid synthesis was determined with the modified carbazol method<sup>14</sup> from fibroblasts grown in separate cultures with 10% normal serum, 10% fetal calf serum, and 10% PTM serum.

The studies were conducted with the use of 100-mm Petri dishes, each with inoculum densities of 400,000 cells. Normal control serum or PTM serum was added to the fibroblast cultures after the third passage. Hyaluronic acid synthesis was measured on the 4th day when the cultures became confluent.

## Results

Normal control fibroblasts that were cultured in media supplemented with normal control serum demonstrated hyaluronic acid production in the 6.6–7.6 µg/µg DNA range (*Figure*). These values were considered the baseline normal values for the study. When PTM serum was substituted for normal control serum, hyaluronic acid synthesis increased. When PTM fibroblasts were used in place of the normal control fibroblasts and normal control serum was added to the media, the hyaluronic acid synthesis increased further. The highest values for hyaluronic acid synthesis were obtained when PTM serum was added to the media in which PTM fibroblasts were being grown.

## Comment

Results of our experiments revealed that pretibial fibroblasts from PTM patients produced increased amounts of hyaluronic acid when incubated with either PTM serum or normal control serum. Fibroblasts from the pretibial area of normal control patients produced increased amounts of hyaluronic acid when incubated with PTM serum, but not with normal serum. These results confirm that a “fibroblast-stimulating factor” is present in the serum of patients with PTM.

Hyaluronic acid synthesis by normal control fibroblasts as well as PTM fibroblasts can be stimulated by the “fibroblast-stimulating factor.”

Cheung et al<sup>10</sup> reported increased hyaluronic acid synthesis when fibroblasts from the pretibial areas of both PTM patients and normal controls were incubated with PTM serum in tissue culture. Fibroblasts from other areas (normal-appearing shoulder skin of PTM patients and normal controls; normal-appearing foreskin and skin from the backs of normal controls), under identical conditions, demonstrated no increased hyaluronic acid synthesis. In addition, pretibial fibroblasts from PTM patients showed no increased hyaluronic acid synthesis when incubated with normal human serum. These results were suggestive of a “fibroblast-stimulating factor” in the serum of PTM patients. Fibroblasts from different regions of the body of PTM patients responded differently to the serum “fibroblast-stimulating factor.”

LATS is a circulating immunoglobulin with thyroid-stimulating effects that are produced by lymphocytes in Graves' disease.<sup>15</sup> LATS has been detected in the sera of most patients with PTM.<sup>16–18</sup> This association may or may not indicate a pathogenetic role for LATS in PTM. McKenzie et al<sup>19</sup> believed that LATS was a significant causative factor in Graves' disease and might act by influencing cell-mediated immune mechanisms.<sup>20,21</sup>

The LATS antigen has not been precisely located, but is thought to be within the thyroid gland.<sup>22</sup> Thyroid injury caused by radioiodine treatment may result in the release of LATS antigen and the subsequent development of LATS antibody. This hypothesis is consistent with the observation that half the cases of PTM occur after treatment of Graves' disease.<sup>1</sup> Furthermore, spontaneous remission or resolution of PTM has been associated with decreased levels of LATS in the serum.<sup>22</sup> Thus, LATS may be the fibroblast-stimulating factor. However, LATS is a 7S gamma globulin; Cheung et al<sup>10</sup> found that their fibroblast-stimulating factor was not a 7S gamma globulin. Further studies on PTM sera are necessary to determine the nature of the serum factor involved.

Studies are also needed to determine whether fibroblasts from certain areas of the body are possibly more susceptible to activation by PTM serum, and to determine normal variations in hyaluronic acid synthesis by normal fibroblasts in different body areas of normal individuals.

Schermer et al<sup>18</sup> proposed that venous stasis, varicosities, focal extravasation of blood, and local trauma might account for the focal accumulations of hyaluronic acid in the pretibial areas of PTM patients. The results of our study and also those of Cheung et al<sup>10</sup> suggest that pretibial fibroblast stimulation by serum factors may be a more direct cause of the pretibial hyaluronic acid accumulations than these previously proposed hypotheses.

Lichen myxedematosus is a disease similar to PTM, in that it is associated with a serum factor and also results in the deposition of hyaluronic acid in skin lesions. Harper and Rispler<sup>23</sup> recently reported that a factor in lichen myxedematosus serum can stimulate DNA synthesis and cell proliferation by normal control fibroblasts. Further studies may show that the same serum factor also stimulates fibroblast hyaluronic acid synthesis in these patients.

We are currently conducting laboratory studies of hyaluronic acid synthesis in fibroblasts from many normal-appearing skin areas in patients with PTM.

## References

1. Ingbar SH, Woeber KA. Diseases of the thyroid. In: Thorn GW, ed. *Harrison's Principles of Internal Medicine*. 8th ed. New York: McGraw-Hill, 1977: p 512.
2. Edmundowicz AC, Ivy HK, Randall RV. Localized (pretibial) myxedema; report of two cases. *Postgrad Med* 1964; **35**:600-605.
3. Lynch PJ, Maize JC, Sisson JC. Pretibial myxedema and non-thyrotoxic thyroid disease. *Arch Dermatol* 1973; **107**:107-111.
4. Nixon DW, Samols E. Acral changes associated with thyroid disease. *JAMA* 1970; **212**:1175-1181.
5. Rook S, Cairns RJ. Metabolic and nutritional disorders. In: Rook A, Wilkinson DS, Ebling FJG, eds. *Textbook of Dermatology*. Oxford: Blackwell Scientific Publications, 1972: p 1870.
6. Hanke CW, Bergfeld WF, Guirguis MN, Lewis LJ. Pretibial myxedema: elephantiasic form. *Cleve Clin Q* 1983; **50**:183-188.
7. Cohen BD, Benua RS, Rawson RW. Localized myxedema involving the upper extremities. *Arch Intern Med* 1963; **111**:641-646.
8. Lever WF, Schaumburg-Lever G. Metabolic diseases. In: *Histopathology of the Skin*. 5th ed. Philadelphia: J.B. Lippincott, 1975: p 404.
9. Sisson JC. Hyaluronic acid in localized myxedema. *J Clin Endocrinol Metab* 1968; **28**:433-436.
10. Cheung HS, Nicoloff JT, Kamiel MB, Spolter L, Nimni ME. Stimulation of fibroblast biosynthetic activity by serum of patients with pretibial myxedema. *J Invest Dermatol* 1978; **71**:12-17.
11. McKenzie JM. The bioassay of thyrotropin in serum. *Endocrinology* 1958; **63**:372-382.
12. McKenzie JM, Williamson A. Experience with the bio-assay of the long-acting thyroid stimulator. *J Clin Endocrinol* 1966; **26**:518-526.
13. Lewis LJ, Hoak JC, Maca RD, Fry GL. Replication of human endothelial cells in culture. *Science* 1973; **181**:453-454.
14. Dische Z. A modification of the carbazole reaction of hexaronic acids for the study of polyuronides. *J Biol Chem* 1950; **183**:489-495.
15. Miyai K, Fukuchi M, Kumahara Y, Abe H. LATS production by lymphocyte culture in patients with Graves' disease. *J Clin Endocrinol* 1967; **27**:855-860.
16. Lipman LM, Green DE, Snyder JE, Nelson JC, Solomon DH. Relationship of long-acting thyroid stimulator to the clinical features and course of Graves' disease. *Am J Med* 1967; **43**:486-490.
17. Kriss JP, Pleshakov V, Chien JR. Isolation and identification of the long-acting thyroid stimulator and its relation to hyperthyroidism and circumscribed pretibial myxedema. *J Clin Endocrinol* 1964; **24**:1005-1028.
18. Schermer DR, Roenigk HH Jr, Schumacher OP, McKenzie JM. Relationship of long-acting thyroid stimulator to pretibial myxedema. *Arch Dermatol* 1970; **102**:62-67.
19. McKenzie JM, Zakarija M, D'Amour P, Joasoo A. The long-acting thyroid stimulator: Is it of importance in Graves' disease. *NZ Med J* 1975; **81**:18-21.
20. Mahieu P, Winand R. Demonstration of delayed hypersensitivity to retrobulbar and thyroid tissues in human exophthalmos. *J Clin Endocrinol* 1972; **34**:1090-1092.
21. Volpe R, Edmonds M, Lamki L, Clarke PV, Row VV. The pathogenesis of Graves' disease; a disorder of delayed hypersensitivity? *Mayo Clin Proc* 1972; **47**:824-834.
22. Kriss JP. The long-acting thyroid stimulator and thyroid disease. *Adv Intern Med* 1976; **16**:135-154.
23. Harper RA, Rispler J. Lichen myxedematosus serum stimulates human skin fibroblast proliferation. *Science* 1978; **199**:545-547.