

Cutaneous T-cell immunoblastic sarcoma¹

Jaye E. Benjamin, M.D.
Wilma F. Bergfeld, M.D.
Raymond R. Tubbs, D.O.
James T. McMahon, Ph.D.

We describe a rare malignant neoplasm, cutaneous T-cell immunoblastic sarcoma (IBS-T). Clinical examination revealed multiple 3–6 mm salmon-pink papules. On biopsy, these papules contained perivascular dermal infiltrates with atypical mononuclear cells, characterized by immunohistochemistry and electron microscopy as T lymphocytes with phenotype T₃+, T₁₁+, Ia+ and B₁-,κ-,λ-, which exhibited focal epidermotropism.

Index terms: Immunity • Sarcoma, cutaneous T-cell immunoblastic • Skin, neoplasms
Cleve Clin Q 50:167–171, Summer 1983

In 1974, based on a study of morphologic characteristics, cytochemistry, and surface immunologic markers, Lukes and Collins¹ recognized that non-Hodgkin's lymphomas were neoplasms of the immune system and displayed the differentiation features of transformed B and T cells. The cutaneous neoplasm, described in this case report, is composed of T lymphocytes indistinguishable from those stimulated by plant lectins in vitro and found in interfollicular benign lymphoid tissue reactions. Immunoblastic T-cell sarcoma was documented in 1978 by Lukes et al.^{2,3} We report what we believe to be the first case of cutaneous immunoblastic T-cell sarcoma, previously classified as reticulum-cell sarcoma, large cleaved and noncleaved follicular center-cell lymphoma, or histiocytic lymphoma² (*Table*).

Case report

A 56-year-old man was first seen in 1968 complaining chiefly of swollen cervical lymph nodes. Physical examination was unremarkable except for multiple salmon-pink lichenoid papules on the medial aspect of the knees, elbows, and forearms. Biopsy suggested cutaneous lymphoma. The patient was treated intermittently with topical nitrogen mustard, triamcinalone acetonide ointment 0.25%, and injection of 5-fluorouracil into the lesions, producing temporary resolution and improvement.

In February 1979 the patient was admitted to The Cleveland Clinic Foundation with swelling of the left knee, ankle, and groin. Physical examination showed 3 × 3-cm nodes in the left inguinal region and an 8 × 4-cm mass in the left lower quadrant of the abdomen. Examination revealed multiple 3–6-mm papules on the arms and trunk. Staging evaluation demonstrated a left pelvic mass and enlarged left peri-iliac nodes. Results of the needle biopsy of the mass were interpreted as diagnostic for Hodgkin's disease, indeterminant type. A lymph-node biopsy specimen demonstrated fibrosis with no atypical infiltrate, whereas a liver biopsy specimen showed only mild fatty change. Laboratory tests were essentially normal except for slight elevation of alkaline phosphatase (95 mU/ml; normal, 30–85 mU/ml) and slightly elevated blood glucose (122 mg/dl; normal, 60–112 mg/dl); the hemogram, platelet count, and SMA-18 were otherwise normal. Chest roentgenogram, barium enema examination, serum protein electrophoresis, urinalysis, rapid plasma reagin, electrocardiograms, prothrombin time, and partial thromboplastin time were normal or negative.

The patient was treated with 3000 rad of 10-MeV x-rays to the left pelvis for 31 days, with a linear accelerator and with 6 courses of MOPP. The skin lesions responded at first but recurred following each course of MOPP; however, the pelvic mass and inguinal adenopathy resolved completely and have not recurred as of this writing.

In January 1980 the patient noted gradually increasing numbers of papules ranging from 3 to 6 mm, particularly on the head, neck, arms, and trunk, accompanied by intermittent pruritus (*Figs. 1 and 2*).

¹ Departments of Dermatology (J. E. B., W. F. B.) and Pathology (J. T. M., W. F. B., R. R. T.), The Cleveland Clinic Foundation. Submitted for publication Feb 1983; accepted March 1983.

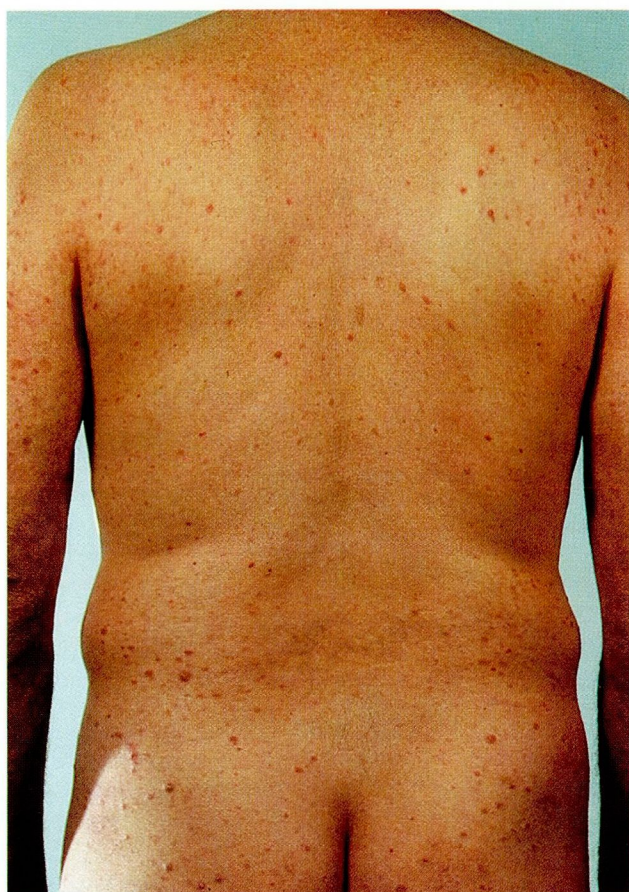

Figure 1. Clusters of salmon-pink papules on the trunk and arms.

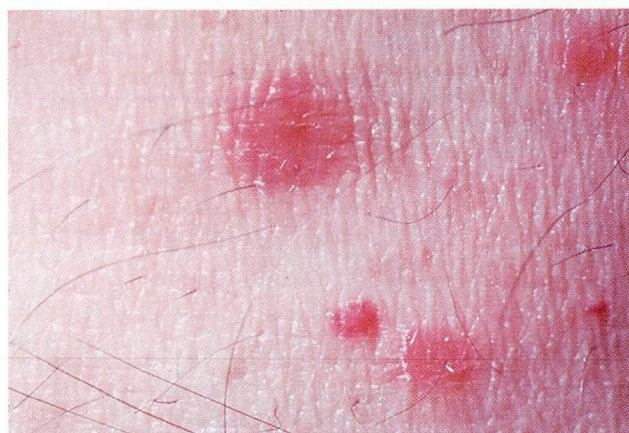

Figure 2. Solitary papule, showing absence of skin markings centrally.

In July 1980, total-body irradiation with 2400 rad of 6-MeV electrons for three months produced only minimal improvement as well as moderate radiation dermatitis. The patient has continued to have episodic clusters of papules without evidence of recurrent visceral disease.

Biopsy technique

Fresh skin biopsy specimens measuring $5.0 \times 5.0 \times 5.0$ mm were divided into three aliquots.

Table. T-cell-derived lymphomas

Small lymphocytes (T)
Convoluting lymphocytes
Cerebriform lymphocytes (Sézary syndrome, mycosis fungoides)
Immunoblastic sarcoma (T)
Lymphoepithelioid cell (Lennert's lymphoma)

One segment was fixed in B5, dehydrated in graded alcohols, embedded in paraffin, and stained with hematoxylin and eosin, periodic acid-Schiff, and methyl green-pyronine. The second segment was snap-frozen in isopentane at -150°C in liquid nitrogen and stored at -80°C . The third segment was diced into 1.0×1.0 mm cubes, fixed overnight in buffered glutaraldehyde, dehydrated in graded alcohols, Spurr-embedded, and fixed in osmium tetroxide. Thick sections stained with toluidine blue and semi-thin sections stained with lead citrate and uranyl acetate were examined in a Philips 400 transmission electron microscope.

The histologic sections were reviewed by three surgical pathologists, a laboratory hematologist, and a clinical oncologist. Tissue was evaluated for immunoglobulin light-chain expression and lymphocyte differentiation antigens by techniques described previously.^{4,5} Briefly, 8μ cryostat-frozen sections were air-dried on glass slides for 15 minutes, fixed in acetone for 10 minutes, allowed to dry in air at room temperature, and incubated with peroxidase-conjugated goat antibodies to κ and λ light chains for 10 minutes in an air-humidified chamber (Dako and Tago). After washing off the antisera with phosphate-buffered saline (PBS) (FTA hemagglutination buffer, BBL Laboratories), the slides were washed again briefly in PBS and subsequently in tris-HCl 0.1 M (pH, 7.6) for 30 seconds and the color reaction product was developed in Hanker-Yates reagent (HYR; p-phenylenediamine and pyrocatechol). The sections were then dehydrated in graded alcohols and xylene and mounted with Coverbond. Cryostat-frozen sections which had been fixed in acetone were incubated with monoclonal mouse hybridoma antibodies specific for circulating T cells (OKT3, PAN, Ortho Immunobiologicals) bearing E rosette receptors (T_{11} and B_1 , Coulter) for two hours in an air-humidified chamber. The sections were washed briefly in PBS, and affinity-purified peroxidase-conjugated goat antimouse IgG was overlaid on the tissue for 30 minutes. The antisera were washed from the slide with PBS, the

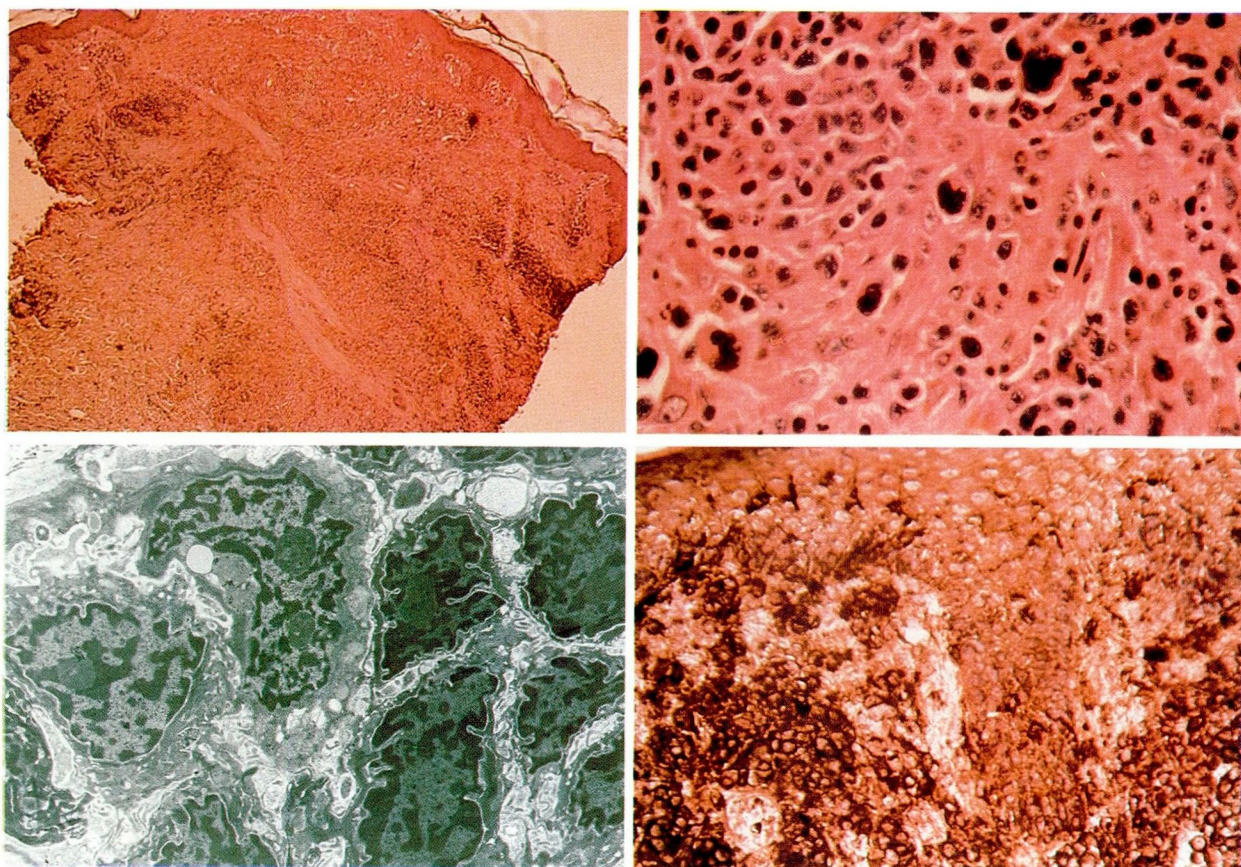


Figure 3. Punch biopsy specimen demonstrates a superficial deep perivascular infiltrate (hematoxylin and eosin, $\times 350$).

Figure 4. Dermal infiltrate containing multiple neoplastic giant cells and atypical lymphocytes (hematoxylin and eosin, $\times 1400$).

Figure 5. Electron microscopy demonstrates large lymphocytic cells with convoluted nuclei, multiple nucleoli, abundant cytoplasm, and free ribosomes.

Figure 6. Surface staining identifies two lymphocytes as a major component of the infiltrate (cryostat-frozen sections, immunohistochemistry, mouse monoclonal antibody OKT3 Pan, hematoxylin and eosin counterstain, $\times 875$).

slides first washed briefly in two changes of PBS and then for 30 seconds in one change of Tris-HCl buffer, and the color reaction product developed in HYR. Sections were counterstained with hematoxylin, dehydrated in graded alcohols and xylene, and mounted with Coverbond.

The skin biopsy specimen demonstrated a diffuse upper dermal infiltrate made up of atypical mononuclear cells, with perivascular prominence and focal epidermotropism (*Fig. 3*). Pautrier abscesses were absent. The mononuclear cells had large, hyperchromatic, folded and clefted nuclei, prominent nucleoli, and minimal cytoplasm, with a nuclear-to-cytoplasmic ratio of about 1:1 (*Fig. 4*). In addition, there were frequent neoplastic giant cells and multinucleated atypical cells; but no acute inflammatory cells.

Electron microscopy showed large, multilobulated mononuclear cells with multiple nucleoli and abundant cytoplasm, observed predomi-

nantly in the dermis and focally within the epidermis. These differed from typical Sézary cells, being larger, with fewer nuclear convolutions, more nucleoli, and increased cytoplasm, which in turn contained more free ribosomes (*Fig. 5*).

Immunohistochemistry studies with the use of cryostat-frozen sections, monoclonal hybridoma primary antibodies specific for T cells, and Ia antigens demonstrated positive staining of all neoplastic cells (*Fig. 6*); however, they were negative for immunoglobulin light chains and B₁. The immunohistochemical phenotype was T₃ +, T₁₁ +, Ia +, B₁ -, κ -, λ -, and the diagnosis was T-cell immunoblastic sarcoma.

Discussion

Well-documented cases of immunoblastic sarcoma of B-cell origin evolving from persistent antigen stimulation have been reported.^{6,7} Conditions seen in such patients include Sjögren's

syndrome,^{2,8,9} systemic lupus erythematosus,² Hashimoto's thyroiditis,^{2,10,11} α -chain disease,^{2,12} gluten-sensitive enteropathy,^{2,7} gastric ulcers,² chronic lymphocytic leukemia,⁷ renal transplant recipients,¹³ celiac disease,⁷ chronic urticaria,⁷ asthma,⁷ rheumatoid arthritis,⁷ and mixed-cellularity Hodgkin's disease.^{7,14,15} It may be assumed that immunoblastic T-cell sarcoma may also have developed in our patient over an 11-year period due to persistent antigen stimulation; or he may have had a deficiency of antigen recognition. Unfortunately, immunologic phenotyping was not performed on the specimens taken from the mass and lymph nodes in 1979, which were interpreted as Hodgkin's disease; however, we speculate that the patient had lymphoma, specifically T-cell immunoblastic sarcoma.

In view of our patient's dramatic visceral response to chemotherapy combined with the persistent eruption of the papular skin lesions, it is possible that IBS-T, like mycosis fungoides, Sézary syndrome, and subacute T-cell leukemia,¹⁶ is basically a cutaneous T-cell neoplasm.

Some reported cases of lymphomatoid papulosis bear a resemblance to the morphologic, cytologic, histopathologic, and relatively benign clinical features of cutaneous IBS-T. Lymphomatoid papulosis has been described as benign nodular cyclical T-cell proliferation within the skin, coexistent with mycosis fungoides.¹⁷ However, it has not been shown that these are transformed or blastic T cells. Other authors have documented coexistence with and progression to other forms of lymphoma.^{18,19} Immunoblastic sarcoma of T-cell origin may indeed represent the subset of lymphomatoid papulosis that is known to progress to true lymphoma. Although one form is characterized by larger, atypical mononuclear cells within the epidermis, epidermotropism is not a common feature of the disease as demonstrated in this case of T-cell immunoblastic sarcoma.

Summary

Although the clinical features of cutaneous T-cell lymphoma are not distinctive, the diagnosis may be suspected when asymptomatic, scattered 3–6mm salmon-pink papules are noted, and it can be established with immunohistochemistry and electron microscopy. In our patient, the skin lesions were intermittently responsive to electron-beam irradiation and chemotherapy. However, this patient has had episodic clusters of papules from 1968 through 1980, the last year

of follow-up. It was apparent on follow-up that the visceral mass was more susceptible to therapy than the cutaneous lesions. This case demonstrates that diagnosis of cutaneous lymphoreticular disorders should be based on light and electron microscopy and on immunohistochemical phenotypes.

References

1. Lukes RJ, Collins RD. Immunologic characterization of human malignant lymphomas. *Cancer* 1974; **34**:1488–1503.
2. Lukes RJ, Parker JW, Taylor CR, Tindle BH, Cramer AD, Lincoln TL. Immunologic approach to non-Hodgkin lymphomas and related leukemias; analysis of the results of multiparameter studies of 425 cases. *Semin Hematol* 1978; **15**:322–351.
3. Lukes RJ, Taylor CR, Parker JW, Lincoln TL, Pattengale PK, Tindle BH. A morphologic and immunologic surface marker study of 299 cases of non-Hodgkin lymphomas and related leukemias. *Am J Pathol* 1978; **90**:461–485.
4. Tubbs RR, Sheibani K, Weiss RA, Sebek BA. Immunohistochemistry of fresh-frozen lymphoid tissue with the direct immunoperoxidase technic. *Am J Clin Pathol* 1981; **75**:172–174.
5. Tubbs RR, Weiss RA, Savage RA, Sebek BA, Weick JK. Determination of immunologic phenotypes of large cell lymphoma using monoclonal antibodies. (Abstr) *Lab Invest* 1981; **44**:69-A.
6. Banik S, Ward RL, Hasleton PS. Immunoblastic lymphadenopathy; evolution into immunoblastic sarcoma. *J Clin Pathol* 1979; **32**:1110–1120.
7. Lichtenstein A, Levine AM, Lukes RJ, et al. Immunoblastic sarcoma; a clinical description. *Cancer* 1979; **43**:343–352.
8. Anderson LG, Talal N. The spectrum of benign to malignant lymphoproliferation in Sjögren's syndrome. *Clin Exp Immunol* 1972; **10**:199–221.
9. Talal N, Bunim JJ. The development of malignant lymphoma in the course of Sjögren's syndrome. *Am J Med* 1964; **36**:529–540.
10. Cureton RJR, Harland DHC, Hosford J, Pike C. Reticulosarcoma in Hashimoto's disease. *Br J Surg* 1957; **44**:561–566.
11. Woolner LB, McConahey WM, Beahrs OH. Struma lymphomatosa (Hashimoto's thyroiditis) and related thyroidal disorders. *J Clin Endocr* 1959; **19**:53–83.
12. Shahid MJ, Alami SY, Nassar VH, Balikian JB, Salem AA. Primary intestinal lymphoma with paraproteinemia. *Cancer* 1975; **35**:848–858.
13. Matas AJ, Hertel BF, Rosai J, Simmons RL, Najarian JS. Posttransplant malignant lymphoma; distinctive morphologic features related to its pathogenesis. *Am J Med* 1976; **61**:716–720.
14. Lukes RJ, Tindle BH. Immunoblastic lymphadenopathy; a hyperimmune entity resembling Hodgkin's disease. *N Engl J Med* 1975; **292**:1–8.
15. Fisher RI, Jaffe ES, Braylan RC, Andersen JC, Tan HK. Immunoblastic lymphadenopathy; evolution into a malignant lymphoma with plasmacytoid features. *Am J Med* 1976; **61**:553–559.
16. Uchiyama T, Todoi J, Sagawa K, Takatsuki K, Uchino H. Adult T-cell leukemia; clinical and hematologic features of 16 cases. *Blood* 1977; **50**:481–492.
17. Lutzner M, Edelson R, Schein P, Green I, Kirkpatrick C, Ahmed A. Cutaneous T-cell lymphomas; the Sézary syn-

- drome, mycosis fungoides, and related disorders. *Ann Intern Med* 1975; **83**:534-552.
18. Brehmer-Andersson E. Mycosis fungoides and its relation to Sézary's syndrome, lymphomatoid papulosis, and primary cutaneous Hodgkin's disease; a clinical, histopathologic and cytologic study of fourteen cases and a critical review of the literature. *Acta Derm Venereol* 1976; **56** (suppl 75): 1-142.
19. Black MM, Wilson Jones E. "Lymphomatoid" pityriasis lichenoides; a variant with histological features simulating a lymphoma; a clinical and histopathological study of 15 cases with details of long term follow up. *Br J Dermatol* 1972; **86**:329-347.