

The role of surgery in epilepsy¹

Joseph F. Hahn, M.D.

Surgery for the reduction or elimination of seizures in epilepsy is not a new therapeutic technique. The criteria for surgical candidates have evolved over the past 40 years so that individuals with epilepsy are not subjected to surgery unless it is considered beneficial after careful evaluation of the patient's condition. An intensive work-up by a multifaceted team at the Cleveland Clinic is performed for each patient referred for epilepsy surgery. Various techniques are considered and tailored for the individual. In the literature, the success rate for epilepsy surgery in markedly reducing or eliminating seizures is about 65%.

Index terms: Brain, surgery • Epilepsy
Cleve Clin Q 50:353-359, Fall 1983

In 1831 William Gowers¹ asked specific questions still pertinent today regarding the localization and etiology of epileptic seizures: (1) What is the seat of the discharge that thus produces the symptoms of the fit? (2) Is the seat of the discharge the seat of the disease? (3) How far does such discharge explain the symptoms of the attack? (4) What is the nature of the morbid change that causes the discharge? At present at least six neurosurgical procedures are used in the treatment of epilepsy: temporal lobectomy, cortical excisions in extratemporal regions, hemicortectomy, commissurotomy, stereotactic ablations, and chronic cerebellar stimulation.

Patient selection

Much has been written about the ideal candidates for

¹ Department of Neurological Surgery, The Cleveland Clinic Foundation. Submitted for publication April 1983; accepted June 1983.

neurosurgical procedures to relieve epilepsy. Of the generally accepted criteria, the first and most important is failure to respond to adequate trials of pharmacotherapy. Careful monitoring of the patient's serum for therapeutic levels of the various drugs is necessary. One cannot assume that the drug is not acting unless it is documented that the serum levels were not in the therapeutic range.

Several different drugs or combinations should be tried. If these trials fail, the patient may have epilepsy refractory to medical therapy. As new drugs are developed, more patients unresponsive to present agents may achieve control. A patient is not a candidate for surgery unless it is documented that his epilepsy is refractory to all available drugs, or that they are required in toxic doses.

A second criterion is that the seizure focus should be predominantly or entirely unilateral. The seizure should evolve from the same focus. If a seizure focus is identified in the temporal lobe, surgery will not be successful, unless the lesion is unilateral. If seizure foci appear in both temporal lobes, it is imperative to determine how often each focus leads to a clinical seizure. If one side is the predominant focus and produces seizures in a ratio of 4:1, the lesion may be surgically amenable to treatment. If seizures evolve with equal frequency from both temporal lobe foci, results following surgical lobectomy are not good.

A third criterion is that the lesion or focus should be in a surgically accessible site. If the lesion is located in the motor area, a monoplegia or hemiplegia would result from its removal. Patients with this problem are not good surgical candidates, but could benefit from one of the more unusual surgical procedures, such as commissurotomy, which will be discussed later.

A fourth criterion is that the seizures must have been occurring over a long period, approximately four to five years. A few patients with seizures of all types undergo gradual spontaneous reduction of seizure tendency in the late teens, whereupon they can be well controlled with medication. A second reason for waiting is that all epileptogenic areas will have become symptomatic.

Most patients coming to surgery are in the younger age groups, but the duration of the seizures does not reduce the likelihood of a successful result. Good results have been obtained

with patients in their fifties. However, the more severe and disabling the seizure disorder, the earlier surgical therapy should be considered.

Two other criteria not universally accepted are an IQ of at least 60, and exclusion of patients with tumors, arteriovenous malformations (AVMs), and abscesses.² At the Cleveland Clinic an IQ of 60 or less does not necessarily rule out surgery. Nursing care of these patients is easier if the seizures can be reduced or eliminated by surgery.

We agree that patients with brain tumors, AVM, and abscesses are not likely to benefit from surgery for epilepsy. However, occasionally there is a patient with a tumor in the anterior temporal lobe who would benefit from surgical resection. We are observing several such patients whose seizures have been markedly reduced by removing the glioma even though resection has not always been complete.

Patient evaluation

When a patient has been accepted as a possible candidate for seizure surgery, a protocol is instituted for his evaluation. As an outpatient, he has several electroencephalograms (EEGs) with the usual scalp electrodes. These recordings are done with and without medication and include sleep recordings as well as nasopharyngeal leads. In attempting to correlate the patient's seizure pattern with the EEG findings, it should be noted that the clinical pattern points to the area of lowest seizure threshold. The EEG provides more reliable evidence of the total extent of the epileptogenic area. Demonstration by EEG of a focal onset of ictal discharge in recording a spontaneous seizure best identifies the site of origin of an attack; interictal discharges are less reliable.

It is usually assumed that if repeated EEGs demonstrate an area from which interictal epileptogenic potentials consistently originate, this area corresponds to the most likely site of onset of the patient's spontaneously occurring seizures. This is not always true. Scalp recordings provide only limited information on the true dimensions of the patient's epileptogenic condition because only a portion of the cerebral cortex is accessible to this technique. The medial and inferior surfaces of the cerebral hemisphere, as well as the depths of the fissures and sulci, are inaccessible. Primary epileptic discharges originating in these areas may be missed altogether. Also, projected EEG signs originating from a distant area may be

recorded on the surface. An attempt should be made to record a seizure to ascertain the correct clinical site and to see whether this conflicts with the EEG localization.

Even if a seizure is recorded, the ictal record often cannot be interpreted because it is obscured by muscle potentials and movement artifact. Hence, some uncertainty remains about the actual site of seizure origin. Rapid spread over a large area, or rapid generalization of the seizure discharge, may also prevent identification of a focal onset. Interpretation of an ictal EEG requires careful analysis by a skilled electroencephalographer.

Frequently the interictal EEG fails to establish the presence of an epileptiform abnormality to provide localizing evidence. In such instances, attempts can be made to bring out latent seizure activity by withdrawing anticonvulsant medication. However, this may produce status epilepticus. A second alternative and easy maneuver is to have the patient hyperventilate. A third is to use intermittent photic stimulation, and a fourth is natural or drug-induced sleep. Drugs used for activation of seizure foci include pentylenetetrazol (Metrazol) or bemegride as well as intravenous methohexital (Brevital) in subanesthetic doses in patients with temporal lobe epilepsy.

Once these readings have been made, the patient is allowed to go home while the tracings are analyzed by our electroencephalography team. If the patient is a candidate for further evaluation, he is admitted to the hospital for the insertion of sphenoidal electrodes at some institutions, although we no longer do this. This is accomplished by inserting a platinum wire electrode into the region of the pterygoid plates at the base of the skull. The electrode is passed over the mandible and below the zygomatic process of the skull. These are left in place approximately four or five days and recordings made continuously. These electrodes will locate foci that are on the mesiobasal portions of the temporal lobes, which are inaccessible to the scalp electrodes and the nasopharyngeal electrodes. The patient is subsequently discharged, and again the data are analyzed. If the patient appears to be a suitable candidate, he is readmitted for the enlarged formal protocol (phase III), which includes insertion of depth, epidural, or subdural electrodes.

Each case is individualized and a map made of the most likely area of epileptic focus (Fig. 1). The neurologist and the electroencephalogra-

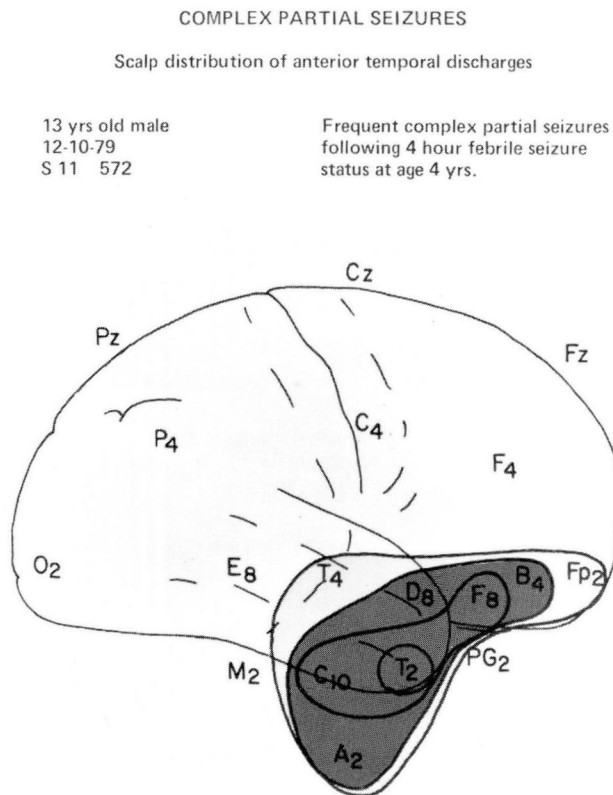


Fig. 1. Map of epileptic activity and spread over brain templates.

pher devise a plan whereby the surface of the brain nearest the focus will be covered with epidural and subdural electrodes (Fig. 2). Depth electrodes having four contacts on each post can also be used. If three posts are inserted, there will be 12 electrodes evaluating the depths of the brain (Fig. 3). These can be left in place for two to three weeks. Cables are brought out through




Fig. 2. Electrode plates for subdural and/or electrode usage.

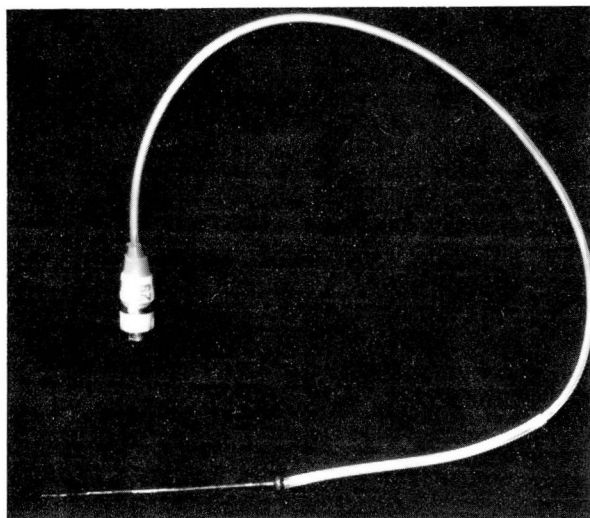


Fig. 3. Depth electrode.

the skin and the head dressing (Fig. 4). The patient is monitored by computer and TV videotapes. The computer is programmed to trigger the videotaping mechanism when a seizure begins. We are thereby able to analyze the exact focus of the epileptic activity and monitor its spread. This technique determines whether the focus is unilateral and spreads to the opposite side before becoming generalized, or remains unilateral; it has demonstrated that these patients often have continuous spike activity despite silent scalp and epidural recordings. We are studying the effect this continual electrical discharge may have on the functioning patient. For example, it may interfere with memory. These patients are not having overt clinical seizures, and at the time that the spike areas are noted, they are thought to be "normal." Recording goes on for approximately two to three weeks. We now use subdural electrodes instead of depth electrodes. If it appears the focus seems to be unilateral and surgically accessible, the patient moves on to phase IV, which includes neuroradiological studies as well as neuropsychological assessment. A CT scan, usually done early after the patient's admission, is analyzed for tumors, AVMs, etc. Normally no structural lesion is noted except for occasional dilation of the temporal horns. The prospective surgical candidate is then scheduled for a Wada test, the intracarotid injection of sodium amytal. Each carotid is injected on separate days, which eliminates the possibility that the drug may have spread to the opposite hemisphere and that the effects may be cumulative. Patients

are tested for speech and motor function and are given simple statements to read and objects to name. They are given a set of objects that they will be asked to recall after the test. This brief assessment of retention and recall helps to determine whether problems with memory may occur if surgical removal of the temporal lobe is attempted. This is the final step in the gathering information before analyzing benefits that might be gained from surgery.

In some parts of the country patients are scanned using positive emission tomography, which demonstrates the seizure focus in a two-dimensional picture by using biological markers. The focus stands out because of abnormal metabolic activity. This procedure, still experimental, is not in wide use. Nuclear magnetic resonance, still in the experimental phases, may be equally effective.

Surgical techniques

Hemispherectomy is effective in eradicating the seizure focus, but only infrequently are patients candidates for this procedure. In a series of 1100 patients reported by Rasmussen³ in 1969, only 29 had hemispherectomies. Overall success rate was 87%, the highest for any procedure, which is understandable because removal of the hemisphere includes all foci. Candidates for this procedure have infantile hemiplegia coinciding with focal seizure disorder on the appropriate side. Disadvantages of this operation are obvious. If the hemisphere removed is only partially damaged, the neurologic deficit would be increased. Delayed complications include hydrocephalus, ependymitis, and spontaneous bleeding into the ventricle or on the surface of the brain with deposition of hemosiderin. The latter, called cerebral hemosiderosis, may increase and form a mass. It may present as a brain tumor requiring removal. To circumvent this problem, we attempt to leave the frontal and occipital poles of the brain intact and not enter the ventricle during surgery.

Stereotactic ablations, another procedure for control of epileptic discharges, have been described by Talairach and Szikla.⁴

Narabayashi⁵ reported follow-up of 29 adult patients treated with stereotactic ablations of the medial amygdala who had severe behavioral as well as epileptic problems. These procedures occurred over 21 years. He demonstrated that severe behavioral problems in epileptic patients,

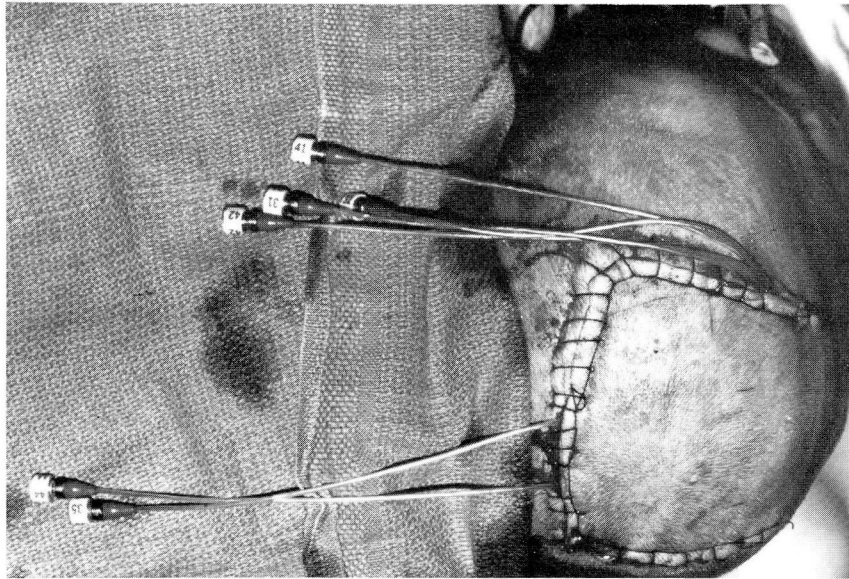


Fig. 4. Electrode cable coming through skin.

such as uncontrollable violent outbursts of temper and easy excitability or lability in mood, are benefited by this procedure. Data are presented on 18 patients. Eleven were able to return to productive work. Eight greatly improved emotionally and had far fewer clinical seizures. No adverse psychological, intellectual, or autonomic side effects were noted in any of his patients with bilateral amygdectomy. No disturbance of memory or evidence of the Klüver-Bucy syndrome occurred. Narabayashi concluded that amygdaloid surgery reduces seizures and behavioral problems associated with epilepsy when all other pharmacological or conservative treatment has failed. It cannot solve behavior problems of unknown etiology such as major psychoses or psychoneuroses.

Cerebellar stimulation has received considerable exposure in the medical and lay press in the last five years. It was thought that repetitive stimulation of the surface of the cerebellum was followed by a variable sequence of events depending on rate of stimulation, pulse duration, intensity of stimulation, and length of the stimulus train.

In 1973, Cooper et al⁶ described 8 patients with intractable epilepsy treated with cerebellar stimulators. Five of the 8 improved markedly, 2 only slightly, and one not at all. Eight electrodes are placed on the superior surface of the left and right anterior lobe of the cerebellum and connected to a radiofrequency receiver implanted subcutaneously on the chest wall. An external

battery powered transmitter generates a predetermined pulse radiofrequency signal. At present the efficacy of these stimulators is being challenged. At the Cleveland Clinic we have stopped inserting cerebellar stimulators in patients with intractable epilepsy. In past cases, we have not noticed any change in the seizure pattern, existing prior to insertion.

Cerebral commissurotomy for control of intractable seizures has recently been redescribed by Wilson et al.⁷ Seizure focus may be bilateral or inaccessible. The corpus callosum is sectioned. Ten patients underwent partial or complete commissurotomy. Complete commissurotomy is the division of the entire corpus callosum, one fornix, and the anterior commissure. Partial commissurotomy is the division of the anterior commissure, one fornix, and the anterior half of the corpus callosum. No patients were worse with surgery. Surgery seemed most effective in patients with obvious unilateral brain damage. Invasion of the ventricular system was hazardous, producing both aseptic ventriculitis and hydrocephalus.

An acute disconnection syndrome occurred in almost all patients. It is characterized by mutism, bilateral grasp reflexes, bilateral Babinski responses, and focal motor seizures on alternating sides without loss of consciousness. Confusion, lack of concentration, and regression to childish behavior may occur in varying degrees. These symptoms gradually resolved and did not present a long-term problem. Of 8 patients studied by

Wilson et al, 6 were listed as improved to "excellent," and one is "poor," requiring nursing home care. One death occurred 12 days after surgery in a patient who had been making a seemingly excellent recovery. Autopsy showed a hemorrhagic infarct of the right frontal lobe.

Corticectomy and lobectomy. The largest group of surgical candidates have a focus in the temporal lobe or other cortical areas. Rasmussen⁸ reported that slow-growing tumors and vascular malformation were present in approximately 20% of the patients having cortical excisions. Brain scarring, gliosis, or atrophy as a result of birth trauma or anoxia accounted for 27% of the nontumoral cases. Postnatal head trauma accounted for 21% and postinflammatory brain scarring for 15%. The cause was unknown in 29%. These patients had temporal lobectomies or cortical excisions in extratemporal locations. These locations, thought to be surgically accessible, may include frontal, parietal, and occipital areas. Removal of an epileptic focus in the motor area without producing deficit would be difficult, if not impossible.

Rasmussen⁸ reviewed approximately 1400 patients in the nontumoral case series; 1277 patients, observed for two years or longer, served as the basis for his report. Nineteen percent have had no seizures since discharge. Another 14% have remained seizure-free after having a few seizure episodes in the early postoperative period. Therefore, approximately 33% of this group with medically refractory epilepsy became seizure-free after cortical resection. Another 13% have had a late recurrence of occasional attacks after being seizure-free for from three to 25 years. Nineteen percent, or 240 patients, have had less than 1% to 2% as many attacks compared to the preoperative rate and only one to three attacks per year. These two groups, or 32% of the follow-up group, have had a marked reduction in seizure tendency. Therefore, 65% have had a complete or nearly complete reduction of seizures following cortical resection. Only a small minority have had no relief from their seizure problems.

Discussion

We have learned several things in analyzing this group of patients. Surgical removal should be as complete as possible. If resection is confined to the lowest area of seizure threshold, a good

result is less likely. Rasmussen and we have both noted this. Effectiveness of cortical resection is about the same regardless of anatomical area involved as long as resection is maximal. Cortical resections limited to the temporal lobe of one cerebral hemisphere were performed in approximately 50% of Rasmussen's patients. Resection resulted in a complete or nearly complete reduction in seizure frequency in 71% of patients. Statistics were similar for the smaller anatomical groups, namely cortical resections involving the frontal, central, parietal, and occipital areas of the brain. Rasmussen contends that effectiveness of cortical resection and treatment of medically refractory focal epilepsy are correlated primarily with complete removal of the epileptogenic cortex rather than with anatomical location of the epileptogenic area of the brain or with underlying cause of original brain damage. His series is one of the largest ones reported. The temporal lobes are easily accessible; hence many patients with refractory seizures from this area are candidates for surgical intervention. Complete or nearly complete reduction of seizure frequency occurs in 65% to 70% of patients.

In summary, patients who may benefit from surgery include: (1) those with a seizure pattern that indicates a discharging lesion in a localized, surgically accessible area of the brain; (2) those in whom serial EEGs supplemented by special studies localize this epileptogenic area; (3) those in whom clinical and laboratory evidence suggests a clinical lesion as the cause of the seizures; (4) those in whom intensive treatment with anti-convulsant drugs, verified by adequate blood levels, is ineffective in controlling seizures and enabling the patient to lead a normal productive life; and (5) those whose physical status allows them to undergo a major surgical procedure without undue risk. These criteria all fit the questions originally posed by William Gowers in 1881.

References

1. Gowers W. *Epilepsy and Other Convulsive Disorders: Their Causes, Symptoms, and Treatment*. London: Churchill, 1881.
2. Editorial. Surgery for epilepsy. *Br Med J* 1976; **1**:924.
3. Rasmussen T. The role of surgery in the treatment of focal epilepsy. *Clin Neurosurg* 1969; **16**:288-311.
4. Talairach J, Szikla G. Stereotactic neuroradiological concepts applied to surgical removal of cortical epileptogenic areas. [In] Rasmussen T, Marino R Jr, eds. *Functional Neurosurgery*. New York: Raven Press, 1979, pp 219-242.
5. Narabayashi H. Long-range results of medial amygdalotomy on epileptic traits in adult patients. [In] Rasmussen T, Marino

- R Jr, eds. *Functional Neurosurgery*. New York: Raven Press, 1979, pp 243–252.
6. Cooper IS, Amin I, Riklan M, Waltz J, Poon T. Chronic cerebellar stimulation in epilepsy. *Arch Neurol* 1976; **33**:559–570.
 7. Wilson DH, Reeves A, Gazzaniga M, Culver C. Cerebral commissurotomy for control of intractable seizures. *Neurology* 1977; **27**:708–715.
 8. Rasmussen T. Cortical resection for medically refractory focal epilepsy: results, lessons, and questions. [In] Rasmussen T, Marino R Jr. *Functional Neurosurgery*. New York: Raven Press: 1979, pp 253–269.