

Meniscofluoresis: an aid in determining prognosis of meniscal tears¹

Gary S. Fanton, M.D.²
Jack T. Andrish, M.D.

Until recently, it was believed that tears of knee menisci were incapable of healing. However, experimental and clinical evidence has now confirmed that some meniscal tears can be surgically repaired, particularly those around the periphery of the meniscus. Blood vessels penetrate that peripheral rim to a variable depth, from 10% to 25% of the meniscal substance. Although this blood supply is thought to be related to healing potential, it is difficult to determine clinically the extent of vascularization. Fluorescein is a relatively nontoxic dye long used in determining viability of skin flaps. When injected into the vascular system, it fluoresces under exposure to ultraviolet light. This is a highly consistent and accurate predictor of vascular integrity and tissue viability. We found that fluorescein dye can penetrate the vascular portion of the dog meniscus and fluoresce under exposure to ultraviolet light. Meniscal tears surgically created in the fluorescent portion of the meniscus healed, whereas those in the nonfluorescent portion did not. Intravenous use of fluorescein dye may be a safe and efficacious method of determining which meniscal tears might best be managed by repair rather than excision.

Index terms: Meniscus, injuries • Meniscofluorescence
Cleve Clin Q 50: 379–383, Winter 1983

¹ Department of Orthopaedic Surgery, The Cleveland Clinic Foundation. Presented at the meeting of the Orthopedic Research Society, Anaheim, CA, March 1983, and to the International Society of the Knee, Scotland, April 1983. Submitted for publication in Aug 1982; accepted Nov 1982.

² Present address: 26757 Menominee Place, Rancho Palos Verdes, CA 90274.

The functions of the knee menisci have been extensively investigated. These functions include (1) load transmission and energy absorption, (2) joint lubrication and synovial fluid distribution, (3) provision of joint stability, and (4) assistance in complex rotary motions of the knee joint.¹⁻⁴ Investigators have shown that preservation of meniscal substance appears to maintain at least some of these functions and decreases both short-term and long-term morbidity.^{1,3,5-7} Most of these studies emphasize the degenerative

changes that occur in the underlying articular cartilage after traditional meniscectomy. Thus, emphasis has shifted from total meniscectomy to partial meniscectomy or even meniscal repair when feasible.^{8,9}

Meniscal tears of the knee joint have a limited ability to heal.¹⁰ In 1885, Thomas Annandale reported the first case of successful meniscal repair when he sutured the torn anterior portion of a medial meniscus to its former position.¹¹ In 1936, King¹⁰ demonstrated that tears that communicate with the synovial periphery of the meniscus heal with a fibrovascular scar, but those entirely within the substance of the meniscus probably never heal. He related this to the poor blood supply found in the meniscal substance. Arnoczky¹² further demonstrated that the peripheral 10%–15% of dog meniscus is vascularized by a dense perimeniscal capillary plexus. This blood supply contributes to the connective tissue healing of the meniscal lesion.

Clinically, it is difficult to determine how much of the periphery of the meniscus has an intrinsic blood supply. Fluorescein is a relatively nontoxic dye that, when administered intravenously, rapidly diffuses into the extracellular space. The dye absorbs light in the ultraviolet range (maximum 3500–4000 Å) and emits light in the visible range

with a yellow hue.¹³ Thus, after intravenous administration of fluorescein, all vascularized tissue appears bright yellow under exposure to ultraviolet light. It has long been used by plastic surgeons as a safe and reproducible method of determining adequacy of tissue blood supply.^{13–15}

The objectives of this study are: (1) to determine if intravenous injection of fluorescein dye can be used as a method to evaluate vascularity of the knee meniscus in dogs, and (2) to determine if the area penetrated by fluorescein dye can be useful as a predictor of successful meniscal healing.

Materials and methods

Twelve adult dogs were used to evaluate the use of fluorescein dye in meniscal lesions. The dogs were anesthetized and both knee joints exposed through standard anteromedial incisions. The fat pad and synovial attachments were preserved. No tourniquet was used. Each dog was given an intravenous injection of 10% fluorescein dye (20 mg/kg). Fifteen minutes later the menisci were examined with the use of a long-wave (3500 nm) ultraviolet lamp. The fluorescent periphery of the anterior horn of the medial meniscus was identified. A transverse or longitudinal full-thickness cut was then surgically created in the meniscus. The transverse tears were of two types, either entirely located within the nonfluorescent substance of the meniscus, or extending peripherally to the area of fluorescence but not into the synovium or ligamentous attachments. The longitudinal tears were made entirely within the fluorescent or nonfluorescent zone (*Table 1*). Four dogs were sacrificed at intervals of 4, 8, or 12 weeks postoperatively by an overdose of barbiturates. Each dog was given a repeat dose of fluorescein dye immediately before sacrifice. The menisci were removed, photographed under ultraviolet light, and studied for both stability and histologic (hematoxylin and eosin stain) healing of the lesion. Six menisci were cross-sectioned immediately after sacrifice to determine the depth of penetration of the fluorescein dye. In four knees, the microvasculature was examined with the use of 50 cc of India ink injected intra-arterially immediately before sacrifice.

Results

Of the 12 dogs originally studied, one was eliminated for technical reasons. In another dog, one knee was excluded because the peripheral attachment of the meniscus was accidentally in-

Table 1. Types of medial meniscus tears made, based on zone of fluorescence

| Type of lesion | Location of lesion | Number of menisci |
|-------------------|---|-------------------|
| Longitudinal tear | Fluorescent zone | 8 |
| | Nonfluorescent zone | 6 |
| Transverse tear | Through nonfluorescent zone into fluorescent zone | 6 |
| | Nonfluorescent zone only | 4 |

Table 2. State of gross and microscopic healing based on location of tear

| Type of lesion | Gross healing | Microscopic healing | Number of menisci |
|-----------------------------------|-------------------|---------------------|-------------------|
| Longitudinal fluorescent zone | Complete | Present | 8 |
| Longitudinal non-fluorescent zone | None | Absent | 6 |
| Transverse to nonfluorescent zone | Peripherally only | Peripherally only | 4 |
| Transverse to nonfluorescent zone | None | Absent | 3 |

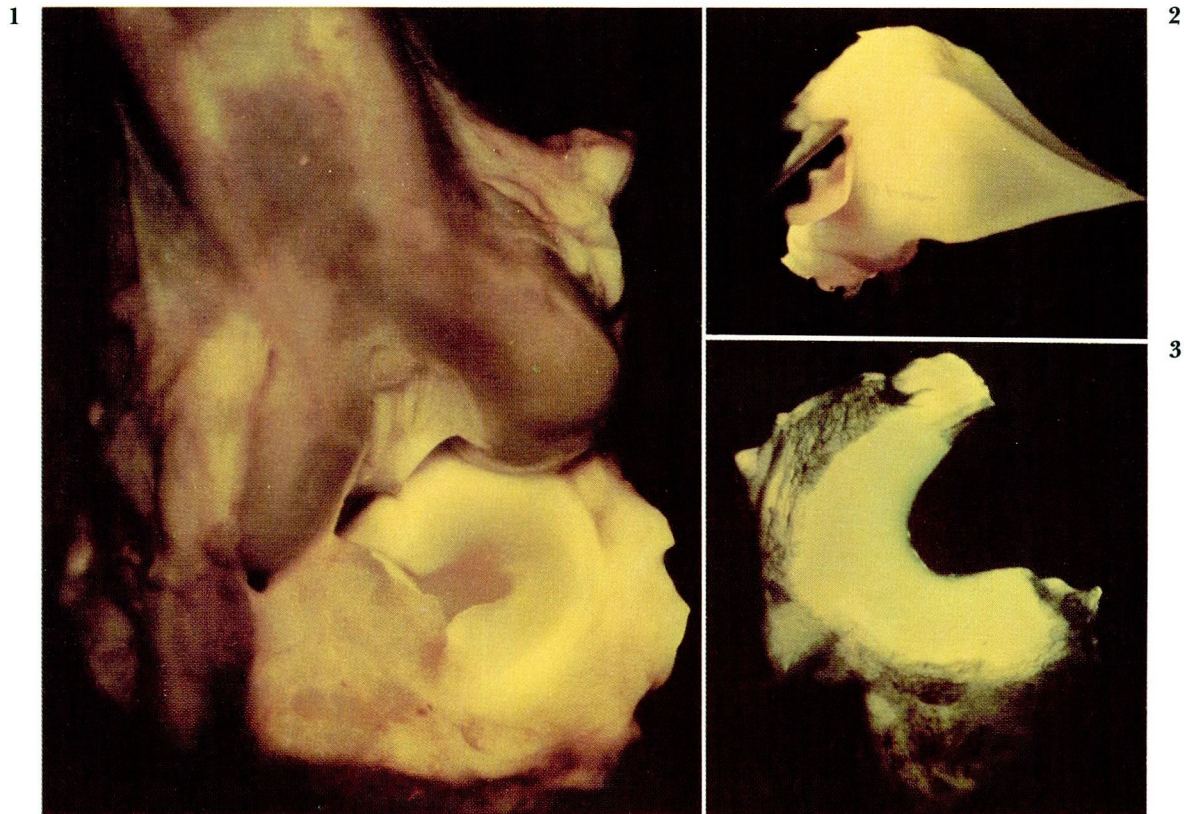


Fig. 1. Ultraviolet photographs of dog knee illustrating fluorescent rim of right medial meniscus.

Fig. 2. Cross section of meniscus photographed under ultraviolet light.

Fig. 3. Ultraviolet photograph of meniscus studied with both India ink and fluorescein. Note halo of fluorescence surrounding areas of India ink penetration.

cised. This left 21 knees in 11 dogs that were examined (*Table 2*).

In all cases, the synovial margin fluoresced brightly and extended into the peripheral 5%–15% of the substance of the meniscus (*Fig. 1*). There was a moderate degree of variation in the width of the fluorescent zone between dogs, but not between different knees in the same dog. The six menisci that were cross-sectioned showed penetration of the fluorescent dye from the periphery up to approximately 15% of the meniscal substance (*Fig. 2*). This seemed to correlate well with the India ink injection studies performed in four knees (*Fig. 3*).

Grossly, all longitudinal tears created in the fluorescent zone were completely healed as early as four weeks postoperatively (*Fig. 4*). The defects were stabilized by a translucent scar with minimal synovial proliferation. Longitudinal tears created in the nonfluorescent zone showed no evidence of healing either grossly or microscopically. The lesions could easily be separated with a blunt probe (*Fig. 5*).

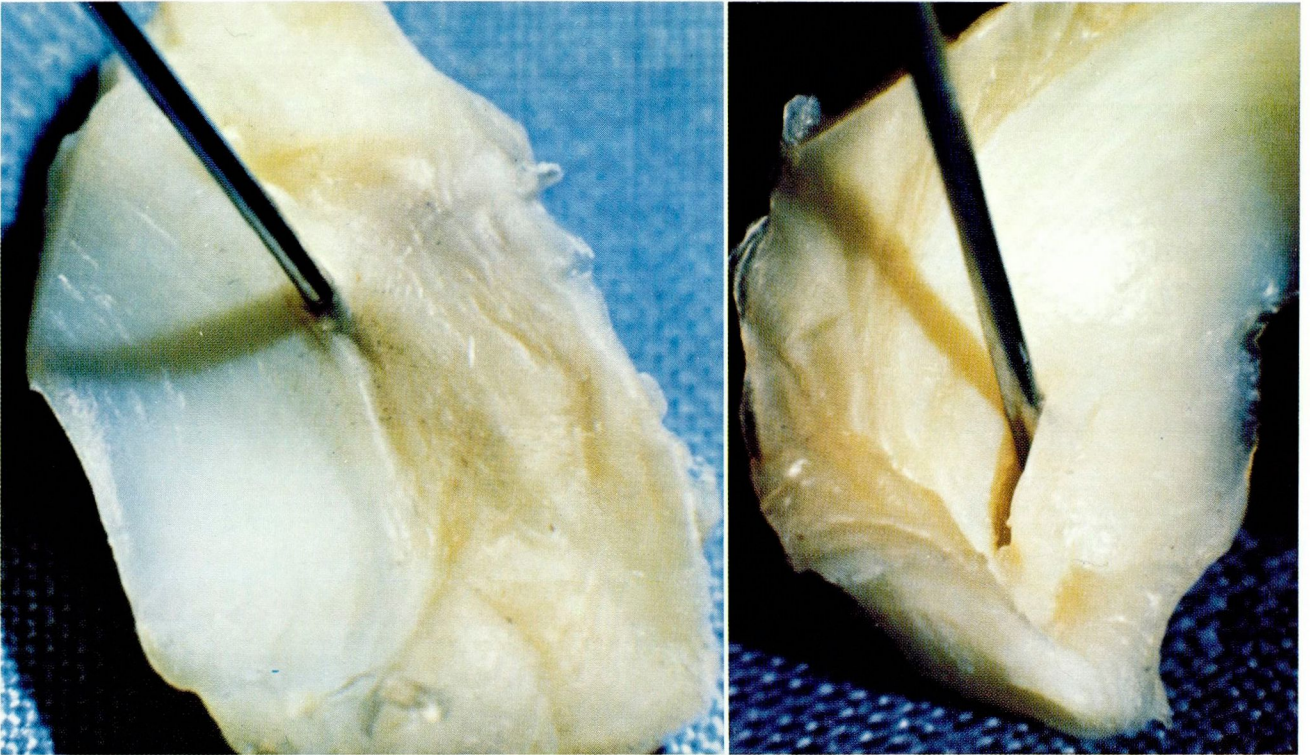
The degree of healing of transverse meniscal tears correlated well with the distance that the lesion extended into the fluorescent zone. All transverse tears extending into the fluorescent zone, but not into the synovium, showed excellent healing and stability only in the area of fluorescence (*Fig. 6*). Transverse tears in the nonfluorescent zone did not heal (*Fig. 7*).

Histologically, the degree of fibrovascular ingrowth correlated well with the region of gross healing and stability. This was characterized by random collagenization and vascular proliferation in those tears that involved the fluorescent zone. Longitudinal tears and transverse tears in the nonfluorescent zone showed little microscopic evidence of repair and no neovascularization.

Discussion

Previous microvascular studies have shown that the meniscus derives a majority of its nutrition from the perimeniscal vessels that arise from both the synovium and from an intrinsic capillary

4, 5



6, 7

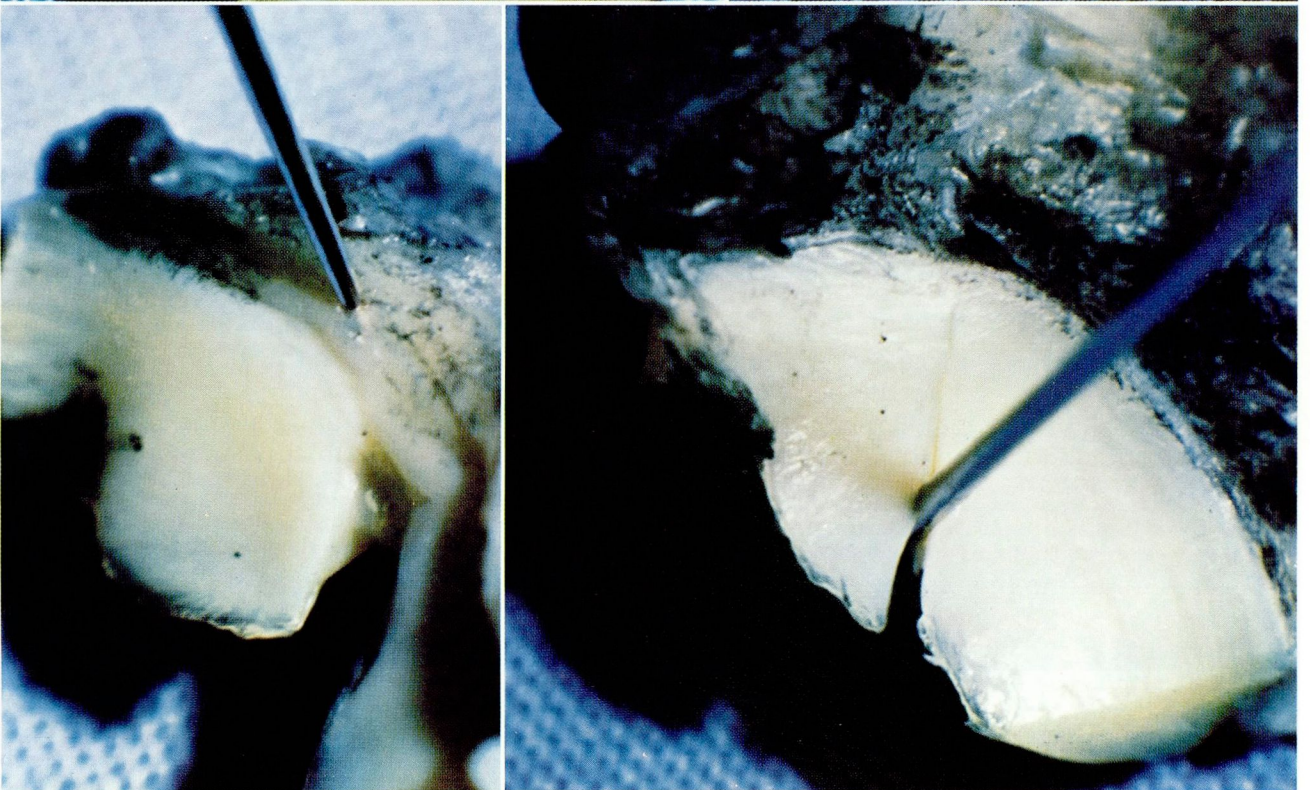


Fig. 4. Healed longitudinal tear previously made in fluorescent zone of meniscus (four weeks). Probe is at end of tear.

Fig. 5. Unhealed longitudinal meniscal tear previously made in nonfluorescent zone (eight weeks).

Fig. 6. Transverse meniscal tear extending into fluorescent zone, but not to synovium (12 weeks). Note peripheral healing adjacent to probe.

Fig. 7. Transverse meniscal tear previously made in nonfluorescent zone (12 weeks). No evidence of healing.

plexus.^{12,16} These supply the peripheral 10%–15% of the meniscus. The vessels are oriented in a predominantly circumferential pattern with radial branches being directed at a variable distance toward the center of the meniscus. The remainder of the meniscus derives nutrition from diffusion of synovial fluid.¹² However, this appears to be slow and limited to a depth of less than 1 mm from the meniscal surface. Meniscal tears that occur in this zone of poor nutrition have little ability to heal.¹⁰ However, those tears that extend into the synovial periphery of the meniscus heal with a fibrovascular scar that extends from the periphery inward and stabilizes the tear.^{8,10,16} In King's¹⁰ study this appeared to protect the articular cartilage from degenerative changes.

In our study, we found that the intravenous injection of fluorescein dye is a useful method of determining the intrinsic vascularity of the dog's knee meniscus. The rim of fluorescence in the meniscal substance appears to correlate well with previous anatomic studies that define the precise meniscal blood supply. This also correlated with the extent of India ink penetration observed grossly in four knees. Surgically created tears contained in the fluorescent zone of the meniscus healed, but those in the nonfluorescent substance did not. An attempt was made to create the lesions in the meniscus proper, avoiding communication with the synovium or ligamentous attachments. This was successful in 21 of 24 knees. The gross and histologic state of these healing lesions compared closely to Cabaud's⁸ findings in similar meniscal lesions that were surgically repaired. The zone of fluorescence was variable from dog to dog, ranging from 5%–15% of the outer rim, but consistent between different knees in the same dog. This may suggest that there is significant anatomic variation in the penetration of the capillary network among individuals and perhaps, therefore, a difference in healing potential.

Over the past decade it has become evident that the menisci of the human knee joint are vital biomechanical structures. Premature degenerative arthritis is a frequent sequella after meniscectomy. Meniscal preservation, therefore, appears to be the better alternative.^{5–7} Intravenous injection of fluorescein dye may be a safe and efficacious method of determining which meniscal tears have the ability to heal and might best be managed by conservative methods or repair rather than excision.

Conclusion

Intravenous injection of fluorescein dye is a useful method of evaluating the blood supply and, therefore, the healing potential of various regions of the dog knee meniscus. Maximum fluorescence in the outer 5%–15% of the meniscal substance correlated well with previous anatomic studies that define the microvasculature of the cartilage. Meniscal lesions that extend into the zone of fluorescence healed with a fibrovascular scar that stabilized the tear. Lesions created entirely outside the fluorescent zone did not heal. There appears to be a substantial variability in the size of the fluorescent zone between individual animals that might suggest anatomic differences in blood supply and, therefore, healing potential.

References

1. Cargill A, Jackson JP. Bucket-handle tear of the medial meniscus; a case for conservative surgery. *J Bone Joint Surg* 1976; **58A**:248–251.
2. Helfet AJ. Mechanism of derangements of the medial semilunar cartilage and their management. *J Bone Joint Surg* 1959; **41B**:319–336.
3. King D. The function of semilunar cartilages. *J Bone Joint Surg* 1936; **18**:1069–1076.
4. Krause WR, Pope MH, Johnson RJ, Wilder DG. Mechanical changes in the knee after meniscectomy. *J Bone Joint Surg* 1976; **58A**:599–604.
5. Cox JS, Nye CE, Schaefer WW, Woodstein IJ. The degenerative effects of partial and total resection of the medial meniscus in dogs' knees. *Clin Orthop* 1975; **109**:178–183.
6. Dandy DJ. Early results of closed partial meniscectomy. *Br Med J* 1978; **1**:1099–1100.
7. McGinty JB, Geuss LF, Marvin RA. Partial or total meniscectomy; a comparative analysis. *J Bone Joint Surg* 1977; **59A**:763–766.
8. Cabaud HE, Rodkey WG, Fitzwater JE. Medial meniscus repairs; an experimental and morphologic study. *Am J Sports Med* 1981; **9**:129–134.
9. Wirth CR. Meniscus repair. *Clin Orthop* 1981; **157**:153–160.
10. King D. The healing of semilunar cartilages. *J Bone Joint Surg* 1936; **18**:333–342.
11. Annandale T. An operation for displaced semilunar cartilage. *Br Med J* 1885; **1**: 789.
12. Arnoczky SP, Marshall JL, Joseph A, Jahre C, Yoshioka M. Meniscal nutrition; an experimental study in the dog. *Trans Orthop Res Soc* 1980; **5**: 127.
13. McGraw JB, Myers B, Shanklin KD. The value of fluorescein in predicting the viability of arterialized flaps. *Plast Reconstr Surg* 1977; **60**:710–719.
14. Myers MB. Prediction of skin sloughs at the time of operation with the use of fluorescein dye. *Surgery* 1962; **51**:158–162.
15. Thorvaldsson SE, Grabb WC. The intravenous fluorescein test as a measure of skin flap viability. *Plast Reconstr Surg* 1974; **53**:576–578.
16. Arnoczky SP, Travin GB, Warren RF, Snyder SJ. The microvasculature of the meniscus and its response to injury; an experimental study in the dog. *Trans Orthop Res Soc* 1981; **6**:177.