

Congenital anomalies of the lung in the adult¹

Atul C. Mehta, M.D.
Muzaffar Ahmad, M.D.
Joseph A. Golish, M.D.
Edward Buonocore, M.D.

A significant number of congenital anomalies of the lung manifest for the first time in adulthood. Patients may present with an incidental finding on a routine chest radiograph or with symptoms related to some complication of the anomaly. Such late presentation and an uneventful history may mislead the clinician to consider only acquired rather than congenital disorders. This paper is a concise guide to the diagnosis of congenital anomalies of the lung in adults without surgical intervention.

Index terms: Lung, abnormalities

Cleve Clin Q 50: 401-416, Winter 1983

Congenital anomalies of the lungs are numerous, but most are either too severe to be compatible with life, or too minute to achieve clinical significance. Most cases present in the newborn period or in early childhood with typical signs, symptoms, and radiographic findings. We will discuss congenital anomalies that may first become manifest in the adult, either with related symptoms or as an incidental radiographic finding. The purpose of this presentation is the recognition and diagnosis of these anomalies without surgical intervention.

There is no satisfactory classification that includes and groups all congenital anomalies of the lung, but for practical purposes, they may be classified as follows:

Congenital anomalies of the lung

1. Anomalies of lobation
2. Anomalies of the bronchi

¹ Departments of Pulmonary Diseases (A.C.M., M.A., J.A.G.) and Radiology (E.B.), The Cleveland Clinic Foundation. Submitted for publication June 1983; revision accepted July 1983.

1 A, B

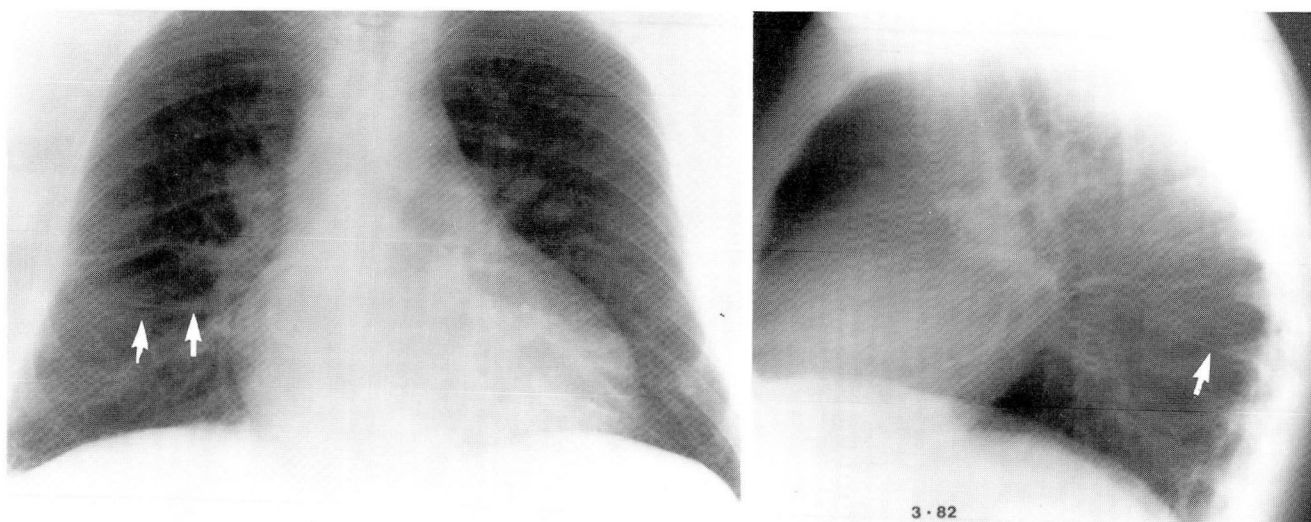


Fig. 1. A and B. Dorsal lobe of the lung produced by an accessory fissure (arrows) between superior segment and rest of the right lower lobe (incidental finding in a 55-year-old man).

3. Anomalies of the parenchyma
4. Anomalies of the pulmonary vessels

Anomalies of lobation

1. Supernumerary fissures
2. Subnumerary fissures
3. Fissures due to displaced structures
 - (a) Lobe of azygos vein
 - (b) Fissure by the subclavian artery.

Anomalous fissures are the most common congenital anomaly involving the lungs, with the least clinical significance.¹ They are rarely associated with symptoms; however, they may cause a diagnostic dilemma on chest radiographs, for example, a collection of fluid in the accessory fissure producing pseudotumor in an unusual location.

Minor developmental deviations such as variations in the number of the lobes and fissures are so common that they are almost a rule rather than an exception.^{1,2}

The most common major supernumerary fissure anomaly is trilobation of the left lung, in which the lingula is separated from the rest of the upper lobe. It has been found in 8% of all routine examinations.³

Inferior accessory lobe: A lobe created by a supernumerary fissure between the medial basilar segment and the rest of the right lower lobe is called an inferior accessory lobe. It has also been referred to as a retrocardiac or lower azygos lobe and has been reported to be present in 30% to 45% of all individuals.^{4,5}

Dorsal lobe of the lung: An accessory fissure between the superior segment and the rest of the lower lobe creates an extra lobe, which is referred to as a dorsal lobe, occurring in about 35% of individuals. Usually it involves the right lung (60%), but it may also be bilateral (14%)^{4,6} (Fig. 1).

In contrast to the supernumerary fissures, subnumerary fissures have significant clinical importance, especially during lobectomy. The most common subnumerary fissure anomaly is bilobation of the right lung. According to Kent's study of 277 autopsy cases, a minor fissure was found to be absent in 21% of the specimens, whereas it was incomplete in 67% of the cases. Incomplete right or left major fissures were found in 30% of the cases.⁷

Lobe of the azygos vein: During embryogenesis, if the right lung grows posterior to the posterior cardinal vein, it forms an accessory fissure or a venous indentation. The posterior cardinal vein eventually becomes the azygos vein, and the portion of lung medial to this vein acquires the name of "azygos lobe." The azygos vein remains embedded in the right lung, covered by the four layers of the pleura, forming an accessory fissure which can be seen in 0.4% to 1% of all routine chest radiographs.^{6,8} In the event of pneumothorax, these layers of the pleura do not separate. The bronchial supply of the azygos lobe is variable.⁹ Rarely, it originates from the left side of the aorta⁶ (Fig. 2).

The incidence of fissure created by the subcla-

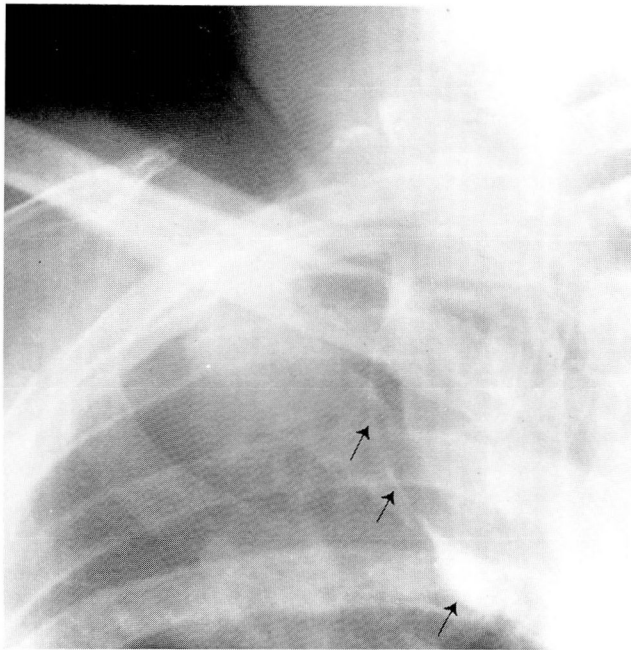


Fig. 2. Characteristic configuration of azygos fissure and vein (arrows) in an asymptomatic individual.

vian artery is much lower than that created by the azygos vein.

Anomalies of the bronchi

The lungs begin to develop as a ventral out pouching from the foregut, which is called the "lung bud." This continues to elongate, divide, and recruit alveoli until the child reaches eight years of age. Any disturbance to this branching process during intrauterine life eventually leads to an anomaly of the bronchi. Most findings observed during bronchoscopy are usually normal variations and are not clinically significant. The most common true anomaly is the supernumerary bronchus to the right upper lobe.¹⁰ The accessory right upper lobe bronchus can arise anywhere from the right lateral wall of the trachea and usually produces no symptoms. At times, it merely represents a displaced bronchus of the apical lobe. It becomes clinically relevant during right upper lobectomy. The exact incidence of this entity is not known (Fig. 3).

A subgroup of conditions related to the congenital segmentations of the bronchi is the group of congenital cystic diseases of the lung. This can be further classified as follows:

- (1) Solitary bronchogenic cysts
- (2) Multiple cysts
 - (a) Cystic bronchiectasis

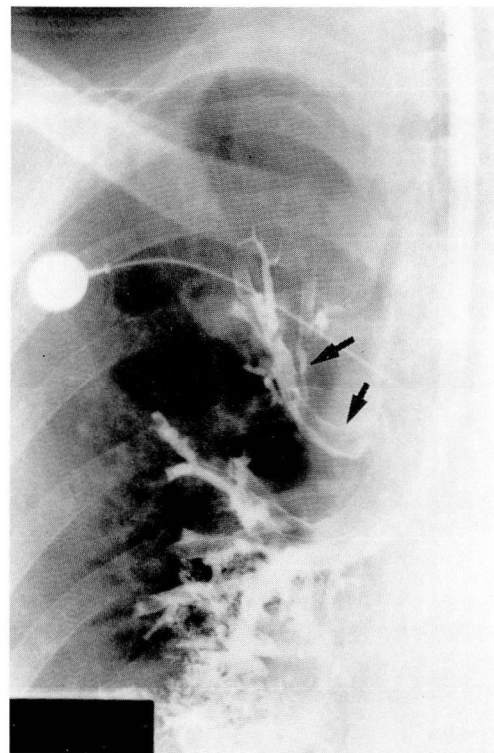


Fig. 3. Accessory bronchus to right upper lobe (arrows), an incidental finding in a patient with bronchiectasis. Bronchograms also demonstrate main right upper lobe bronchus and its three subsegments.

(b) Congenital adenomatoid malformation

(3) Lobar emphysema of the newborn

Solitary bronchogenic cysts: Bronchogenic cysts embryologically share their origin with esophageal cysts or duplication cysts, and posterior mediastinal cysts, which are usually associated with spinal cord anomalies.¹¹ Bronchogenic cysts probably arise between the 26th and 40th days of intrauterine life, when rapid tracheobronchial tree development and division take place, during which time any portion of the lung bud may become detached to form a bronchogenic cyst. Bronchogenic cysts have been found in embryos 50 to 60 days old, supporting the above hypothesis.^{12, 13}

For unknown reasons, bronchogenic cysts are more common in males and Yemenite Jews.^{14, 15} According to location, they can be classified into two broad categories, parenchymal cysts and mediastinal cysts. Bronchogenic cysts occurring within or beneath the diaphragm are rare.¹⁶

Mediastinal cysts: The incidence of mediastinal cysts has been reported at between 30% and 86%

4 A, B

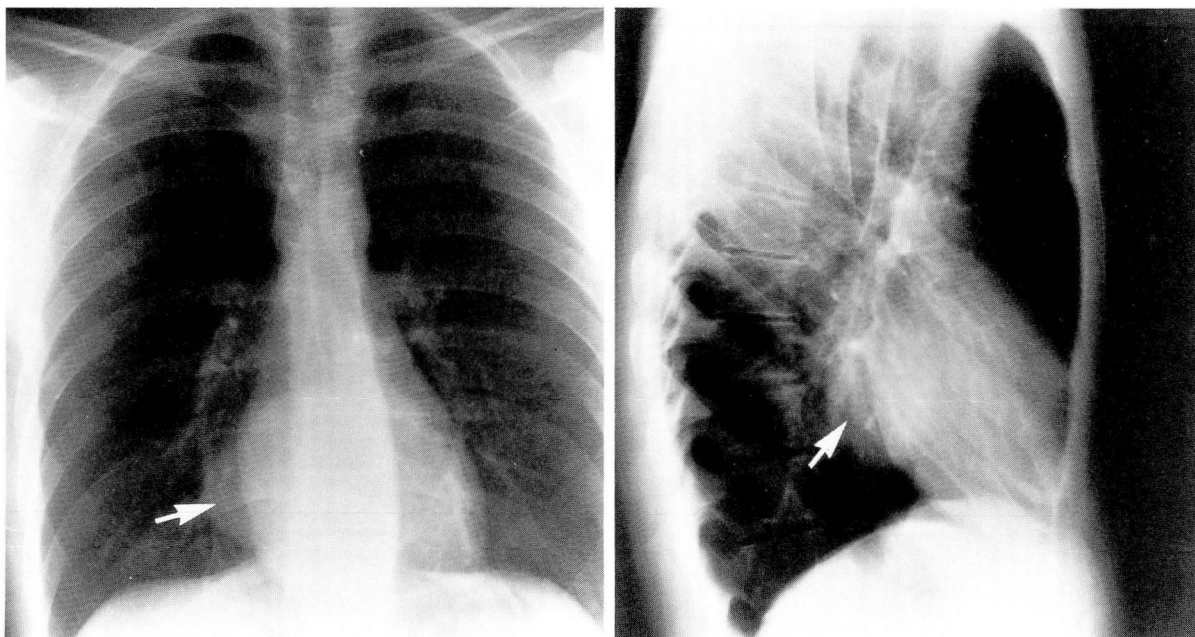


Fig. 4. A and B. Mediastinal (bronchogenic) cyst in the right infrahilar area (*arrows*) in an asymptomatic patient.

of all bronchogenic cysts.^{17,18} They are usually single but can be multiloculated. When multiple, they are usually unilateral.¹⁹ They are mainly situated in the carinal area, although they can be found in the paratracheal, hilar, paraesophageal, or suprahilar areas.²⁰ Mediastinal cysts uncommonly become infected and form fistulas with adjacent bronchi.²¹ The majority of symptoms related to mediastinal cysts are due to mass effect, especially in infants, and even deaths have been reported from airway obstruction leading to respiratory insufficiency.²² Partial pericardial defects are commonly associated with this type of cyst²³ (*Fig. 4*).

On histologic examination, the mediastinal cyst wall contains larger numbers of mucous glands and cartilaginous tissue than parenchymal cysts and also possesses smooth muscle fibers.

Parenchymal cysts: Parenchymal cysts can be multiple and even bilateral. They involve both lungs with equal frequency. Two thirds of parenchymal cysts are situated in the lower lobes. The rate of infection and fistula formation with adjacent bronchi is more than 75%. Communication with adjacent bronchi can be present without infection or fistula formation. Symptoms of cough, purulent sputum production, and hemoptysis may develop, but only when the cyst becomes infected.⁷ Associated congenital anomalies are rare compared to those that occur with mediastinal cysts (*Fig. 5*).

On histologic examination, the cyst wall contains less cartilaginous tissue than mediastinal cysts and lacks smooth muscle fibers.

Both types of cysts are lined with ciliated columnar epithelium. When they become infected, these cilia are lost, and the histologic distinction between congenital and acquired cysts becomes impossible.

Radiographically, they look like well-circumscribed, solitary, round, or oval densities which may be seen growing slowly for months or years. Microscopic¹⁷ and radiographic evidence²⁴ of cyst wall calcification has been reported. Recognition of the mediastinal cyst can be difficult on plain radiographs, especially in infants, but CT scanning or barium studies²² may be helpful in detecting the lesion.

Cases of air embolism from bronchogenic cysts in tunnel workers following decompression have been reported.²⁵ Squamous cell carcinoma²⁶⁻³⁰ and adenocarcinoma²⁶ of the cyst wall have also been reported.

Treatment is surgical resection. Infection, if present, should be treated before surgery.

Congenital cystic bronchiectasis: Most cases of bronchiectasis are acquired from bacterial or viral infections, but a congenital form of bronchiectasis does exist.

Congenital cystic bronchiectasis can occur in familial form,³¹ and often siblings have involvement of the same lobe.³² It has been found in

patients without a history of previous pneumonia and often occurs in association with congenital malformations including cleft palate, kyphoscoliosis, abnormal pulmonary artery, or Klippel-Feil syndrome.³³ In addition, it may also occur in the form of distinct syndromes such as Williams-Campbell anomaly, in which the bronchial wall cartilage is defective or totally absent, which may contribute to formation of bronchiectasis.³⁴ All occurrences support the hypothesis of the congenital origin of bronchiectasis. Bronchiectasis in the immotile cilia syndrome probably has a combined congenital and acquired etiology.

Primary lymphedema, which can also occur in the congenital form, has been associated with bronchiectasis. The pathogenesis of this association is not known but could be related to the immunologic abnormalities seen in these patients.³⁵

In congenital bronchiectasis, all the bronchi of the affected lobe or lobes are involved, and it is usually bilateral.

Microscopically, peribronchial inflammation and scarring, as seen in the acquired form, are rare. The cartilage is poorly developed and muscular hypertrophy is present. Small airways often fail to develop.

The symptoms are the same as in the acquired form, if infection is present; otherwise, the patients are asymptomatic. Symptomatic children may have growth retardation and chest wall deformities such as pigeon chest or barrel chest. Clubbing, chronic anemia, and brain abscesses may develop.

The chest radiograph may show cystic changes in the parenchyma. Bronchograms will be diagnostic. In Williams-Campbell syndrome, ballooning and collapsing of the third and fourth generation bronchi may be seen during inspiration and expiration on bronchography³⁴ (Fig. 6).

Depending upon the chronicity and complexity of the illness, the obstructive, mixed, or restrictive patterns can be identified on pulmonary function testing. Large residual volume is present, and midexpiratory flow rates are decreased because of small airways involvement.

The treatment is the same as for the acquired form.

Congenital cystic adenomatoid malformation: This anomaly consists of an intralobar mass of disorganized pulmonary tissue that lacks a well-defined bronchial system. It communicates with the bronchial tree and is supplied by the pulmonary circulation. It is found chiefly in infants and

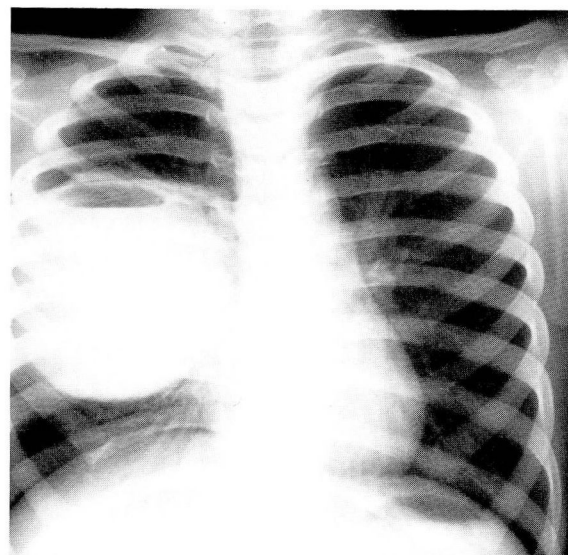


Fig. 5. Infected parenchymal (bronchogenic) cyst in a 13-year-old boy who presented with a history of recurrent pneumonia.

can involve any lobe of the lung, but rarely involves more than one lobe.³⁶ The lesion is usually solid at birth but eventually becomes cystic.³⁷

Size varies on the plain chest film, with a radiographic pattern suggesting numerous air-containing cysts arranged in bizarre fashion.

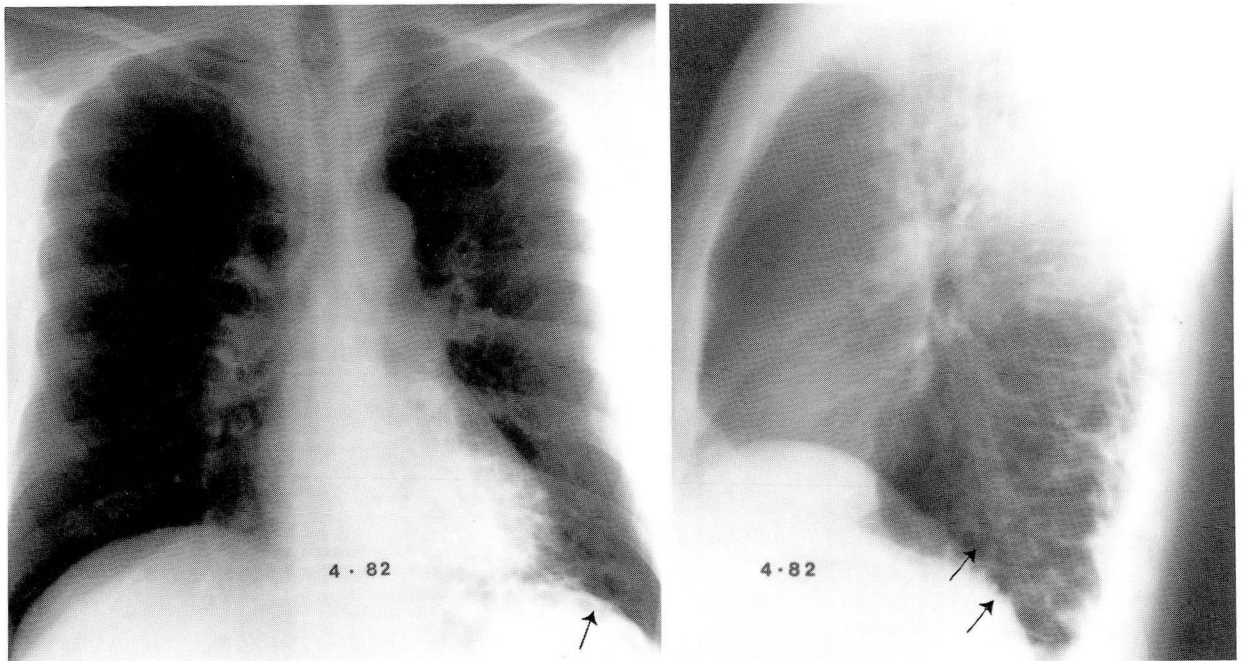
Histologically, the mass is an overgrowth of bronchioles with polypoid changes in the mucosa, lined by tall columnar mucoid cells.

Symptoms depend on the size of the lesion, and treatment is surgical extirpation.

Lobar emphysema of the newborn: This condition is characterized by severe hyperinflation of one or more lobes, with varying degrees of respiratory distress. The term "emphysema" is actually a misnomer, since on histologic study there is no destruction of the alveolar septa or alveolar walls, and the number of alveoli is normal or even increased.³⁸ This condition has been grouped under anomalies of the bronchi as the hyperinflation of the affected lobe or lobes is due to some form of bronchial obstruction including deficiency in bronchial wall cartilage,³⁹ congenital stenosis, mucous plug, or extraluminal compression from a patent ductus arteriosus or anomalous pulmonary artery or vein.⁴⁰

Males are more frequently affected than females by a ratio of 3:1.⁴¹ The upper lobes are more frequently affected than the lower lobes. The left upper lobe is more frequently involved than the right.^{42,43} The incidence of associated

6 A, B



6, C

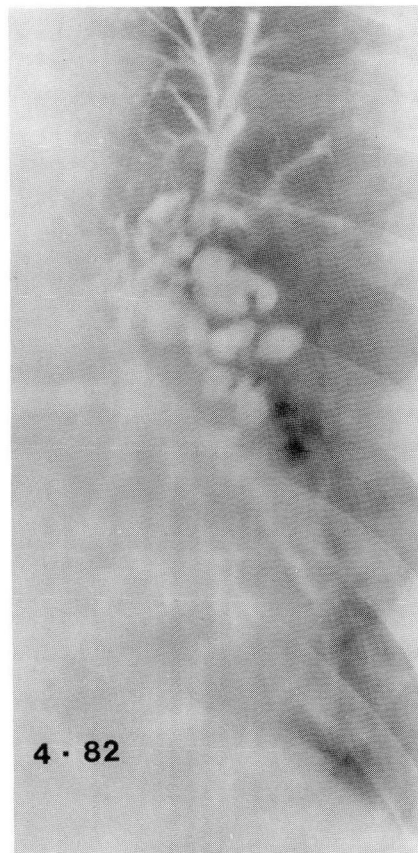
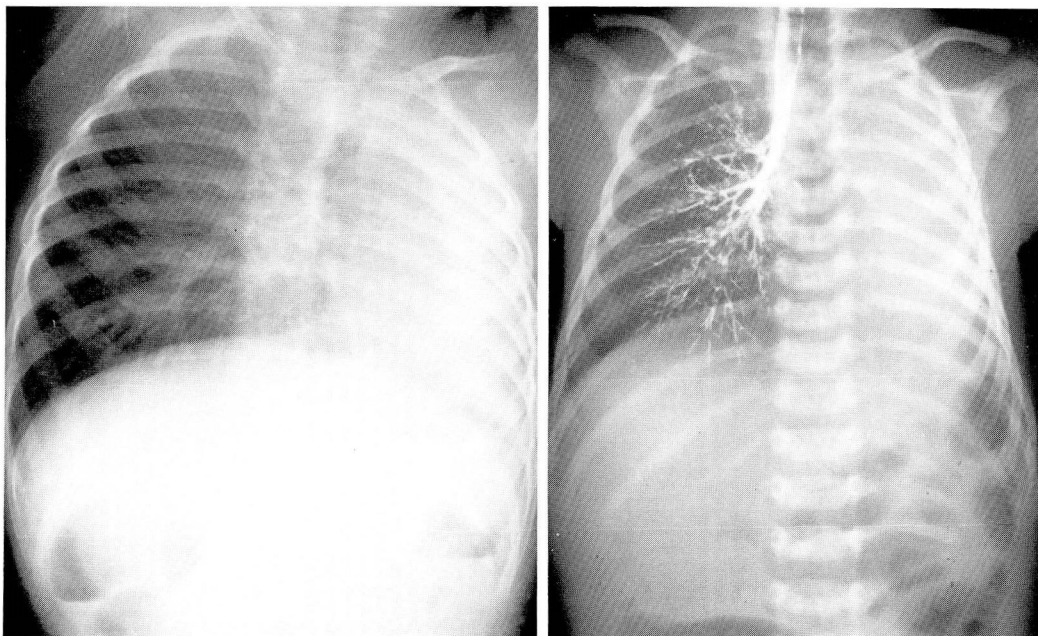


Fig. 6. A and B. Congenital bronchiectasis manifested by diffuse cystic changes involving the entire left lower lobe. **C.** Saccular changes of the left lower bronchus are demonstrated on selective bronchography.



7 A, B

Fig. 7. A. Agenesis of the left lung. Note mediastinal shift towards left and herniation and hyperinflation of right lung.

B. Agenesis of left lung with complete absence of left bronchial tree and no evidence of pulmonary parenchyma on left.

cardiac anomalies is reported to be as high as 50%.⁴⁴ Thirty percent of patients with lobar emphysema are symptomatic at birth, whereas the rest become symptomatic in later years.⁴⁵

The presence of symptoms and physical findings and the radiographic appearance depend on the degree of hyperinflation. The presence of vascular markings on the chest film may help to differentiate this condition from pneumatocele, cyst, or pneumothorax. However, fluoroscopy is often needed to support the diagnosis. If bronchial or lymphatic drainage is impaired, the involved lobe may become opaque.^{46, 47} With severe air-trapping, a mediastinal swing can be seen during inspiration and expiration.

Treatment is conservative unless there is severe respiratory distress. Spontaneous regression of the condition may occur.⁴⁸

Congenital bronchial atresia: As the name suggests, absence of the bronchial lumen leads to nondevelopment of the particular lobe of the lung. The anomaly represents atresia or stenosis of the lobar, segmental, or subsegmental bronchus near its origin. The apical posterior segment of the left upper lobe is the most commonly affected, whereas the left lower lobe is rarely involved. This condition is very rare, and fewer than 40 cases have been reported. The chest

radiograph may show an elliptical mass in the area of the anomaly which may mimic a vascular anomaly. Bronchograms and/or bronchoscopy are diagnostic, whereas pulmonary angiography may or may not be helpful.

It rarely causes any symptoms, and no treatment is required.

Anomalies of the parenchyma

Parenchymal anomalies can be further classified as follows:

- (1) Agenesis
 - (a) True agenesis
 - (b) Hypoplasia
 - (c) Aplasia
- (2) Accessory lung or bronchopulmonary sequestration
 - (a) Extralobar sequestration
 - (b) Intralobar sequestration

Failure in the development of the lung can be total or partial. It occurs in three distinct forms.

Agenesis: True agenesis means the complete absence of a lobe, or lobes, in one or both lungs, without trace of bronchial communication, vascular supply, or parenchymal tissue (Fig. 7). Aplasia means a bronchus ending in a blind pouch, with absence of pulmonary parenchyma and vas-

cular supply. Hypoplasia means a normal bronchus and an underdeveloped parenchyma with pulmonary vessels reduced in size and number.

These conditions are rare and may be found in one of 10,000 chest radiographs. The left lung is more commonly affected than the right,⁶ but when the right lung is involved, associated cardiac anomalies are common, leading to high mortality during the first year of life.⁴⁹ Sixty percent of all patients have associated anomalies, such as patent ductus arteriosus, tetralogy of Fallot, anomalies of the bone, bronchogenic cysts, or diaphragmatic hernias.⁵⁰⁻⁵² Vitamin A deficiency in pregnant rats was found to be associated with agenesis of the lung,⁵³ but this seems to be unlikely in man.⁵⁴

The chest radiograph may show mini-hemithorax⁵⁵ with complete absence of lung, crowding of the ribs, elevation of the diaphragm, and shift of the mediastinum to the affected side, with hyperinflation of the contralateral lung, depending on the severity of the abnormality. Bronchography and angiography may be required to make a definite diagnosis. Ventilation perfusion scanning is also helpful in differentiating hypoplasia from conditions giving rise to hyperlucent lung syndrome.⁵⁶

Depending upon the degree of lung involvement, the patient may die at birth or remain asymptomatic unless complications develop. Hypoplastic lung has been discussed in detail under Anomalies of the Pulmonary Vessels.

Accessory lung or bronchopulmonary sequestration: Accessory lung is aberrant lung that arises from the trachea or mainstem bronchus, receives its blood supply from the pulmonary circulation, and has a separate pleural cavity.⁵⁷ The incidence of accessory lung is extremely rare compared with bronchopulmonary sequestration. Bronchopulmonary sequestration is a congenital anomaly in which a portion of the pulmonary tissue is detached from the normal lung and receives its blood supply from systemic circulation. It has been found in 1% to 2% of all pulmonary resections.⁵⁸ Bronchopulmonary sequestration is of two types, extralobar and intralobar.

Intralobar bronchopulmonary sequestration: This variety of sequestration lies contiguous to normal lung, sharing the same pleural cavity. Sixty percent of these are found on the left side.⁶ The upper lobes are rarely involved.⁵⁹ This form of sequestration receives its blood supply from the thoracic or abdominal aorta and is significantly larger than the extralobar variety. It is usually

drained via a pulmonary vein, producing a left-to-left shunt. Associated congenital anomalies are rare with this form of sequestration.⁶

Extralobar bronchopulmonary sequestration: This form of sequestration lies in close proximity to normal lung but within its own pleural cavity. Ninety percent of these are found on the left side.⁶ It may be found below, within, or above the diaphragm, or even in the mediastinum.⁶⁰ This form of sequestration's blood supply is smaller than that of intrapulmonary sequestration and comes from the abdominal aorta. Venous drainage is through the systemic venous system, usually via the hemiazygos vein, producing a left-to-right shunt.⁶ Associated congenital anomalies such as diaphragmatic paralysis or achalasia cardia are frequent.⁶¹⁻⁶³ Diaphragmatic hernia has been found in 30% of all cases.⁶⁴ Extralobar bronchopulmonary sequestration is a common finding at neonatal autopsy.⁶

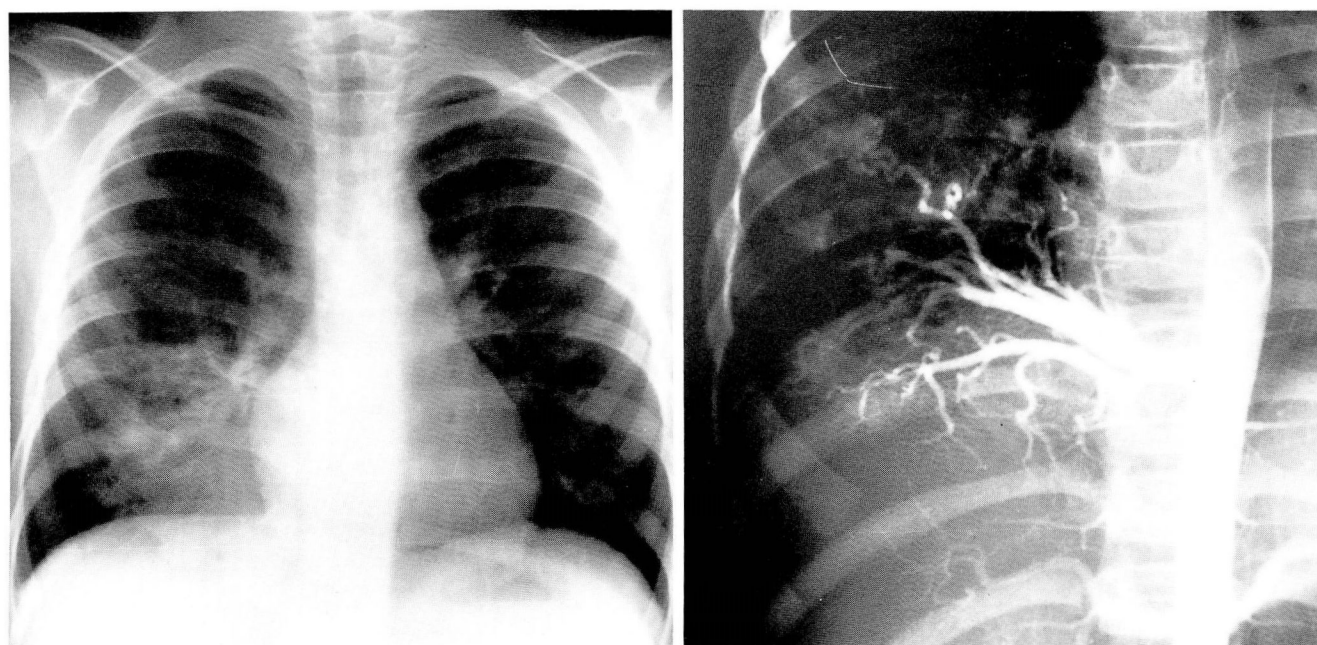
Cases of combined extralobar and intralobar sequestration in the same individual have been reported.⁶⁵ Bronchopulmonary sequestration can also involve the entire lung.^{66,67}

Several opinions have been offered regarding the development of these anomalies, but probably each of these sequestrations has a different embryogenesis. Most likely, one developed from the original lung bud and the other from an accessory one.^{67,68}

If associated congenital anomalies are dormant, both conditions go unrecognized until complications develop such as pyogenic, tuberculous,⁶⁹ or fungus infections, fistula formation, pneumothorax,⁶³ or massive hemoptysis.⁶⁵ Fistula formation or communication with the normal lung usually develops after infection.

Radiographically, sequestration appears as a homogeneous, well-circumscribed, round, oval, or triangular mass of fluid density in the paravertebral area contiguous to the diaphragm. An air/fluid level may be seen with or without infection. This may be due to communication with the gastrointestinal tract and can be detected by an upper gastrointestinal series.⁷⁰ The lesion is usually cystic, but with infection, the cystic nature of the lesion is lost. At times, anomalous vessels entering or leaving the mass may be detected on plain films or tomograms, but angiograms are required to make the diagnosis (*Fig. 8*).

Microscopically, this anomaly is a cystic lesion lined by flat or tall columnar epithelium. The tissue between the cysts is poorly developed and does not contain cartilage.



8 A, B

Fig. 8. A. Bronchopulmonary sequestration: note dense infiltrate in the posterior basal segment of the right lower lobe in an adolescent presenting with recurrent pneumonia.

B. Aortogram identifying the systemic blood supply to the sequestered lobe.

Excision is not always necessary in uncomplicated cases.

Anomalies of the pulmonary vessels

Most multiple congenital anomalies involving the pulmonary vasculature are related primarily to anomalies of the heart. Those independent of cardiac involvement are discussed here.

Arteriovenous fistula: Arteriovenous (AV) fistula is a rare but potentially dangerous congenital malformation consisting of an abnormal communication between the pulmonary artery and vein bypassing the capillary bed. According to its etiology, AV fistulas can be classified as follows:

- (1) Congenital
 - (a) Associated with Osler-Rendu-Weber (ORW) disease
 - (b) Idiopathic
- (2) Acquired
 - (a) Trauma
 - (b) Schistosomiasis
 - (c) Cirrhosis of the liver
 - (d) Carcinoma of the lung

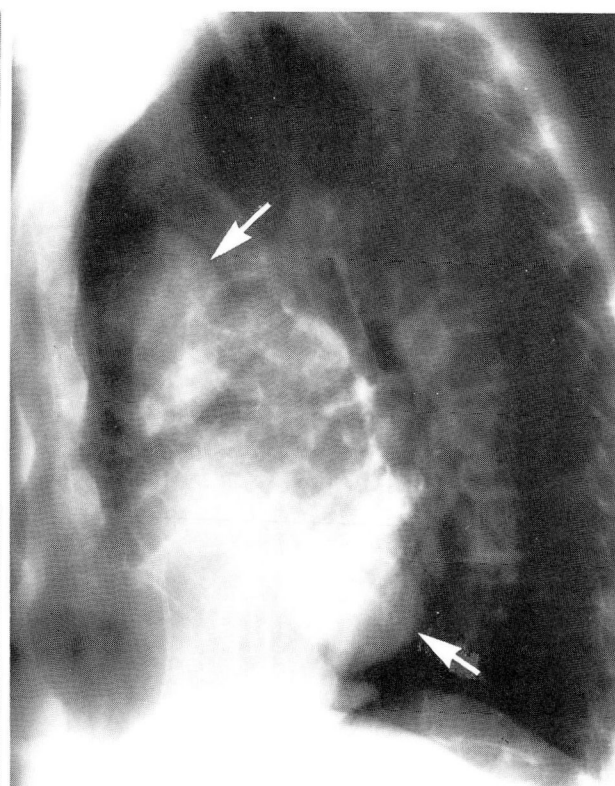
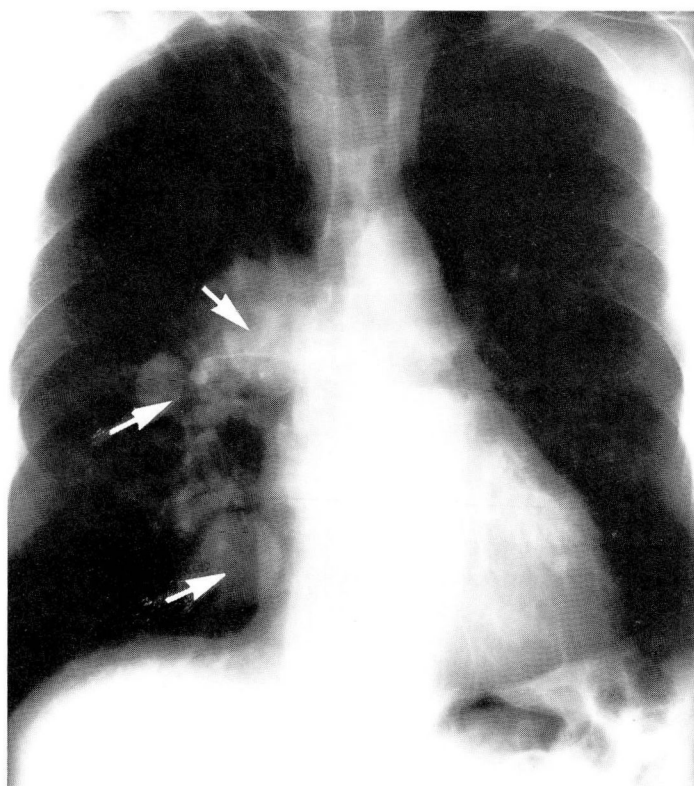
The pulmonary vascular communication can develop with the systemic circulation on either the arterial or venous side and from several acquired conditions. Only the congenital form of AV fistula is discussed here.

Congenital AV fistula has been found mainly

in patients with ORW disease. Sixty percent of the patients with AV fistula have this autosomal dominant, non-sex-linked condition.⁷¹ Fifteen percent of all patients with ORW disease have AV fistulas of the lung, as do 6% of relatives of patients with ORW disease.⁷² Sixty-five percent of the patients are females. Thirty-three percent of patients have multiple lesions. Eighty percent of the lesions are either single or unilateral, and 70% involve the lower lobes.⁷¹

Physiologically, an AV fistula is a right-to-left shunt which results in reduced oxygen saturation. Smaller shunts of less than 15% will not produce symptoms, but if the shunt is more than 25%, it will lead to increased cardiac output because of significant hypoxia.⁷² It can also produce erythrocytosis unless chronic bleeding is present. Symptoms are usually manifested during the third decade of life. About 50% of patients are asymptomatic and detected mainly from an abnormal chest film. In symptomatic patients, hemoptysis and dyspnea on exertion are the most common symptoms.⁷¹ Other symptoms may include headache, dizziness, vertigo, and diplopia. Symptomatic patients uncommonly may show the classical triad of clubbing, cyanosis, and polycythemia. On auscultation, a continuous bruit may be heard over the involved area, which may increase in intensity by inspiration, by standing up, or with

9 A, B



9 C

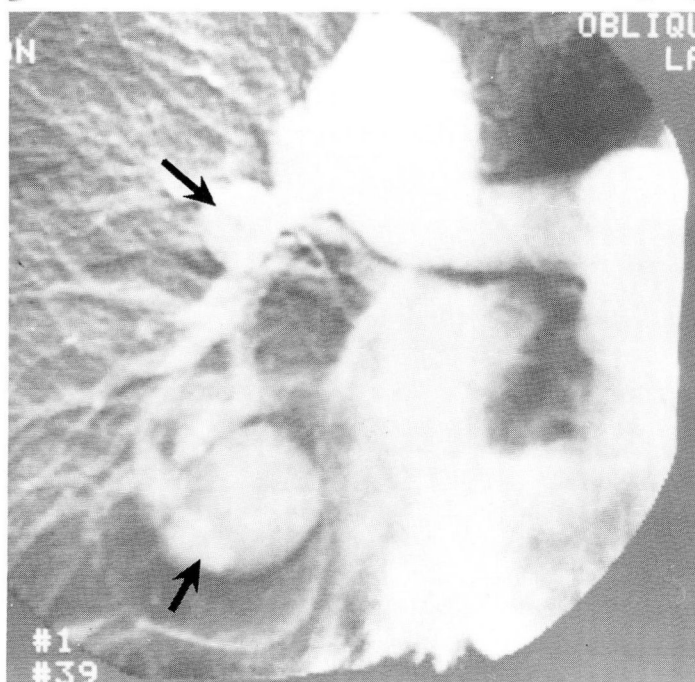
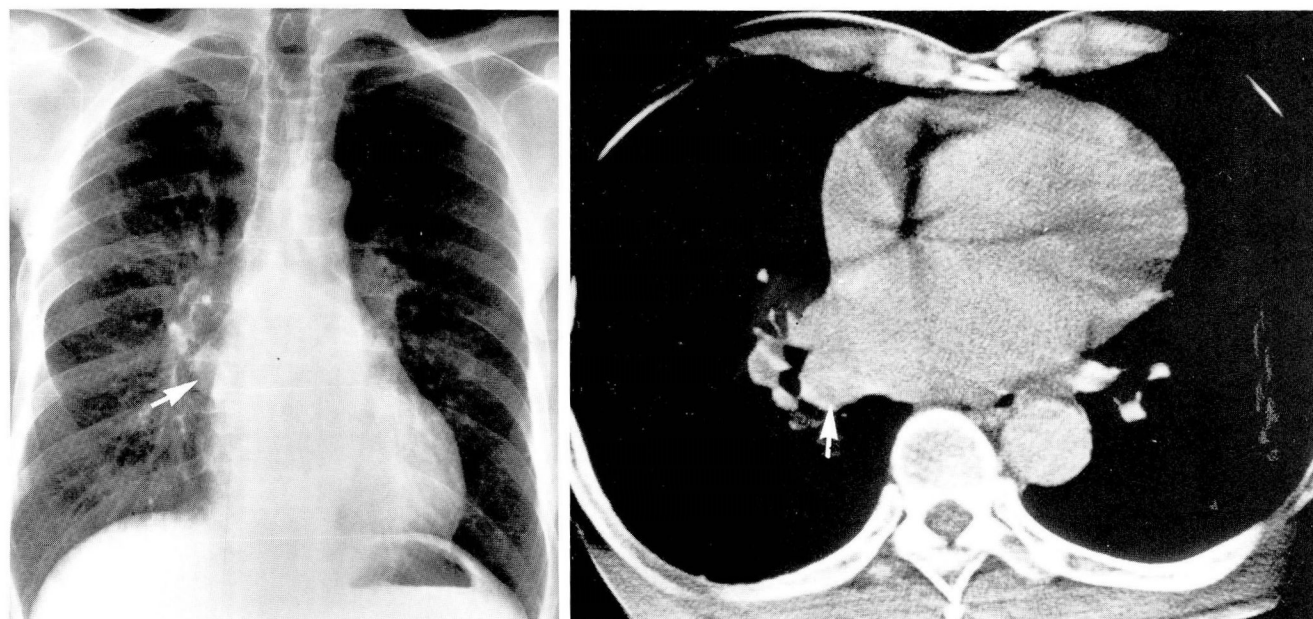


Fig. 9. A and B. Pulmonary AV fistulas in a patient with ORW syndrome. Note multiple, large, well-circumscribed nodular densities.

C. Digital subtraction angiogram. Nodules opacify following injection of contrast material through a peripheral vein.

Müller's maneuver, and becomes faint with the Valsalva maneuver. Radiographically, it may appear as a solitary, circumscribed lesion in the peripheral lung field. Calcification is seldom detected. Occasionally, a feeding or draining vessel

may be seen on the chest film or on tomography. Fluoroscopy may show a pulsating mass. Angiograms are not always necessary to make the diagnosis but are mandatory to find other lesions, if excision is being contemplated. Along with



10 A, B

Fig. 10. A. Pulmonary varix. Note the smooth nodular density in the right infrahilar area (*arrow*). [Figure 10. A and B from *Borkowski GP, O'Donovan PB, Troup BR: Pulmonary varix: CT findings. J Comput Assist Tomogr 1981; 5:827-829. By permission of the authors and publisher.*]

B. CT scan of the chest at the level of mid-right hilus establishing the diagnosis of pulmonary varix. Note dilated right pulmonary vein entering the left atrium (*arrow*).

angiograms, cardiac catheterization is recommended to determine the differential pulmonary venous oxygen content and to rule out cyanotic heart diseases. Digital subtraction angiography may be equally helpful in making the diagnosis (Fig. 9). Contrast echocardiography with indocyanine green is particularly valuable in the diagnosis of small asymptomatic AV fistulas and is used to determine residual shunt in patients who have undergone surgery.⁷³

Fifty percent of the lesions will remain stable in size, whereas the rest will gradually increase. Significant hemoptysis will develop in 10% of the patients. In about 6% of patients, septic emboli will develop as the filtering mechanism of the lung is being bypassed.⁷¹ Fishman⁷⁴ reported a case in which the size of the fistula increased with pregnancy and shrank to its original size at termination of pregnancy at the seventh month. A case of intrapleural rupture of an AV fistula leading to death has been reported.⁷⁵ Complications of AV fistula are significantly higher in patients with ORW disease than in patients with the idiopathic variety.

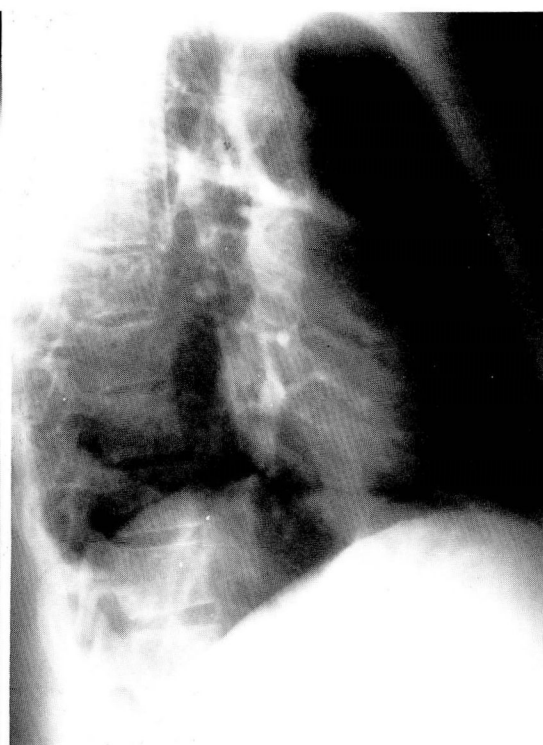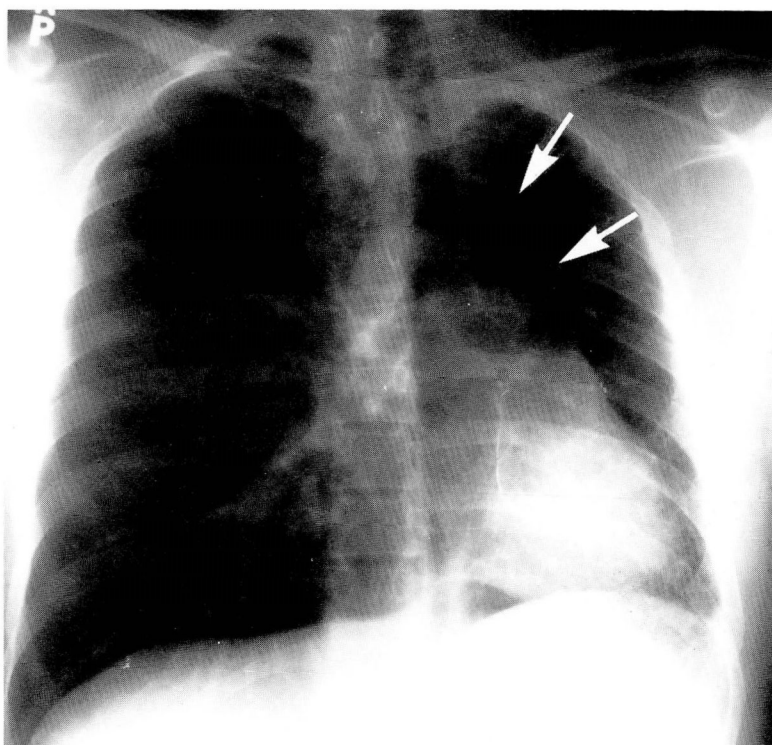
Treatment is conservative resection, or embolization,⁷⁶ if possible. Surgery is not indicated if there is a small, single, asymptomatic lesion without ORW disease. It should be performed if the

lesion is increasing in size or producing symptoms. In the patient with multiple lesions, removal of all fistulas may be impossible, but selective resection may reduce the degree of shunt. A fistula with connection to the systemic circulation should be resected.⁷¹

Varicosities of the pulmonary veins: This rare anomaly is characterized by abnormal dilatation and tortuosity of the pulmonary veins before entering the heart. The majority of patients are asymptomatic, but massive hemoptysis has been reported.⁷⁷ An acquired form of pulmonary varix is known to occur with mitral stenosis. The right side is more frequently involved than the left, and the upper lobes more frequently than the lower. The sexes are equally affected. Associated pulmonary venous hypertension and congenital anomalies such as patent ductus arteriosus, ventricular septal defect, coarctation of the aorta, and diaphragmatic eventrations have been reported.⁷⁸⁻⁸¹

Radiographically, the anomaly appears as multiple, small, round, or oval homogeneous masses or as a single moderate-sized lobulated mass with well-defined borders in the perihilar areas. Fluoroscopy may confirm the pulsatile nature of the lesion: reduction in size with the Valsalva maneuver and increase in size with Müller's ma-

11 A,B



11 C

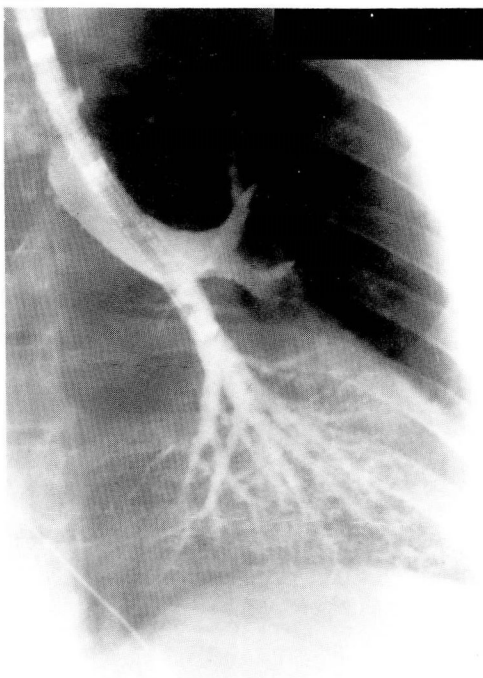


Fig. 11. A and B. Hypoplastic left lung. Note marked shift to the left of the mediastinum. The left pulmonary artery and its branches are not visualized. Compensatory emphysema is noted on the right. Anterior junctional line (*arrows*) extends into the mid-left thorax.

C. Bronchograms of left hypoplastic lung. Left mainstem bronchus and branches are patent and essentially of normal configuration.

neuver can be observed. Angiography is necessary to differentiate it from an AV fistula. The varix will opacify slowly and only during the venous phase. CT scanning is also helpful in making the diagnosis⁸² (Fig. 10).

Surgery is indicated only for symptomatic or progressing lesions.

Absence of unilateral pulmonary artery or hypoplastic lung: This rare anomaly is characterized by unilateral absence of connection between the main pulmonary artery and the parenchymal pulmonary vessels. Nondevelopment or underdevelopment of the sixth arch during the embryonic stage leads to this anomaly.

The involved lung is usually supplied by the bronchial arteries. The involved pulmonary artery is usually on the side opposite to the aortic arch. When the left side is involved, associated cardiac anomalies such as tetralogy of Fallot are common. Twenty percent of patients with right-sided involvement have pulmonary hypertension.⁸³

Radiographically, the involved hilus and lung are smaller, and the lung is hyperlucent. A reticular pattern from collateral circulation can sometimes be seen. Its differentiation from the Swyer-James anomaly requires pulmonary angiography or ventilation-perfusion lung scanning.⁵⁶ Along with pulmonary angiography, thoracic aortography is necessary to document collateral circulation.

Patients are usually asymptomatic, but hemoptysis may develop from collateral circulation. Treatment is conservative. We have encountered a case in a 25-year-old white man who had hypoplastic lung and presented with pulmonary hemorrhage from hypertrophied bronchial arteries. Pneumonectomy was required (Figs. 11–13).

Surgical anastomosis with the pulmonary arterial tree has been tried only in a very few cases.⁸⁴

Anomalous origin of the pulmonary artery: Of the several different forms of anomalous origin of the pulmonary arteries, such as from the ascending aorta, subclavian artery, innominate artery, and patent ductus arteriosus, the origin of the left pulmonary artery from the right pulmonary artery has special significance. This occurs as a consequence of failure of connection between the left pulmonary arterial plexus and the left sixth arch.⁸³

Because of its peculiar course between the trachea and the esophagus, it produces varying degrees of obstruction of the trachea or right bronchus or esophagus, and results in related symptoms. Ring cartilages with absence of pars membranacea may be present along with this anomaly, contributing further to tracheal obstruction.⁸⁵

Barium studies support and pulmonary angiography confirms the diagnosis. Treatment is surgical. Bronchoscopy should be done before surgery to rule out ring cartilage deficiencies.

Anomalous systemic supply of the lung: Arteries from the systemic circulation may supply normal or dysplastic tissue of the lung in an abnormal fashion. They may arise from the ascending, descending, or abdominal aorta, or from the subclavian, intercostal, or internal mammary arter-

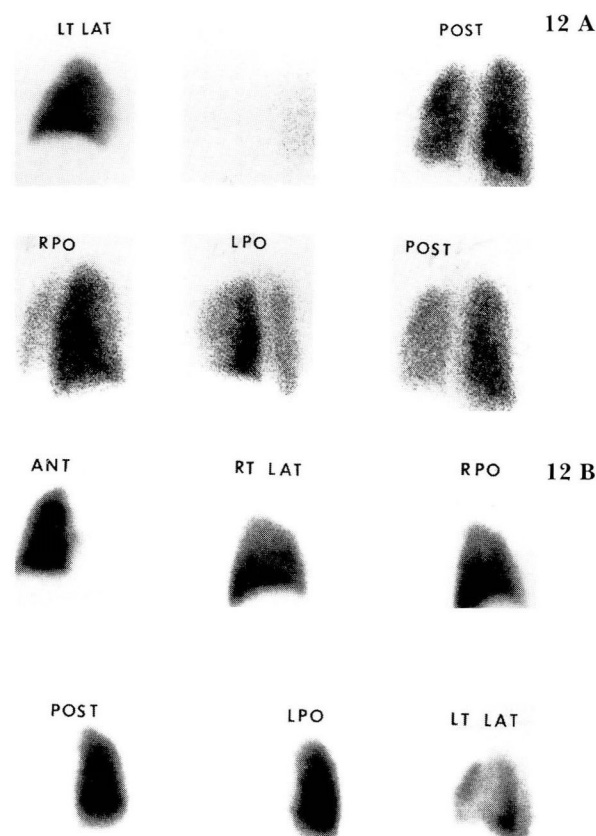


Fig. 12. A. Hypoplastic left lung. Ventilation lung scan. Xenon activity, present bilaterally, is decreased on the left. (LT LAT = Left lateral, POST = posterior, RPO = right posterior oblique, LPO = left posterior oblique).

B. Hypoplastic left lung. Perfusion lung scan demonstrates total absence of perfusion on the left. Normal uptake and distribution are seen on the right. (ANT = anterior, RT LAT = right lateral, RPO = right posterior oblique, POST = posterior, LPO = left posterior oblique, LT LAT = left lateral).

ies, or from the celiac plexus.⁸³ These arteries may communicate with the pulmonary arteries or veins. If the bronchial arteries are also enlarged for any reason, their differentiation from anomalous arteries becomes difficult. The acquired form of anomalous supply may develop in postinfectious or postinflammatory conditions of the lungs.

Patients are usually asymptomatic but may suffer from recurrent hemoptysis. A systolic bruit may be heard over the involved area. The chest radiograph may be normal, but increased irregular vascular markings and rib notching may be seen. The pulmonary angiogram is normal whereas the aortogram is diagnostic.

13 A, B

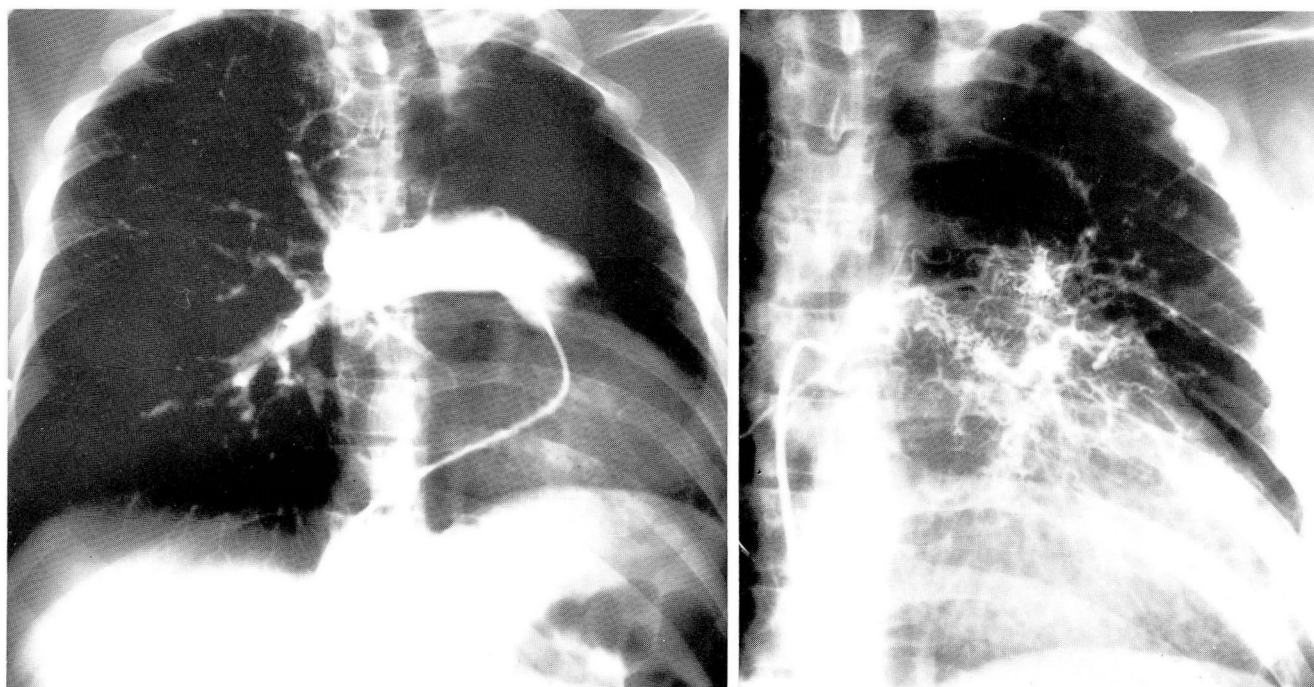


Fig. 13. A. Hypoplastic left lung. Pulmonary angiogram demonstrates opacification of the pulmonary arterial system and complete absence of filling of left pulmonary artery.

B. Hypoplastic left lung. Thoracic aortogram reveals hypertrophy of the bronchial arteries.

Multiple pulmonary artery coarctations: Congenital multiple coarctations of the pulmonary arteries are rarely associated with pulmonary hypertension. Patients may have a systolic murmur over the involved areas. Coarctations are due to intimal fibrosis and medial hypertrophy.⁸³

Pulmonary vascular anomalies such as anomalous venous return, pulmonary artery stenosis, pulmonary artery aneurysm, hypogenetic lung syndrome, and others are invariably associated with major cardiac anomalies, and the latter is directly or indirectly responsible for the resulting consequences.

References

- Scammon RE. The developmental anatomy of the chest and thoracic organs. [In] Myers JA, McKinley CA, eds. *The Chest and Heart*, Vol 1, Springfield, Illinois, Charles C Thomas, 1948.
- Potter EL. Pulmonary pathology in newborn. *Adv Pediatr* 1953; **6**:157.
- Boyden EA. Cleft left upper lobes and split anterior bronchus. *Surgery* 1949; **26**:167-180.
- Von Hayek, H. *The Human Lung*. New York, Hafner Publishing Co, 1960.
- Schaffner A. *Textbook of X-ray Diagnosis*. Vol II, 2nd ed., Philadelphia, WB Saunders Co, 1950-52, p 241.
- Wier JA. Congenital anomalies of the lung. *Ann Intern Med* 1960; **52**:330-348.
- Kent EM, Blades B. The anatomic approach to pulmonary resection. *Ann Surg* 1942; **116**:782-794.
- Felson B. The lobes and interlobar pleura: fundamental roentgen considerations. *Am J Med Sci* 1955; **230**:572-584.
- Boyden EA. Developmental anomalies of the lung. *Am J Surg* 1955; **89**:79-89.
- Brock RC. *Anatomy of the Bronchial Tree*. London, Oxford Univ Press, 1947. (Cited by Wier JA.)
- Kirwan WO, Walbaum PR, McCormack RJM. Cystic intrathoracic derivatives of the foregut and their complications. *Thorax* 1973; **28**:424-428.
- Jones PH. Developmental defect in the lung. *Thorax* 1955; **10**:205-213.
- Boyden EA. Bronchogenic cysts and theory of intralobar sequestration: new embryologic data. *J Thorac Surg* 1958; **35**:604-616.
- Racz I, Baum GL. The relationship of ethnic origin to prevalence of cystic lung disease in Israel: a preliminary report. *Am Rev Resp Dis* 1965; **91**:552-555.
- Baum GL, Racz I, Bubis JJ, Molho M, Shapiro BL. Cystic disease of the lung: report of eighty-eight cases, with an ethnologic relationship. *Am J Med* 1966; **40**:578-602.
- Buddington WT. Intradiaphragmatic cyst, ninth reported case. *N Engl J Med* 1957; **257**:613-615.
- Rogers LF, Osmer JC. Bronchogenic cyst: a review of 46 cases. *AJR* 1964; **91**:273-283.
- Reed JC, Sobonya RE. Morphologic analysis of foregut cyst in the thorax. *AJR* 1974; **120**:851-860.
- Spencer H. *Pathology of the Lung*. Oxford Program, 2d ed. 1968.
- Maier HC. Bronchogenic cyst of the mediastinum. *Ann Surg* 1948; **127**:476-502.
- Schmidt FE, Drapanas T. Congenital cystic lesions of the bronchi and lungs. *Ann Thorac Surg* 1972; **14**:650-657.
- Eraklis AJ, Griscom NT, McGovern JB. Bronchogenic cysts of the mediastinum in infancy. *N Engl J Med* 1969; **281**:1150-1155.

23. Kwak DL, Stork WJ, Greenberg SD. Partial defect of the pericardium associated with a bronchogenic cyst. *Radiology* 1971; **101**:287-288.
24. Fraser RG, Paré JAP. *Diagnosis of Disease of the Chest*. Philadelphia, W.B. Saunders, 2d ed, Vol 1, 1979, p. 618.
25. Golding FC, Griffiths P, Hempleman HV, Paton WDM, Walder DN. Decompression sickness during construction of Dartford Tunnel. *Br J Industr Med* 1960; **17**:167-180.
26. Moersch HJ, Clagett OT. Pulmonary cysts. *J Thorac Surg* 1947; **16**:179-194.
27. Baxter SG, Meakins JF. Developmental bronchogenic cysts. *Ann Intern Med* 1953; **38**:967-980.
28. Larkin JC Jr, Phillips S. Carcinoma complicating cyst of the lung. *Dis Chest* 1955; **27**:453-457.
29. Peabody JW Jr, Katz S, Davis EW. Bronchial carcinoma arising in a lung cyst. *AJR* 1957; **77**:1048-1050.
30. West JP, Van Schoonhoven PV. Carcinoma of the lung developing in congenital cyst. *Surgery* 1957; **42**:1071-1076.
31. Williams H, O'Reilly RN. Bronchiectasis in children: its multiple, clinical and pathological aspects. *Arch Dis Child* 1959; **34**:192-201.
32. Danielson GK, Hanson CW, Cooper EC. Middle lobe bronchiectasis: report of an unusual familial occurrence. *JAMA* 1967; **201**:605-608.
33. Field CE. Bronchiectasis in childhood. I. Clinical survey of 160 cases. *Pediatrics* 1949; **4**:21-46.
34. Williams H, Campbell P. Generalized bronchiectasis associated with deficiency of cartilage in the bronchial tree. *Arch Dis Child* 1960; **35**:182-191.
35. Beer DJ, Pereira W Jr, Snider GL. Pleural effusion associated with primary lymphedema. A perspective on the yellow nail syndrome. *Am Rev Resp Dis* 1978; **117**:595-599.
36. Neitzschman HR, Nice CM Jr, Harbison JB. Cystic adenomatoid malformation of the lung: case report. *Radiology* 1972; **102**:407.
37. Moncrieff MW, Cameron AH, Astley R, Roberts KD, Abrams LD, Mann JR. Congenital cystic adenomatoid malformation of the lung. *Thorax* 1969; **24**:476-487.
38. Hislop A, Reid L. New pathological findings in emphysema of childhood. I. Polyalveolar lobe with emphysema. *Thorax* 1970; **25**:682-690.
39. Leape LL, Longino LA. Infantile lobar emphysema. *Pediatrics* 1964; **34**:246-255.
40. Kruse RL, Lynn HB. Lobar emphysema in infants. *Mayo Clin Proc* 1969; **44**:525-534.
41. Hendren W, McKee DM. Lobar emphysema in infancy. *J Ped Surg* 1966; **1**:24-39.
42. Reid JM, Barclay RS, Stevenson JG, Welsh TM. Congenital obstructive lobar emphysema. *Dis Chest* 1966; **49**:359-361.
43. Slaple TW, Hudson HH, Hartmann AF Jr, McAlister WH. The angiographic findings in the four cases of infantile lobar emphysema. *AJR* 1966; **97**:195-202.
44. Cottom DG, Myers NA. Congenital lobar emphysema. *Br Med J* 1957; **1**:1394-1396.
45. Cremin BJ, Movsowitz H. Lobar emphysema in infants. *Br J Radiol* 1971; **44**:692-696.
46. Franken EA Jr, Buehl I. Infantile lobar emphysema: report of two cases with unusual roentgenographic manifestation. *AJR* 1966; **98**:354-357.
47. Fagan CJ, Swischuk LE. The opaque lung in lobar emphysema. *AJR* 1972; **114**:300-304.
48. Roghair GD. Nonoperative management of lobar emphysema: long term follow-up. *Radiology* 1972; **102**:125-127.
49. Booth JB, Berry CD. Unilateral pulmonary agenesis. *Arch Dis Child* 1967; **42**:361-374.
50. Brünner S, Nissen E. Agenesis of the lung. *Am Rev Resp Dis* 1963; **87**:103-106.
51. Smith RA, Bech AO. Agenesis of the lung. *Thorax* 1958; **13**:28-33.
52. Jones HE, Howells CHL. Pulmonary agenesis. *Br Med J* 1961; **2**:1187-1189.
53. Wilson JG, Warkany J. Aortic-arch and cardiac anomalies in offspring of vitamin A deficient rats. *Am J Anat* 1949; **85**:113-155.
54. Warkany J. Congenital anomalies. *Pediatrics* 1951; **7**:607-610.
55. Daves ML, Walsh JA. Minihemithorax. *AJR* 1970; **109**:528-530.
56. Grum CM, Yarnal JR, Cook SA, Cordasco EM, Tomashefski JF. Unilateral hyperlucent lung. Non-invasive diagnosis of pulmonary artery agenesis. *Angiology* 1981; **32**:194-207.
57. Hennigar GR, Choy SH. Accessory lung with persistent left superior vena cava and duplication of intestine. *J Thorac Surg* 1958; **35**:469-473.
58. Carter R. Pulmonary sequestration. *Ann Thorac Surg* 1969; **7**:68-88.
59. Marks C, Wiener SN, Reidman M. Pulmonary sequestration. *Chest* 1972; **61**:253-257.
60. Williams AO, Enumah FI. Extralobar pulmonary sequestration. *Thorax* 1968; **23**:200-203.
61. Tharion J, Das PB, Gupta RP, Jairaj PS, John S. Sequestration of the lung associated with achalasia cardia. *Chest* 1974; **65**:222-223.
62. Campbell JA. The diaphragm in roentgenology of the chest. *Rad Clin N Amer* 1963; **1**:395-410.
63. Kilman JW, Battersby JS, Taybi H, Vellios F. Pulmonary sequestration. *Arch Surg* 1965; **90**:648-657.
64. Valle AR, White ML Jr. Subdiaphragmatic aberrant pulmonary tissue: case report. *Dis Chest* 1947; **13**:63-68.
65. Iwai K, Shindo G, Hajikano H, et al. Intralobar pulmonary sequestration with special reference to developmental pathology. *Am Rev Resp Dis* 1973; **107**:911-920.
66. Blesovsky A. Pulmonary sequestration: a report of an unusual case and review of the literature. *Thorax* 1967; **22**:351-357.
67. Bates M. Total unilateral pulmonary sequestration. *Thorax* 1968; **23**:311-315.
68. Halasz NA, Lindskog GE, Liebow AA. Esophagobronchial fistula and bronchopulmonary sequestration: report of a case and review of the literature. *Ann Surg* 1962; **155**:215-220.
69. Schachter EN, Karpick RJ. Bronchopulmonary sequestration and pulmonary tuberculosis. *Chest* 1972; **62**:331-333.
70. Gerle RD, Jarltzki A III, Ashley CA, Berne AS. Congenital bronchopulmonary-foregut malformation: pulmonary sequestration communicating with the gastrointestinal tract. *N Engl J Med* 1968; **278**:1413-1419.
71. Dines DE, Arms R, Bernatz PE, Gomes MR. Pulmonary arteriovenous fistulas. *Mayo Clin Proc* 1974; **49**:460-465.
72. Hodgson CH, Burchell HB, Good AC, Clagett OT. Hereditary hemorrhagic telangiectasia and pulmonary arteriovenous fistula. *N Engl J Med* 1959; **261**:625-636.
73. Dines DE, Seward JB, Bernatz PE. Pulmonary arteriovenous fistula. *Mayo Clin Proc* 1983; **58**:176-181.
74. Fishman AP. *Pulmonary Diseases and Disorders*. New York, McGraw Hill Publication 885, 1980.
75. Dalton ML Jr, Goodwin FC, Bronwell AW, Rutledge R. Intrapleural rupture of pulmonary arteriovenous aneurysm; report of a case. *Dis Chest* 1967; **52**:97-100.
76. Taylor BG, Cockerill EM, Manfredi F, Klatte EC. Therapeutic embolization of the pulmonary artery in pulmonary arteriovenous fistula. *Am J Med* 1978; **64**:360-363.
77. Poller S, Wholey MH. Pulmonary varix: evaluation by selective pulmonary angiography. *Radiology* 1966; **86**:1078-1081.
78. Papamichael E, Ikkos D, Alkalais K, Yannacopoulos J. Pulmonary varicosity associated with other congenital abnormalities. *Chest* 1972; **62**:107-109.
79. Rizk G, Malhem R, Dagher I. Bilateral pulmonary varicosities associated with coarctation of the aorta. *Thorax* 1970; **25**:97-100.
80. Redo FS, Engle MA, Holswade GR, Goldberg HP. Operative correction of ventricular septal defect with origin of both great vessels from the right ventricle. *J Thorac Cardiovasc Surg* 1963; **45**:526-538.

81. Vengsarkar AS, Kincaid OW, Weidman WH. Selective angiography in the diagnosis of varicosity of the pulmonary veins; report of a case. *Am Heart J* 1963; **66**:396-398.
82. Borkowski GP, O'Donovan PB, Troup BR. Pulmonary varix, CT findings. *J Comput Assist Tomogr* 1981; **5**:827-829.
83. Ellis K, Seaman WB, Griffiths SP, Berdon WE, Baker DH. Some congenital anomalies of the pulmonary arteries. *Semin Roentgenol* 1967; **2**:325-341.
84. Kieffer S, Amplatz K, Anderson RC, Lillehei CW. Proximal interruption of a pulmonary artery. *AJR* 1965; **95**:592-597.
85. Landing BH. Syndromes of congenital heart disease with tracheobronchial anomalies. *AJR* 1975; **123**: 679-686.