

Esophageal perforation: a complication of the Angelchik prosthesis¹

C. Douglas Lees, M.D.
Ezra Steiger, M.D.
Delos M. Cosgrove III, M.D.

The recent introduction of the Angelchik antireflux prosthesis has led to its widespread acceptance, especially in community hospitals. Long-term follow-up is not yet available, but there are recent reports of serious complications with this device. A case of perforation of the distal esophagus by an Angelchik prosthesis is presented, and the literature is reviewed. Caution is advised in the implantation of this prosthesis.

Index terms: Esophageal perforation • Esophageal reflux • Prosthesis

Cleve Clin Q 50: 449-451, Winter 1983

Hiatal hernia and associated reflux esophagitis should initially be treated medically. Many cases, however, require surgical correction. The objective of surgical repair is to prevent reflux and esophagitis and its sequelae.¹ Allison initially proposed an anatomical repair of hiatal hernia, which has been superseded by three accepted operations: Nissen's fundoplication,² Belsey's Mark IV,³ and Hill's posterior gastropexy.⁴ These procedures involve closing the hiatal defect, keeping the lower part of the esophagus in the abdominal cavity, and reestablishing the lower esophageal sphincter. Although excellent results have been obtained by various groups for all of these operations, they have been considered by some to be technically complicated.⁵

Recently Angelchik and Cohen⁵ have developed a prosthetic device (*Fig. 1*), which can be placed around the distal esophagus below the

diaphragm. This procedure prevents reflux, does not require repair of the diaphragmatic defect, and is technically easier than the standard operations. Although it has failed to generate enthusiasm in the surgical academic sector,⁶ an estimated 9000 prostheses have been implanted in patients in more than 1500 institutions. (Communication from Vassallo TM, American Heyer-Schulte Corporation, Aug 12, 1982). Concern has been raised by Polk⁷ and others about the risks involved in using such a prosthesis for which no long-term follow-up is available. This report concerns a patient who was referred to the Cleveland Clinic for evaluation after implantation of an Angelchik prosthesis.

Case report

A 22-year-old white woman was transferred to the Cleveland Clinic on June 12, 1982, from a community hospital. In June 1979, she had undergone combined gastric stapling and Nissen repair for obesity and hiatal hernia with severe reflux esophagitis. Postoperatively, intermittent nausea and vomiting developed, and a weight loss of 22.7 kg occurred. Esophagoscopy showed no recurrence of the hiatal hernia, but there was considerable edema at the gastric staple line. Dilatation of the gastric staple line was performed twice. Impacted food in the proximal gastric pouch responded to meat tenderizer. In September 1979, a laparotomy was performed to disrupt the gastric staple line, since she was now considered psychologically unsuited to the gastric pouch. In January 1982, a recurrent hiatal hernia developed with reflux esophagitis. She underwent laparotomy, lysis of dense adhesions, and placement of an Angelchik prosthesis. During this procedure a small rent was made in the upper stomach. The rent was closed with sutures, and a gastrotomy tube was inserted (this was later removed). After making a satisfactory recovery, she complained of persistent epigastric pain, intermittent vomiting, constipation, and weight loss of

¹ Departments of Thoracic and Cardiovascular Surgery (C. D. L., D. M. C.) and General Surgery (E. S.), The Cleveland Clinic Foundation. Submitted for publication June 1983; accepted July 1983.

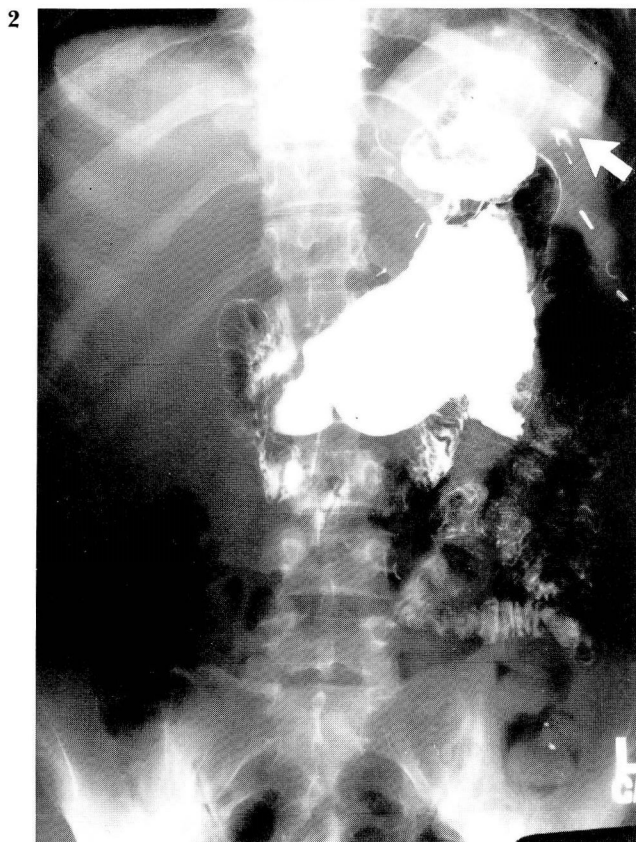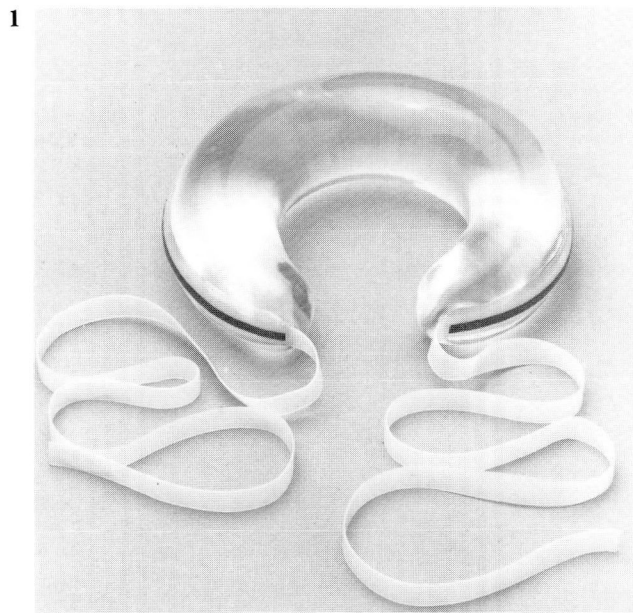


Fig. 1. Angelchik prosthesis.

Fig. 2. Upper gastrointestinal study; *arrow* indicates extravasated barium.

63 kg from her original weight of 118 kg. In June 1982, she had fever and chills for approximately 12 days and was transferred to the Cleveland Clinic for evaluation.

Physical examination revealed mild tenderness in the left lower abdomen. Esophagogastroscopy was performed on June 15, 1982, and showed a perforation of the distal esophagus with the Angelchik prosthesis clearly visible in the lumen. A barium study confirmed the esophageal perforation (*Fig. 2*). After a three-week course of total parenteral nutrition to improve her significant malnutrition, surgery was performed on July 7, 1982. Laparotomy revealed massive adhesions and a 4-inch longitudinal tear in the anterior aspect of the distal esophagus. After extension of the incision into the left thorax, the distal esophagus was resected and an esophagogastrostomy performed with the end-to-end anastomosis (EEA) stapling device. In addition, a pyloroplasty and Thal fundoplication, a feeding jejunostomy, and incidental splenectomy were performed. After several days in the intensive care unit, she had a satisfactory postoperative recovery. An exploratory laparotomy with no significant findings was performed three weeks later for severe abdominal pain. Currently the patient is receiving psychiatric treatment for persistent abdominal pain and analgesic dependency.

Discussion

Angelchik and Cohen⁵ reported 46 cases of prosthesis implantation without mortality. One patient had a gastric perforation unrelated to the prosthesis, and 14 patients had transient dysphagia. The median period of follow-up was 21 months. Starling et al⁶ reported 28 procedures without mortality. Short-term follow-up revealed no recurrent hiatal hernias, but 7 patients had transient dysphagia and one had persistent "gas bloat" syndrome. In addition, the prosthesis was disrupted and had migrated to the pelvis in one case, and into the mediastinum in another. Peloso⁸ reported 5 cases of intra-abdominal migration of the prosthesis. A product improvement, the circumferential one-strap device, is an attempt to prevent migration.

Lackey and Potts⁹ reported a case of a prosthesis that had penetrated the stomach, after functioning for five months postoperatively. In addition to the erosion on the greater curvature of the stomach, dense omental adhesions were noted. Malposition of the prosthesis, either from inappropriate placement or migration, was thought to be the cause of this gastric injury; treatment involved removal of the prosthesis and partial gastrectomy. The manufacturers report 15 cases of entry of the prosthesis into the gastrointestinal tract. (Communication from Vassalo TM, American Heyer-Schulte Corporation, Aug 12, 1982.) These cases were usually associated with previous or concomitant gastric operations or disease and a torn or untied device. There

have been five postoperative deaths from prosthesis implantations, but none were directly related to the prosthesis.

Although the cause of this late development of esophageal perforation is unknown, it may be postulated that the prosthesis became surrounded by dense fibrosis and that extreme sheer forces were exerted on the distal esophagus during episodes of emesis. This could have resulted in esophageal perforation. The surrounding adhesions contained the esophagogastric secretions within a localized area, thus moderating the symptoms usually present in Boerhaave's syndrome.

In view of recent reports such as our own, we would advise caution with respect to this procedure until long-term follow-up data are available. There is certainly reason to question the wisdom of placing a permanent prosthesis in young people and in those who have had previous upper abdominal surgery or adhesions.

References

1. Postlethwait RW. *Surgery of the Esophagus*. Appleton-Century-Crofts, New York, 1979.
2. Nissen R. Gastropexy and "fundoplication" in surgical treatment of hiatal hernia. *Am J Dig Dis* 1961; **6**: 954-961.
3. Skinner DB, Belsey RHR. Surgical management of esophageal reflux and hiatus hernia; long-term results with 1030 patients. *J Thorac Cardiovasc Surg* 1967; **53**: 33-54.
4. Hill LD. An effective operation for hiatal hernia; an eight year appraisal. *Ann Surg* 1967; **166**: 681-692.
5. Angelchik J, Cohen R. A new surgical procedure for the treatment of gastroesophageal reflux and hiatal hernia. *Surg Gynecol Obst* 1979; **148**: 246-248.
6. Starling JR, Reichelderfer MO, Pellett JR, Belzer FO. Treatment of symptomatic gastroesophageal reflux using the Angelchik prosthesis. *Ann Surg* 1982; **195**: 686-691.
7. Polk HC [in discussion]: Starling JR, Reichelderfer MO, Pellett JR, Belzer FO. Treatment of symptomatic gastroesophageal reflux using the Angelchik prosthesis. *Ann Surg* 1982; **195**: 686-691.
8. Peloso OA. Intra-abdominal migration of an antireflux prosthesis; a cause of bizarre pain. *JAMA* 1982; **248**: 351-353.
9. Lackey C, Potts J. Penetration into the stomach; a complication of the antireflux prosthesis. *JAMA* 1982; **248**: 350.