

Nocardia osteomyelitis and epidural abscess in the nonimmunosuppressed host¹

John M. Petersen, D.O.²
Issam Awad, M.D.
Muzaffar Ahmad, M.D.
Janet W. Bay, M.D.
Martin C. McHenry, M.D.

We present a case of invasive nocardiosis in a nonimmunosuppressed host with pulmonary and neurosurgical complications, treated successfully with extensive surgical debridement and long-term antibiotic therapy. No underlying neoplasm or cellular or humoral immune defect was detected. The Cleveland Clinic's experience with nocardiosis from 1967–1982 is reviewed. This review exemplifies the well-described augmented risk of *Nocardia* infection in the immunosuppressed host with a history of prolonged antibiotic, corticosteroid, or cytotoxic therapy, along with malignancy and cellular immunity dysfunction. The spectrum of invasive pulmonary nocardiosis in the nonimmunosuppressed patient should be recognized so as to understand the natural history and prognosis of this potentially lethal infection.

Index terms: Spinal canal, abscess • Lung abscess • *Nocardia asteroides* • Osteomyelitis

Cleve Clin Q 50:453–459, Winter 1983

¹ Departments of Internal Medicine (J.M.P.), Pulmonary Disease (A.M.), Neurosurgery (I.A., J.W.B.), and Infectious Disease (M.C.M.), The Cleveland Clinic Foundation. Submitted for publication June 1983; accepted Aug 1983.

² Present address: Yale University School of Medicine, Dept. Internal Medicine, Section of Gastroenterology, 92 LMP, P.O. Box 3333, New Haven, CT 06510.

Since Nocard's description of a strange granulomatous disease of cattle called "bovine farcy" on the island of Guadeloupe in 1888¹ and Eppinger's "pseudotuberculosis" *Nocardia* brain abscess in 1890,² only 300 cases of nocardiosis had been described before 1976. *Nocardia asteroides* (NA), a slow-growing soil saprophyte and an aerobic Actinomycetale, is the only one of its group able to infect the central nervous system. Most authors agree that *Nocardia* isolated from sputa from the immunosuppressed host should be regarded as an active infection.^{3–5}

The branching filaments of *Nocardia* are capable of terminal growth, or may rise into the air like the hyphae of

true fungi. The bacterial nature of the actinomycetes is exhibited by their delicate structure and the chemical composition of the cell wall. In vitro, *N. asteroides* fails to digest casein, tyrosine, or xanthine, but if decolorized with 1% H₂SO₄, it will be mildly acid-fast.

The literature abounds with *Nocardia* cases related to the immunosuppressed host,⁶ such as those with leukemia, lymphoma, systemic lupus erythematosus,⁷ nephrosis, ulcerative colitis, Cushing's disease, Whipple's disease, asthma, tuberculosis, diabetes mellitus, sarcoidosis, bronchiectasis, alveolar proteinosis, and renal and heart transplantation.⁸ The lesions produced from active infection are typically purulent with abscess formation, sinus tracts, fibrosis, occasional encapsulation, and, rarely, visible granules or granulomas.

Approximately 20% of nocardiosis occurs in patients receiving corticosteroids. *Nocardia* pulmonary infections may present as lobar pneumonia, single or multiple nodular densities, milary abscesses, or large cavities.^{9,10} Pulmonary infection may be associated with pleural effusion, empyema, or, as noted in our case, sinus tract infection.¹⁰ A survey done by the Center for Disease Control estimates that there are 500 to 1000 new cases of nocardiosis in the United States annually, with up to 15% occurring in nonimmunosuppressed hosts³ (persons having no defect in cellular or humoral immunity). A decade ago, Palmer reviewed 243 cases; 23% involved the central nervous system, and 49% had no apparent underlying disease process or drug reaction.¹¹ Aggressive attempts at procuring cytobacteriologic specimens, surgical debridement, and prolonged antibiotic therapy have dramatically lowered the overall mortality from this ubiquitous obligate aerobic infection.

This is the first described complex of invasive *N. asteroides* pulmonary infection in a nonimmunosuppressed host with necrotizing pneumonitis, spinal epidural abscess, Horner's and Brown-Séquard syndromes, and coexistent vertebral osteomyelitis.

Case report

Four months prior to his referral to the Cleveland Clinic, a 53-year-old construction worker from Ohio presented to his local physician with complaints of cough productive of white mucoid sputa, upper thoracic back pain, anorexia, malaise, a 20-pound weight loss, chills, and an occasional fever to 101°F. A chest roentgenogram revealed a well-defined right upper lobe infiltrate, and he was treated with erythromycin. The patient was a 75 pack/year smoker who

drank a fifth of vodka almost daily. Persistent fever, cough, and neurologic findings prompted hospitalization.

Physical examination revealed right-sided hypoesthesia with loss of pain and temperature sensation on the left, below T₅, along with a right Horner's syndrome. The infiltrate was unchanged following a 10-day course of erythromycin. An intermediate-strength purified protein derivative (PPD) was nonreactive. Pantopaque myelography showed a complete blockage of contrast agent above T₄. Emergency decompressive laminectomy revealed destruction of T₃ and marked epidural cord compression. Sputum samples were reported as growing *N. asteroides*. Results of fiberoptic bronchoscopy, a CT scan of the brain, and analysis of the cerebrospinal fluid (CSF) were reportedly normal, and the patient was transferred to the Cleveland Clinic Hospital.

Physical examination at the time of admission revealed a deeply encephalopathic man with a right Horner's syndrome and marked left lower extremity weakness with rectal and urinary incontinence. He was disoriented to time and place, could not calculate, and was withdrawn and hallucinating at times. Head and neck examinations revealed right ptosis and meiosis. There was no lymphadenopathy. The chest was clear save for decreased breath sounds in the right upper thorax and egophony apically. The cardiovascular examination was within normal limits. The liver was firm and nodular, percussing to 14 cm. On neurologic review, the lower extremities were spastic and hyperreflexic with bilateral upgoing toes. There was loss of fine touch, pin, proprioception, and vibratory sense in the legs, right greater than left. There was loss of pain and temperature sense in the left lower extremity. A C₄ sensory level was present on the left, which extended to T₄ on the right. The patient was not ambulatory; lower extremity paraparesis with motor strengths of 3/5 in the proximal groups on the right and 2/5 on the left were recorded. Results of the cerebellar examination were normal. The optic fundi were unremarkable, and cranial nerves were intact. A surgical wound from his recent posterior thoracic decompression was open and draining seropurulent fluid.

A complete blood count (CBC) revealed 18,000 white cells/mm³ with 20% banded neutrophils, 920 total lymphocytes, and a hematocrit of 37%. Results on the sequential multiple analyzer (SMA-18) were normal except for an alkaline phosphatase of 247 U/L, and serum glutamic oxaloacetic transaminase (SGOT) 38 U/L, serum glutamic pyruvic transaminase (SGPT) 35 U/L, and albumin 2.1 g/dl. Prothrombin time was 19 sec. with a control of 12. The partial thromboplastin time, three-hour glucose tolerance test, urinalysis, and electrocardiogram were all normal. A chest roentgenogram (Fig. 1) displayed a posterior segment right upper lobe infiltrate with mediastinal widening. A cranial CT scan, with and without contrast agent, was unremarkable. Pantopaque myelography showed persistent extradural compression at the T₂₋₄ levels (Fig. 2). The CSF contained 15 WBC (98% lymphocytes), glucose 18 g/dl (plasma 78), and total protein 30 g/dl. Results of cytologic examination were normal. Results of aerobic and fungal cultures, acid-fast stains, and *Nocardia* cultures were negative. A sector CT scan of the thoracic spine disclosed subtotal destruction of the underside of the T₂ body, pedicles, and the transverse processes of T₃ (Fig. 3).

A percutaneous aspiration biopsy specimen from the right upper lobe infiltrate was free of malignant cells, but hyphal forms were noted and confirmed to be *N. asteroides*. Cultures

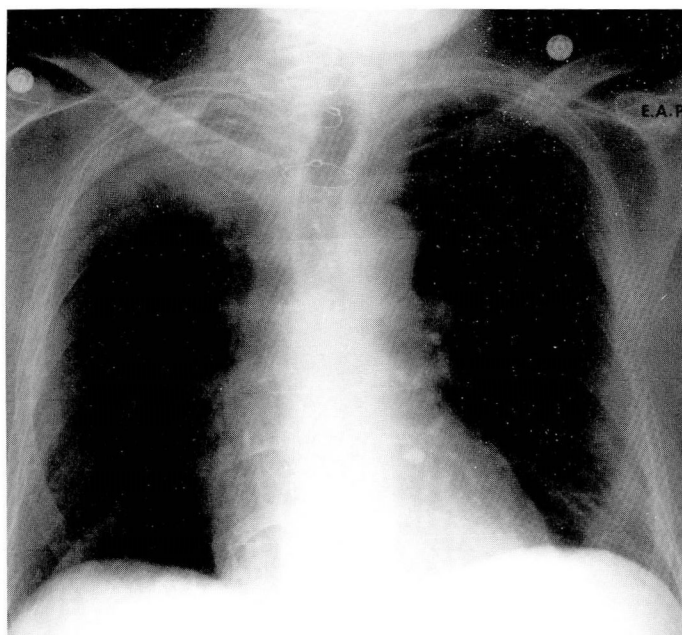


Fig. 1. Chest radiograph showing the initial right upper lobe infiltrate.

from the thoracic back wound, routine sputa, and brushings from a narrowed posterior segment of the right upper lobe obtained at fiberoptic bronchoscopy grew *Nocardia*.

Neurosurgical decompression and debridement were performed. Purulent sinus tracts and subtotal destruction of the bodies and pedicles of T₃ and T₄ were noted: T₃ was extremely unstable, and the heads of the third and fourth ribs were destroyed; the disc spaces were preserved. Phlegmonous epidural tissue was colonized with *N. asteroides*, as were the curettings from the T₃ and T₄ bodies. Persistent bilateral cord hemisection prompted a second debridement, and, eventually, a left thoracotomy approach to an anterior T₃₋₅ fusion using autologous rib. Following the initial decompression, the urine was alkalinized, and sulfadiazine (100 mg/kg/day) and ampicillin (8 g/day) were administered. Numerous subsequent blood cultures have remained sterile.

The patient's immune status was extensively evaluated. Delayed cutaneous hypersensitivity demonstrated anergy to streptokinase, mumps, *Candida*, *Trichophyton*, and intermediate PPD. Quantitative lymphocyte counts demonstrated B-cells (via polyvalent antisera) at 5% (normal, 14.7% \pm 4.3%), T-cells (via E-rosette technique) at 55% (normal, 75.2% \pm 5.2%), SIg = 4.0. The isoagglutinins, anti-A and anti-B, were present. Quantitative immunoglobulins (sera) revealed IgG of 514 (normal, 1350 \pm 250 mg/dl), IgA 243 (normal, 155 \pm 92 mg/dl), and IgM 78 (normal, 145 \pm 100 mg/dl). The mitogen stimulation, lymphocyte transformation studies revealed the following (via HJ³DR uptake):

Control = 214

- a) Phytohemagglutinin (PHA) = 64,671
- b) Pokeweed mitogen (PWM) = 33,944
- c) Concanavalin A (ConA) = 48,824

These findings are all normal for our laboratory.

Serum complement assays: C3 Beta IC/Beta IA was 200 (normal, 80–250 mg/dl); C4 was 36 (normal, 14–51 mg/dl); and CH₅₀ was 104 (normal, 70–185 mg/dl). Levels of

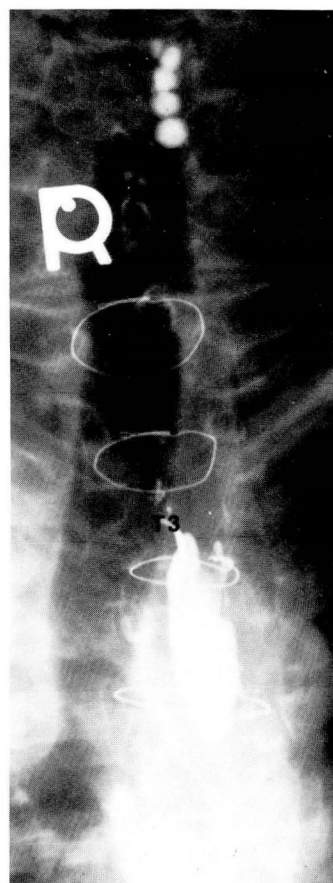


Fig. 2. Pantopaque myelogram demonstrating abrupt cutoff of contrast flow at the level of T₃.

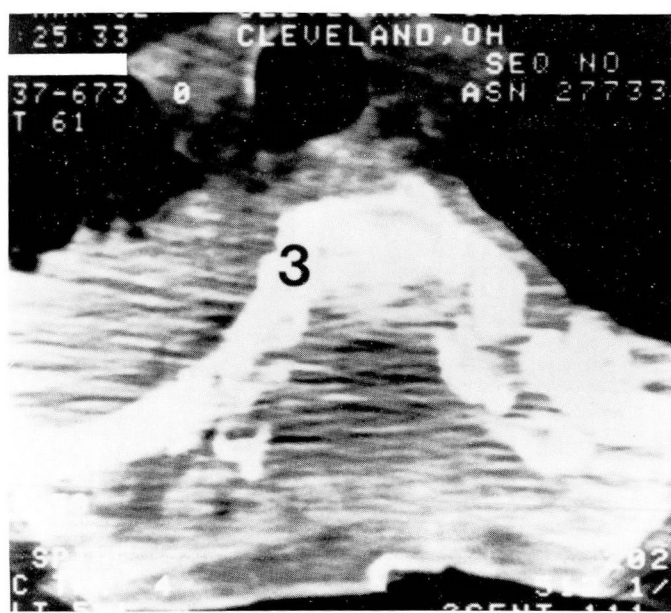


Fig. 3. CT sector scan reveals destruction of the body, transverse processes, pedicle, and rib at the level of T₃.

circulating immune complexes measured by the C1q binding method were normal. T-lymphocyte subsets revealed normal qualitative and quantitative levels of "helper"/inducer T-cells (oKT4+) and "suppressor" cytotoxic/T-cells (oKT8+). Migratory inhibition factor assay showed a normal response to *Candida* antigen. Tests for lymphocyte transformation and migratory inhibition factor in response to the patient's *N. asteroides* antigen were not technically feasible.

Final postoperative cultures of the back wound, sputa, urine, blood, and CSF have remained sterile. Serial chest roentgenograms have shown nearly total resolution of the right upper lobe infiltrate. Postoperative bilateral long tract signs persist, being less severe, whereas the sensory levels, Brown-Séquard components, and encephalopathy have cleared. Repeat quantitative T-cell counts have normalized, and delayed hypersensitivity skin responses to streptokinase, *Candida*, and *Trichophyton* are reactive after three months of sulfadiazine therapy.

Discussion

Our patient had epidural cord compression and contiguous vertebral osteomyelitis from invasive pulmonary *N. asteroides*. Despite numerous reviews in the last 40 years of intramedullary or extradural empyemas constituting a true neurosurgical emergency, no investigators have described such an aggressive epidural process in a nonimmunosuppressed host, and no cases have advanced to the Brown-Séquard syndrome.¹²⁻¹⁵ Since its description in 1849, investigators have come to understand the Brown-Séquard syndrome (BSS) as a nontraumatic intramedullary or traumatic hemisection of the spinal cord with monoplegia and loss of proprioception ipsilateral

to the insult, with contralateral loss of pain and temperature.¹⁶ In addition, nontraumatic BSS has been described in a number of other inflammatory states such as epidural hematomas, lues, contiguous osteomyelitis, and herniating nucleus pulposus.¹⁷⁻²⁰

The first account of spinal cord nocardiosis was reported in a 38-year-old housewife with lower extremity paraparesis, a right upper lobe infiltrate, sputa and skin lesions that cultured *N. asteroides*, and a rapid demise in three weeks despite treatment with sulfadiazine.²¹ Epstein described a 55-year-old nonimmunosuppressed man with back pain, inability to walk, a right upper lobe infiltrate, and a draining right supraclavicular mass with thoracic nocardial epidural cord compression. Decompressive laminectomy, debridement, and more than three months of tetracycline and sulfisoxazole therapy resulted in avoidance of major morbidity and potential mortality. Interestingly enough, as in our case, the disc spaces were preserved, with erosion of ribs, pedicles, and numerous transverse processes. Because of its propensity to involve rib heads, actinomycotic bone disease differs from metastatic cancer and tuberculosis in that it spares the intervertebral disc spaces.²²

Vertebral osteomyelitis is an unusual manifestation of localized or disseminated *Nocardia* infections. Only 3 other cases have been reported in the world literature, all of them presenting as a myelopathy. One case involving the cervical spine was treated medically, whereas the other 2 were thoracic with contiguous osteomyelitis, with only one culture proved.²²⁻²⁴ Hematogenous dissemination or contiguous invasion are the routes of vertebral involvement. The valveless venous sinuses communicating between the retropleural veins and the epidural venous plexus of Batson provide a potential anatomic route for such hematogenous spread.^{25,26}

In their review of 147 cases of nocardiosis, Presant et al²⁷ summarized many of the features seen in our case. In that study, 69% of the victims were men, 79% had some variety of pulmonary involvement, and 44% had central nervous system features (none with BSS or Horner's syndrome). Eleven weeks was the mean duration of symptoms prior to diagnosis. A mortality of 81% was noted with disseminated infection, with no difference in mortality rate based on site of the primary infection, preexisting systemic disease, or prior drug or cytotoxic therapy. Furthermore, systemic infection occurred as frequently in

healthy as in immunosuppressed hosts. Mortality rose to 85% in the presence of any of the following features: (1) acute visceral symptoms for less than three weeks, (2) use of corticosteroids or cytotoxics (3), or spread to noncontiguous organs.²⁷

As of 1981, only 4 cases of *Nocardia* brain abscess have been healed by drugs alone, which stresses the need for aggressive surgical debridement.²⁸ A study from the Mayo Clinic of 25 cases in 24 months made it quite clear that the *Nocardia* organism is not a contaminant or laboratory saprophyte; in fact, *Nocardia* species were verified in only 0.05% of the 40,000 cultures done during this time.²⁹ Although the portal of entry in at least 75% of cases is the pulmonary tree, gastrointestinal origins have also been described.^{30,31}

It has been postulated that healthy hosts harbor this organism without apparent clinical consequence (similar to other commensals in man), but conclusive evidence of a reservoir of subclinical disease is lacking. In similar experiments from separate laboratories, killing of *N. asteroides* in immune macrophages for up to 60 days occurs in guinea pigs challenged with intraperitoneal NA inoculums. It appears that humoral activity has little role in host protection against *Nocardia* species. In patients passively immunized by spleen cell transfer from donors immunized with either live NA or P-RNA, the investigators found a decrease in intracellular NA in the peritoneal macrophages. In addition, host resistance was found to be markedly impaired when antimacrophage sera were given prior to the NA inoculum, with death ensuing in five days.³²⁻³⁴

Since corticosteroids have clearly been shown to suppress macrophage function, it is understandable how rampant nocardiosis can become when these drugs are administered.³⁵ A recent study has described invasive nocardiosis in the presence of an "apudoma" as part of the multiple endocrine adenomatosis (MEA I) syndrome. An undifferentiated adrenocorticotrophic hormone (ACTH)-producing islet cell neoplasm provided the impetus for a life-threatening infection.³⁶

Mortality has been 30% in the Cleveland Clinic's experience with *Nocardia* in the last 15 years (Table). Only 3 of the 13 cases (nos. 2, 5, and 10) were free of illness associated with a humoral or cellular immune defect or pharmacologic immunosuppression. We believe that alcohol abuse and, likely, alcoholic cirrhosis, along with obstructive airway disease and poor nutrition, made our patient a more suitable recipient for this

opportunistic infection. The patient's cellular immune dysfunction and mild hypogammaglobulinemia had been altered by the infection and chronic illness itself in that these conditions were corrected following surgical drainage, prolonged antibiotic therapy, and rehabilitation. For purposes of discussion in this case report and in those patients seen at the Cleveland Clinic between 1967 and 1982, immunosuppression implies no discernible defect in humoral or cellular immunity. Other conditions such as malnutrition, alcoholism, and chronic liver or lung disease may predispose the host to *Nocardia* infection (e.g., cases 2, 10, and 13) but are not proven determinants in the acquisition of this opportunistic pathogen. The Table shows that degree of immunosuppression; age, sex, and race of the host; or underlying condition do not correlate well with manifestations or site of *Nocardia* infection, or outcome. It is also noteworthy that extensive surgical debridement was necessary in only one (case 13) of the 13 cases. As in many cases reported in the literature, 7 of 13, or 54% of our patients were taking glucocorticoids.

The recent literature has numerous pharmacologic treatment regimens for nocardiosis, along with ideal minimal inhibitory concentrations to assure eradication. Many drugs suppress the growth of *Nocardia* effectively, including the sulfonamides, ampicillin, tetracycline, erythromycin, trimethoprim, rifampin, the aminoglycosides, and cycloserine. Most reports show significant improvement in survival in patients treated for six months or longer. However, there are reports of cures in patients treated for less than four weeks^{37,38} and, on the other hand, relapses of systemic nocardiosis following five prior months of pharmacotherapy.³⁹

With greater physician awareness, aggressive attempts at surgical debridement and procurement of fresh tissue for culture, refined staining and plating techniques, and prolonged antibiotic therapy, mortality from nocardiosis has fallen from close to 70% to less than 30% in the last two decades.⁴⁰ Our case presentation and review of the Cleveland Clinic's experience with *Nocardia* demonstrate this improvement in overall mortality (30%). However, in the immunosuppressed host with disseminated infection, mortality rates totaled 80% in a large series just ten years ago, with death commonly resulting from superimposed infection, pulmonary hemorrhage, and respiratory failure.²⁷

Clinical presentation of an apical pulmonary

Table. Nocardiosis at the Cleveland Clinic, 1967–1982

Case	Age/Race/Sex	Underlying condition	Culture source	Species	Treatment	Outcome of nocardiosis
1	77/B/F	Myeloproliferative syndrome; steroids for three months	Brain; LLL (effusion)	NA	Gantrisin	Died
2	69/W/M	Horticulturist; left arm sporotrichosis; COPD	Right leg pustule	NB	I and D sulfa-methoxypyridazine	Alive
3	18 mo/B/M	Asthma; steroids; right arm nodule; hypogammaglobulinemia	Open-lung biopsy upper lobe nodules	NA	Bactrim/oxacillin	Alive
4	57/W/M	Wegener's; diabetes mellitus; cyclophosphamide and steroids	RUL cavity; blood and urine	NA	Sulfadiazine	Alive
5	65/B/M	Postop sepsis	Blood	N.A.	None	Alive
6	63/B/M	Undiff bronchogenic; Type II DM; COPD	LUL cavity; sputa	NC	Sulfadiazine	Alive
7	49/W/M	CML; blastic left temporal lobe mass	CSF	NA	Sulfadiazine	Died
8	37/W/F	Polymyositis; steroids; hyperthyroidism	LUL asp biopsy	NA	Sulfadiazine	Alive
9	28/W/M	Stage IV ^b Hodgkin's; remote chemo and RT	Right hip nodule	NA	Sulfisoxazole	Alive
10	65/W/M	Alcoholism; COPD; recent CVA	Brain, lung abscess and pleural effusion	NA	Sulfadiazine	Died
11	35/W/M	CRF; cadaveric tx; GVHD; steroids and azathioprine	Brain—occipital cortex	NA	Sulfadiazine and sulfisoxazole	Alive
12	47/W/M	MEA I; parathyroid adenomas; Zollinger-Ellison; ectopic Cushing's	Right chest nodules	NA	Sulfadiazine and cycloserine	Died
13	53/W/M	Alcoholism; COPD	Necrotizing right upper lobe pneumonia; thoracic epidural abscess; thoracic vertebrae (osteomyelitis)	NA	Surgical debridement; ampicillin; sulfadiazine	Alive

NA = *Nocardia asteroides*; NB = *Nocardia brasiliensis*; NC = *Nocardia caviae*; GVHD = graft-vs-host disease; MEA I = multiple endocrine adenomatosis I; LLL = left lower lobe; COPD = chronic obstructive pulmonary disease; I and D = incision and drainage; RUL = right upper lobe; undiff = undifferentiated; Type II DM = Type II diabetes mellitus; LUL = left upper lobe; CML = chronic myelogenous leukemia; CSF = cerebrospinal fluid; ASP = aspiration; chemo and RT = chemotherapy and radiation; CVA = cerebrovascular accident; CRF = chronic renal failure; cadaveric tx = cadaveric transplant.

density along with the Horner's syndrome and contiguous bone destruction is nearly pathognomonic for a Pancoast tumor. However, our case study stresses the importance of considering nocardiosis in the differential diagnosis. We believe that all cases of nocardiosis should be investigated with humoral and cellular immunity studies to delineate this group of apparently nonimmunosuppressed patients so that we may better understand the natural history and prognosis of this potentially devastating infection.

References

1. Nocard E. Note sur la maladie des boeufs de la Guadeloupe connue sous le nom de farcin. Ann Inst Pasteur 1888; 2:293.
2. Eppinger H. Über eine neue Pathogene cladotrix und eine durch sie hervorgerufene Pseudotuberculosis. Wien Klin Wochschr 1890; 3:321.
3. Beaman BL, Burnside J, Edwards B, Causey W. Nocardial infections in the United States, 1972–1974. J Infec Dis 1974; 134:286–289.
4. Smith DE, Benecke J. Pulmonary nocardiosis: report of a fatal case. Med J Aust 1960; 47:254–258.
5. Williams DM, Krick JA, Remington JS. Pulmonary infection in the compromised host. Am Rev Respir Dis 1976; 114:359–394.
6. Mathay RA, Greene WH. Pulmonary infections in the immunocompromised patient. Med Clin NA 1980; 64:529.
7. Gorevic PD, Katler EI, Agus B. Pulmonary nocardiosis: occurrence in men with systemic lupus erythematosus. Arch Intern Med 1980; 140:361–363.
8. Krick JA, Stinson EB, Remington JS. Nocardia infection in heart transplant patients. Ann Intern Med 1975; 82:18–26.

9. Balikian JP, Herman PG, Kopit S. Pulmonary nocardiosis. *Radiology* 1978; **126**:569–573.
10. Neu HC, Silva M, Hazen E, Rosenheim SH. Necrotizing nocardial pneumonitis. *Ann Intern Med* 1967; **66**:274–284.
11. Palmer DL, Harvey RL, Wheeler JK. Diagnostic and therapeutic considerations in *Nocardia asteroides* infections. *Medicine* 1974; **53**:391–401.
12. Baker AS, Ojemann RG, Swartz MN, Richardson EP. Spinal epidural abscess. *N Engl J Med* 1975; **293**:463–468.
13. Browder J, Meyers R. Infections of the spinal epidural space: an aspect of vertebral osteomyelitis. *Am J Surg* 1937; **37**:4–26.
14. Heusner AP. Nontuberculous spinal epidural infections. *N Engl J Med* 1948; **239**:845–854.
15. Petersen RL. Cervical epidural abscess producing acute paraplegia. *S Afr Med J* 1962; **36**:703–704.
16. Brown-Séquard M. De la transmission des impressions sensibles par la Moelle Epiniere. *Comptes Rendus des séances de la Société de Biologie* 1849; **1**:192.
17. Russman BS, Kazi KH. Spinal epidural hematoma and the Brown-Séquard syndrome. *Neurology* 1971; **21**:1066–1068.
18. Stammers FAR. Epidural suppuration with special reference to osteomyelitis of vertebrae. *Osteomyelitis*. *Br J Surg* 1938; **26**:366–374.
19. Stookey B. Compression of spinal cord and nerve roots by herniation of the nucleus pulposus in the cervical region. *Arch Surg* 1940; **40**:417–432.
20. Davidson RI, Zajac JJ. Spinal epidural empyema with the Brown-Séquard syndrome. *Surg Neurol* 1978; **9**:195–197.
21. Welsh JD, Rhoades ER, Jaques W. Disseminated nocardiosis involving the spinal cord. Case report. *Arch Intern Med* 1961; **108**:73–79.
22. Epstein S, Holden M, Feldshuh J, Singer JM. Unusual cause of spinal cord compression: nocardiosis. *NY State J Med* 1963; **63**(PT 2):3422–3427.
23. Cruickshank JG, Riley MJ, White RM. Nocardiosis and actinomycosis in the Mashonaland province of Rhodesia. *Cent Afr J Med* 1975; **21**:152–158.
24. Lytton DG, Hamilton DR. Mycetoma in PNG with special reference to a case of New Guinea extradural mycetoma. *Papua New Guinea Med J* 1975; **18**:61–65.
25. Natarajan M, Muthu AK, Arumugham K. Nocardial extradural granuloma causing spinal cord compression. *Neurol India* 1974; **22**:97–99.
26. Reinhard KR, Miller ME, Evans HE. The craniovertebral veins and sinuses of the dog. *Am J Anat* 1962; **111**:67–87.
27. Presant CA, Wiernik PH, Serpick AA. Factors affecting survival in nocardiosis. *Am Rev Respir Dis* 1973; **108**:1444–1448.
28. Smith PW, Steinkraus GE, Henricks BW, Madson EC. CNS nocardiosis. Response to sulfamethoxazole-trimethoprim. *Arch Neurol* 1980; **37**:729–730.
29. Frazier AR, Rosenow EC, Roberts GD. Nocardiosis. A review of 25 cases occurring during 24 months. *Mayo Clin Proc* 1975; **50**:657–663.
30. Hickey RC, Berglund EM. Nocardiosis. Aerobic actinomycosis with emphasis on the alimentary tract as portal of entry. *Arch Surg* 1953; **67**:381–391.
31. Cuttino JT, McCabe AM. Pure granulomatous nocardiosis: new fungus disease distinguished by intracellular parasitism; description of new disease in man due to hitherto undescribed organism, *Nocardia intracellularis*, n. sp., including study of biologic and pathogenic properties of this species. *Am J Pathol* 1949; **25**:1–47.
32. Sundararaj T, Agarwal SC. Relationship of macrophages to cell-mediated immunity in experimental *Nocardia asteroides* infection. *Infect Immun* 1978; **20**:685–691.
33. Krick JA, Remington JS. Resistance to infection with *Nocardia asteroides*. *J Infect Dis* 1975; **131**:665–672.
34. Sundararaj T, Agarwal SC. Cell-mediated immunity in experimental *Nocardia asteroides* infection. *Infect Immun* 1977; **15**:370–375.
35. Fauci AS, Dale DC, Balow JE. Glucocorticosteroid therapy: mechanisms of action and clinical considerations. *Ann Intern Med* 1976; **84**:304–315.
36. Higgins TL, Calabrese LH, Sheeler LR. Opportunistic infections in patients with ectopic ACTH-secreting tumors. *Cleve Clin Q* 1982; **49**:43–49.
37. Murray JF, Finegold SM, Froman S, Will DW. The changing spectrum of nocardiosis. *Am Rev Respir Dis* 1961; **83**:315–330.
38. Geisler PJ, Andersen BR. Results of therapy in systemic nocardiosis. *Am J Med Sci* 1979; **278**:188–194.
39. Geisler PJ, Check F, Lamothe F, Andersen BR. Failure of trimethoprim-sulfamethoxazole in invasive *Nocardia asteroides* infection. *Arch Intern Med* 1979; **139**:355–356.
40. Rosett W, Hodges GR. Recent experiences with nocardial infections. *Am J Med Sci* 1978; **276**:279–285.