

# Removal of massive ovarian tumor: case report and a critical review of surgical management and postoperative care<sup>1</sup>

Alexander W. Kennedy, M.D.

A 31-year-old woman had a massive ovarian tumor and multiple associated metabolic abnormalities. Preoperative care included correction of cachexia-induced dehydration, hyperkalemia, azotemia, anemia, and hypoproteinemia. Hyperalimentation was also instituted because of profound malnutrition. Complete cardiovascular monitoring was used preoperatively to maximize her status and specifically to improve intravascular volume and cardiac output. At surgery, a 60–65-kg ovarian mucinous cystadenocarcinoma of low malignant potential was removed, and a Swan-Ganz catheter was inserted to monitor therapy for resultant hypovolemic and splanchnic shock. Postoperative complications included adult respiratory distress, sepsis, hemorrhagic ulcerative cytomegalic virus colitis, and acute tubular necrosis. Eventually the patient died of hemorrhagic necrotizing cytomegalic virus pneumonitis. The surgical therapy of massive ovarian tumors and resultant complications are reviewed.

**Index terms:** Ovary, neoplasm • Ovary, surgery

**Cleve Clin Q 50:** 461–464, Winter 1983

Previous case reports have emphasized the problems encountered in the removal of massive (>11.35 kg) ovarian tumors and the myriad of potential complications during surgery and the postoperative period.<sup>1–3</sup> The approximately 50% mortality related to removing masses >45.4 kg<sup>1,3</sup> requires the full resources of modern critical care medicine. Balloon-tipped cardiac (Swan-Ganz) catheters have been increasingly used to monitor the critically ill patient<sup>4–6</sup> and would be expected

to be helpful in the management of women with massive ovarian tumors. We present the first reported use of advanced hemodynamic monitoring in a patient with a massive ovarian tumor whose course was marked by multiple complications affecting both the cardiovascular and respiratory systems. Although she eventually died as a result of overwhelming viral infection, hemodynamic monitoring facilitated management of many of the other postoperative problems encountered. A critical review of the literature indicates that many of these complications are predictable and that their recognition and treatment may be improved by complete Swan-Ganz monitoring.

## Case report

A 31-year-old white woman was seen in the Emergency Room with the complaint of increasing abdominal girth and progressive severe debility. Two years previously, the patient was noted on pelvic examination to have a 25-cm ovarian mass, but refused recommended medical care. Complete urinary incontinence and severe abdominal distension eventually forced her to seek medical attention.

At the time of admission, the patient was unable to move, was severely cachectic and dyspneic, and appeared to be in extreme distress. She was hypothermic (34.3 °C); her pulse was 120 beats/min; and blood pressure was 110/90 mm Hg. Weight was 106.7 kg; height 163 cm. There was marked wasting of the upper body and upper extremities, and the abdomen was massively distended (*Fig. 1*). The abdominal girth was 175 cm. The lower extremities were severely edematous, and decubitus ulcers were present in the presacral and posterior tibial areas. Pelvic examination was not possible.

Results of initial laboratory studies included the following values: sodium, 116 mEq/L; carbon dioxide, 17 mEq/L; blood urea nitrogen (BUN), 83 mg/dl; creatinine, 2.3 mg/

<sup>1</sup> Department of Gynecology, The Cleveland Clinic Foundation. Submitted for publication April 1983; accepted June 1983.

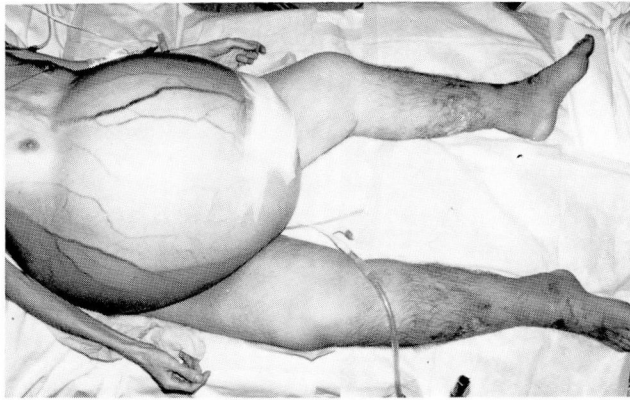

Fig. 1. Patient shortly after admission.

dl; total protein, 7.7 g/dl; albumin, 3.2 g/dl; and uric acid, 9.7 mg/dl. Immediate measures were instituted to correct the hyperkalemia and dehydration. Following intravenous hydration, laboratory values were: hemoglobin, 8.7 g/dl; hematocrit, 27%; white blood cell count,  $14.0 \times 10^9/L$ ; platelets,  $213 \times 10^9/L$ ; serum sodium, 128 mEq/L; serum potassium, 4.7 mEq/L; BUN, 73 mg/dl; serum creatinine, 1.0 mg/dl; total serum protein, 5.7 g/dl; and serum albumin 2.6 g/dl. Gynecologic consultation was obtained, and the diagnosis was probable giant mucinous cyst of the ovary. Skin testing for mumps, *Candida*, *Trichophyton*, and purified protein derivative (PPD) were all negative. Hyperalimentation was initiated on the third hospital day.

The patient was transferred to the Surgical Intensive Care Unit 48 hours preoperatively. A Swan-Ganz catheter was inserted, and the following initial values were obtained: pulmonary artery pressure, 26/10 mm Hg, mean 19 mm Hg; pulmonary capillary wedge pressure, 7 mm Hg; and central venous pressure, 7 cm H<sub>2</sub>O. Her cardiac output was calculated to be 5.85 L/min with a cardiac index of 2.75 L/min/M<sup>2</sup>. Preoperative administration of crystalloid solutions and whole blood increased her intravascular volume and improved her hemodynamic status. The cardiac output rose to 7.37 L/min, and the pulmonary wedge pressure increased to 10 mm Hg.

On the eighth hospital day an exploratory laparotomy was performed. Anesthesia was introduced in a sitting, partially recumbent position without significant changes in cardiovascular status. The abdomen was opened through a subumbilical transverse incision with minimal blood loss. A massive multiloculated mass was encountered adherent to the anterior parietal peritoneum. During dissection, many cysts ruptured, releasing approximately 25 L of viscous mucinous fluid. The remaining portion of the left ovarian mass was delivered and removed without further technical difficulties. The patient immediately became severely hypotensive with mean arterial pressure of 20 mm Hg; pulse 150 beats/min; pulmonary artery pressure, 16/4 mm Hg; and pulmonary wedge pressure, 2 mm Hg (Fig. 2). The aorta was manually occluded, and rapid fluid and blood product administration was begun. After one hour, the hemodynamic factors gradually improved, but oozing began from multiple points of previous adherence to the peritoneum and liver. These areas were repeatedly sutured and hemostasis was eventually secured with difficulty. The hematocrit was 23% and platelet count  $21 \times 10^9/L$  during the

latter part of the procedure. The partial thromboplastin time was 37 sec. (control, 21–31 sec.) and prothrombin time, 18 seconds (control, 13 sec.). Eighteen hours postoperatively the patient became severely hypotensive again with evidence of poor perfusion. Fluid resuscitation and epinephrine drip corrected these problems, but she required continued intensive hemodynamic and pulmonary support.

The final pathology diagnosis from the removed mass was ovarian mucinous cystadenoma with focal low malignant potential carcinoma and pseudomyxoma ovarii. The submitted mass weighed 35.4 kg and the total mass, including fluid spillage, was estimated to be 60–65 kg. Even after receiving large amounts of fluid and developing severe ascites, the patient weighed 48 kg less on the second postoperative day than preoperatively.

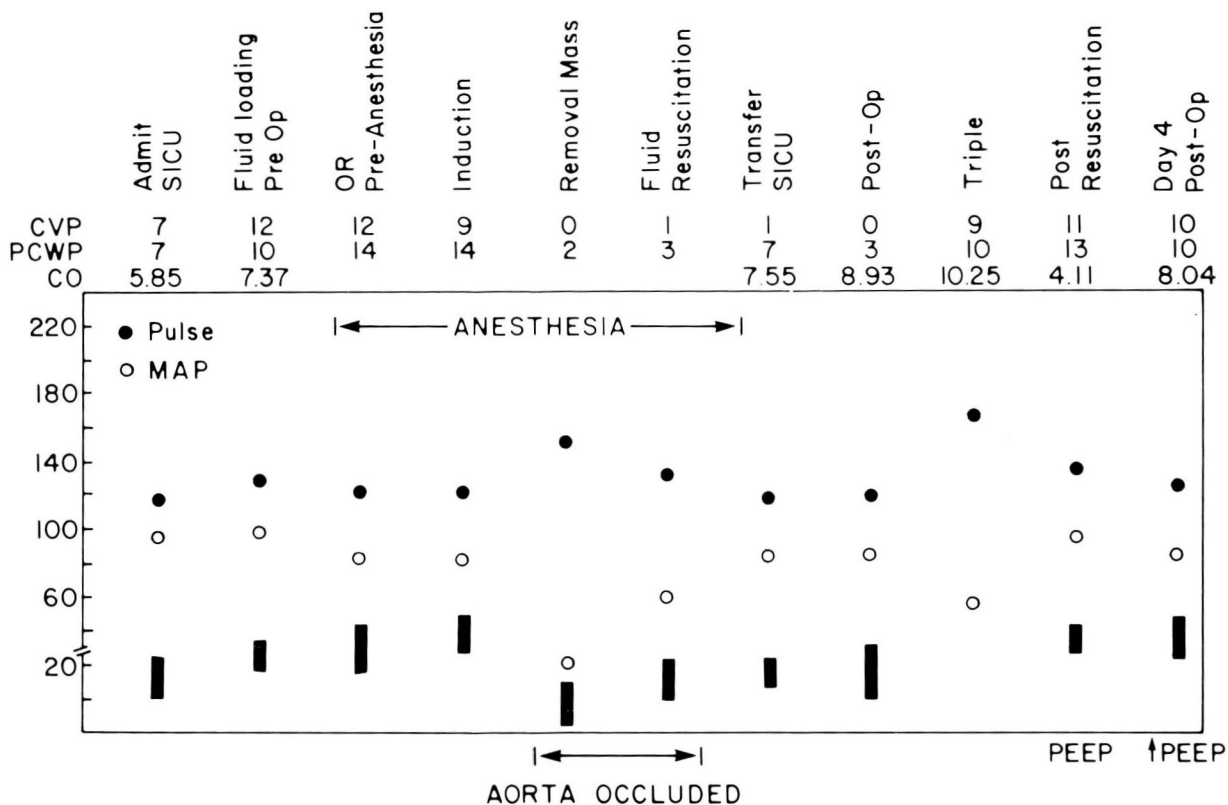
The remainder of the postoperative course was marked by numerous complications. The patient was never able to leave the intensive care unit or to be extubated. Hyperalimentation did not correct nutritional depletion. Adult respiratory distress developed, and sepsis occurred repeatedly during the first postoperative week. Laparotomy and right hemicolectomy were performed on the 40th postoperative day for hemorrhagic ulcerating cytomegalic virus colitis. Recurrent sepsis did not respond to antibiotics, and acute renal tubular necrosis requiring dialysis eventually developed.

The patient died on the 64th postoperative day after other complications as a result of hemorrhagic necrotizing cytomegalic virus pneumonitis and pulmonary failure.

## Discussion

In 1963, Symmonds et al<sup>3</sup> reported the removal of an 80-kg ovarian mucinous cystadenocarcinoma and aptly commented: "The surgical removal of a tumor of this dimension represents only the initial and perhaps the simplest aspect of the patient's therapy. The alterations in metabolism, fluid and electrolyte balance, and blood volume associated with the loss of more than twenty gallons of fluid and the loss of more than fifty percent of the body weight are entirely unimaginable." This statement summarizes well the postoperative problems encountered in managing this most tragic case. The potential complications are innumerable and require anticipation and monitoring in an intensive care setting with comprehensive aggressive modern management.

The preoperative condition of the patient must be carefully assessed and particular attention paid to nutritional status as the eventual outcome is greatly dependent upon this factor. These patients are often severely debilitated and cachectic as a result of long-standing neglect of the illness. Anergy is a particularly worrisome finding as it predicts a tenfold increase in mortality.<sup>7</sup> Hyperalimentation must be considered in the preoperative management. Severe fluid and electrolyte



**Fig. 2.** Hemodynamic measurements (CVP = central venous pressure, cm H<sub>2</sub>O; PCWP = pulmonary capillary wedge pressure, mm Hg; CO = cardiac output, L/min; MAP = mean arterial pressure, mm Hg; PEEP = positive end expiratory pressure; dark bars = pulmonary artery pressure, systolic/diastolic, mm Hg).

disorders must be corrected and underlying medical disorders identified. Preoperative hemodynamic monitoring is likewise critical to maximize the severely stressed cardiovascular system. Preoperative paracentesis has been successfully used in some reported cases but is not generally recommended.<sup>8,9</sup> Besides cyst rupture and fluid spillage, this procedure may expose the patient to risk of cardiovascular collapse in a nonoperative setting if excessive fluid is removed. The viscosity of the cyst fluid in the current case precluded decompression by paracentesis. Preoperative preparation must also include the availability of large amounts of blood and blood products and adequate routes for administration.

The operative approach to these masses is challenging and debated. A high transverse incision has proved satisfactory in other cases<sup>3</sup> and was selected in this case because the transverse diameter offered the longest potential incision for an attempt at intact removal of the mass. This incision provided excellent exposure and healing. Ideally, ovarian masses should be removed intact, but the sudden removal of such an enormous

mass led to severe cardiovascular problems in this patient. Techniques for gradual suction decompression have been described,<sup>8,10</sup> and, had they been feasible in this case, the severe hypotension and collapse might have been avoided. The subsequent necessity for rapid blood administration in large quantities resulted in a severe thrombocytopenic coagulopathy.

Although the potential postoperative complications are many and varied, many of these patients share particular problems. Cardiovascular problems are frequently encountered. The splanchnic vascular bed and venous system of the lower extremities are compressed with an increased intravascular pressure. The sudden release of this pressure and poor sympathetic tone may produce a sudden dramatic increase in potential venous volume with venous pooling precipitating hypotension and hypoperfusion, so-called splanchnic shock.<sup>11</sup> This may also occur within the first 24 hours postoperatively and must be watched for carefully. The patient described here responded well to fluid and vasopressor therapy when this occurred 18 hours after sur-

gery. The application of a gravity suit might also be helpful in this situation by increasing venous pressure and decreasing the splanchnic bed. This was attempted in our patient but was very poorly tolerated at even low pressures because of dramatic hypertension and decreased cardiac output. Another cause of hypotension may be supine positioning.<sup>12</sup>

Advanced hemodynamic monitoring allows the determination and calculation of multiple factors in critically ill patients with impaired or rapidly changing cardiovascular systems. This has resulted in not only earlier recognition of cardiac failure (particularly left-sided failure) but also the ability to monitor the results of therapeutic interventions. Crucial factors not available with previous monitoring include pulmonary artery pressures, pulmonary capillary wedge pressure, determination of cardiac output, and sampling of mixed venous blood. These determinations allow improved assessment of pulmonary circulation, left ventricular function, and systemic perfusion. In this patient, they enabled preoperative preparations that improved intravascular volume and cardiac output. During the operative and postoperative period, the administration of fluid and blood products as well as the therapeutic effects of various cardiovascular drugs were directed by hemodynamic monitoring. This led to early recognition and prompt correction of postoperative hypotension and hypoperfusion. Likewise, Swan-Ganz monitoring was an invaluable guide in therapy of postoperative sepsis, adult respiratory distress, and massive gastrointestinal tract hemorrhage in this severely compromised patient. The use of Swan-Ganz catheter monitoring during the preoperative period in patients with massive ovarian tumors is helpful in recognizing and managing the multiple complications that can be expected in these patients.

Postoperative pulmonary complications are to be expected, and these patients usually require mechanical ventilation for varying periods of time after surgery. The diaphragmatic muscles contract poorly, and the patient must depend upon the intercostal muscles.<sup>9</sup> Infection and adult respiratory distress syndrome may be encountered. Gastrointestinal complications are com-

mon, and prolonged drainage and delayed eating have been recommended.<sup>2,3,13</sup> The patient previously described by Symmonds et al<sup>3</sup> died as a result of avascular necrosis and perforation of the cecum; our patient had hemorrhagic colitis requiring massive transfusions and eventual partial colectomy. Periodic abdominal roentgenograms may be helpful in anticipating these problems.

In summary, the patient with a massive ovarian tumor presents an extreme challenge to the gynecologic surgeon who must not only remove the mass but manage the many complications surrounding this surgery. Modern hemodynamic monitoring and intensive care are needed to maximize the chances for survival from this often fatal illness of neglect. It is hoped that observations from this single case may prove valuable in the future treatment of similar patients.

## References

1. Lynch FW, Maxwell AF. *Pelvic Neoplasms*. New York, Appleton-Century-Crofts, 1922, pp 403-412.
2. Beacham WD, Webster HD, Lawson EH, Roth LM. Uterine and/or ovarian tumors weighing twenty-five pounds or more. *Am J Obstet Gynecol* 1971; **109**:1153-1161.
3. Symmonds RE, Spraitz AF, Koelsche GA. Large ovarian tumor; report of a case. *Obstet Gynecol* 1963; **22**:473-477.
4. Forrester JS, Ganz W, Diamond G, McHugh T, Chonette DW, Swan HJC. Thermodilution cardiac output determination with a single flow-directed catheter. *Am Heart J* 1972; **83**:306-311.
5. Swan HJC. The role of hemodynamic monitoring in the management of the critically ill. *Crit Care Med* 1975; **3**:83-89.
6. Pace NL. A critique of flow-directed pulmonary arterial catheterization. *Anesthesiology* 1977; **47**:455-465.
7. Meakins JL, Pietsch JB, Bubenick O, et al. Delayed hypersensitivity: indicator of acquired failure of host defenses in sepsis and trauma. *Ann Surg* 1977; **186**:241-250.
8. Bezjian AA, O'Leary JA. A massive (121-lb) ovarian tumor—preoperative siphonage and excision; a case report. *Obstet Gynecol* 1971; **38**:214-216.
9. Hunter DJS. Management of a massive ovarian cyst. *Obstet Gynecol* 1980; **56**:254-255.
10. Buller RE, Holter H, Laros RJ, Hanson KH, Abele J. Massive ovarian mucinous cystadenoma of low malignant potential. *Obstet Gynecol* 1982; **59**:1125-1165.
11. Eames DH. Removal of 184 pound ovarian tumor and observations regarding splanchnic shock. *Am J Obstet Gynecol* 1954; **67**:1358-1364.
12. Epstein RA, Panter GG. Giant ovarian cyst and the supine hypotensive syndrome. *Anesthesiology* 1966; **27**:515-516.
13. Hoile RW. Hazards in the management of large intra-abdominal tumors. *Ann R Col Surg Eng* 1976; **58**:393-397.