

# Subclavian vein thrombophlebitis: complication of total parenteral nutrition (TPN)<sup>1</sup>

Jose M. Soto-Velasco, M.D.<sup>2</sup>  
Ezra Steiger, M.D.  
John L. Rombeau, M.D.  
David G. Jagelman, M.D.  
Faith Srp, R.N.

A retrospective analysis of 1311 patients who underwent 1611 central venous catheterizations for total parenteral nutrition (TPN) showed clinical subclavian and central venous thrombophlebitis in 11 patients (0.8%). Catheter-related complications occurred in 9.6% of the patients. Of 11 patients with thrombophlebitis, 10 were female, and half of the patients had ulcerative colitis or Crohn's disease. Fifty percent of the patients had multiple punctures and catheter malposition. In 3 patients the diagnosis of central venous thrombophlebitis was made within four days, and in 6 patients, within two to four weeks of catheter insertion. The initial symptoms in 81% of the patients were fever, chills, diaphoresis, and severe pain including the arm, axilla, neck, and pectoral areas followed by edema and superficial collateral venous distention. Internal jugular occlusion in 5 patients, extension into the superior vena cava in 5 patients, and right atrium involvement in one patient were noted. Staphylococcus bacteremia was documented in 6 patients with the onset of symptoms. There was one fatality due to pulmonary embolism. Eight patients are alive and well and 2 of them have chronic edema of the arm. Two patients died of causes unrelated to subclavian vein thrombosis or TPN.

**Index terms:** Parenteral feeding • Subclavian vein • Thrombophlebitis

**Cleve Clin Q** 51:159-166, Spring 1984

<sup>1</sup> Department of General Surgery, The Cleveland Clinic Foundation. Submitted for publication July 1983; revision accepted August 1983.

<sup>2</sup> Present address: 4800 San Mateo Lane #331, Albuquerque, NM 87109.

The technique of percutaneous subclavian venous catheterization was reported by Aubaniac<sup>1</sup> in 1952, for the rapid administration of intravenous fluids for patients in shock. In 1962, Wilson,<sup>2</sup> in this country, introduced the same method for the measurement of central venous pres-

**Table 1.** Complication of subclavian vein catheterization for total parenteral nutrition

Author, yr, no. of pub- lished cases, complications, %	Pneumo- thorax	Catheter mal- position	Hemo- thorax	Hydro- thorax	Arterial punc- ture	Catheter sepsis	Hematoma or bleeding	Central venous throm- bosis
Christensen <sup>7</sup>	30	12	5	3	13	4	5	0
1967 (review series)	1.9%	0.8%	0.3%	0.2%	0.8%	0.3%	0.3%	...
1570 cases								
4.6%								
Bernard <sup>8</sup>	6	...	1	...	1	...	1	0
1971	4.1%	...	0.7%	...	0.7%	...	0.7%	...
146 cases								
6.2%								
Ryan <sup>10</sup>	6	...	...	1	1	14	1	?
1974	3%	...	...	0.5%	0.5%	7%	0.5%	...
200 cases								
12%								
Blackett <sup>11</sup>	2	10	...	...	3	...	...	8
1978	2.6%	13.0%	...	...	3.9%	...	...	10.4%
77 cases								
29.9%								
Padberg <sup>12</sup>	5	19	1	1	...	5	5	5
1981	4.8%	18.3%	1.0%	1.0%	...	4.8%	4.8%	4.8%
104 cases								
39.4%								
Present series	33	48	3	3	6	22	...	11
1311 cases	2.5%	3.7%	0.2%	0.2%	0.5%	1.7%	...	0.8%
9.6%								
Total	88	89	10	8	24	53	12	24
3408 cases	2.4%	2.6%	0.3%	0.2%	0.7%	1.6%	0.4%	0.7%
8.9%								

sure in critically ill patients. Nordlund,<sup>3</sup> in 1964, followed by Mogil<sup>4</sup> in 1967, Wilmore and Dudrick,<sup>5</sup> and later Dudrick<sup>6</sup> in 1968, introduced a modification of Wilson's technique as a safe method for central venous access for the routine administration of intravenous hyperalimentation

in patients requiring parenteral nutrition. The subclavian venipuncture technique has gained popularity and widespread acceptance for the administration of parenteral fluids, central venous pressure measurement, cardiac hemodynamic monitoring with the use of pulmonary artery catheters, placement of cannulas for hemodialysis for acute renal failure, placement of temporary and permanent electrodes for pacemakers, ventricular atrial shunts for management of hydrocephalus, and peritoneal right atrial shunts for the treatment of ascites.

Catheterization of the subclavian vein is not without hazard.<sup>7-12</sup> Incidence of the most common complications related to the initial catheter placement varies in the reported series from 4.6% to 39.4% (*Table 1*). Morbidity related to complications is low. Some unusual but serious complications are noted in *Table 2*.

Central venous thrombosis and septic thrombophlebitis are infrequent but potentially fatal complications of subclavian vein catheterization for total parenteral nutrition (TPN). During the last five years we have encountered 11 cases at the Cleveland Clinic. The purpose of this pres-

**Table 2.** Unusual complications of central venous catheterization

Author(s)	Complication
Hurwitz and Posner <sup>13</sup>	Nonhemorrhagic cerebral infarction, 2 cases followed subclavian artery puncture
Lefrak and Noon <sup>14</sup>	Subclavian arteriovenous fistula
Larsen and Lindahl <sup>15</sup>	Laceration of internal mammary artery
Kuiper <sup>16</sup>	Cardiac tamponade
Reilly et al <sup>17</sup>	Delay perforation
Flanagan et al <sup>18</sup>	Air embolism
Obel <sup>19</sup>	Phrenic nerve injury
Smith et al <sup>20</sup>	Brachial plexus injury
Moosman <sup>21</sup>	Laryngeal nerve injury
Moosman <sup>21</sup>	Thoracic duct injury
Klipper et al <sup>22</sup>	Tracheal perforation
Holt et al <sup>23</sup>	Laceration of the apical branch of the pulmonary artery
Brennan et al <sup>24</sup>	Venobronchial fistula

entation is to report the incidence of this complication, review the diagnostic features, clinical manifestations, and possible etiological factors in an effort to prevent, recognize, and adequately treat this complication.

### Material and methods

The records of 1311 consecutive patients undergoing central venous catheterization for TPN from September 1975 through December 1980 were retrospectively reviewed to establish the incidence of complications related to catheter placement and maintenance. Eleven patients who developed subclavian and central venous thrombosis during the time they received TPN were identified and their charts reviewed.

During a period of 64 months a total of 1603 catheters involving 1311 patients were placed and closely monitored by the TPN team in our institution. Resident surgeons with the assistance of the hyperalimentation nurses inserted the 8"-long radiopaque polyethylene catheter using sterile aseptic techniques at the bedside. The right infraclavicular approach was preferred and used in 913 catheterizations (56.9%), the left in 549 (34.2%), the right internal jugular in 94 (5.8%), and the left internal jugular in 47 (2.9%). Free retrograde venous blood flow was always demonstrated before a slow infusion of an isotonic solution was administered to keep the line patent. A portable chest roentgenogram was obtained to confirm the proper placement of the catheter in the superior vena cava and to exclude any possible complications related to the catheter placement before infusion of the hyperalimentation solution. The central venous catheter was used exclusively for the TPN solution. No other fluids, drugs, blood, or blood products were administered through the line. Central venous pressure measurements were also not allowed. The TPN line was carefully attended. The skin was prepared with acetone and povidone iodine solution. Povidone ointment was placed over the insertion site. The occlusive dressing was routinely changed three times a week and the intravenous tubing was changed daily. One thousand units of heparin were added to each litre of TPN solution to reduce catheter thrombogenesis. The indications for TPN in 1311 patients are summarized in *Table 3*.

### Results

The insertion of 1603 catheters in 1311 patients led to complications involving 7.8% of the

**Table 3.** Indication for total parenteral nutrition in 1311 cases

Diseases	Number of patients	Percent
Malignancy	354	27.0
Crohn's	253	19.3
Preoperative/postoperative support	243	18.5
Enterocutaneous fistula	130	9.9
Ulcerative colitis	62	4.7
Vascular disease	52	4.0
Radiation enteritis	42	3.2
Diverticulitis	31	2.4
Renal failure	25	1.9
Cardiovascular disease	19	1.4
Other	100	7.6

catheters and 9.6% of the patients (*Table 1*). Multiple catheterizations were required in 326 patients (24.8%) and single catheterization was done in 985 patients (75.1%). Central venous thrombosis was clinically detected in 11 patients (0.84%). Difficult catheterization with multiple venipunctures occurred in 5 of 11 patients (45%). The clinical findings, diagnostic modalities, treatment, and morbidity and mortality of this group of patients receiving hyperalimentation are summarized in *Table 4*. There were 10 female patients and one male; ages ranged from 11 to 63 years. The most frequent indications for intravenous hyperalimentation were gastrointestinal tract disorders (10 patients); 6 had severe complications or acute mucosal ulcerative colitis or Crohn's disease. Three patients had radiation enteritis, one had extensive ischemic colitis, the other 2 had severe nutritional depletion, the first one suffering from Werner-Morrison syndrome, and the second had lost 15% body weight five weeks after open heart surgery.

The diagnosis was established in 5 patients three to nine days after the initial subclavian catheter insertion. It was characterized by the presence of temperature elevation greater than 102 °F in 9 patients (81%), tachycardia, chills, followed by edema of the involved extremity in 9 patients (81%), edema of the neck in 8 (72%), facial edema in 7 (63%), and ipsilateral, pectoral, and subclavian area edema in 4 patients (36%). Cyanosis of the involved extremity was seen in only 2 patients. Severe pain over the lateral aspect of the involved neck was observed in 9 patients (81%), axillary areas in 8 (72%), pectoral area in 7 (63%), and in the arm in 3 (27%). In 6 patients (54%) the clinical findings of central venous thrombosis appeared 20 to 40 days after the initiation of TPN. In 10 patients (91%) prom-

**Table 4.** Clinical summary

Case, age, sex	Diagnosis, complications	Technique of insertion	Single/multiple punctures	No. of days TPN	Fever	Edema	Pain
1 51 WF	Crohn's disease	Lt subclavian, infraclavicular	Single	3	104 Chills	Arm, neck	Neck, arm
2 32 WF	Radiation enteritis, multiple fistulae	Rt subclavian, infraclavicular	Single	19	101	Facial, lateral neck, rt arm	Severe, neck, axilla
3 55 WF	Ischemic colitis	Rt subclavian, infraclavicular	Single	9	102	Facial, neck, chest, arms	Rt chest wall, neck
4 46 WF	Crohn's disease, rectovaginal fistula	Rt subclavian, lt internal jugular	Multiple, difficult	14	103 Chills	Severe, lt neck, chest wall, arm	Severe, lt neck chest, shoulder
5 63 WF	Active ulcerative colitis	Rt subclavian, infraclavicular	Single	4	101	Rt lateral neck, chest wall, arm	Rt neck, axilla
6 60 WF	Werner-Morrison syndrome	Lt subclavian, infraclavicular	Single	4	99	Lt arm, axilla	Lt axilla
7 32 WF	Ulcerative colitis with pelvic sepsis	Rt subclavian, infraclavicular	Multiple, difficult	42	101	Rt neck, face, arm	Rt neck, axilla, shoulder
8 28 WM	Active Crohn's disease	Lt subclavian, infraclavicular	Multiple	7	102 Chills	Lt neck, chest wall	Severe, lt neck, axilla
9 53 WF	Radiation proctitis, sacral, decubitus	Rt/lt subclavian, infraclavicular	Multiple, difficult	24	102 Chills	Arms	Rt/lt axilla, neck, chest wall
10 54 WF	Cancer, cervix pelvic exenteration	Rt/lt subclavian infraclavicular	Multiple	36	103	Rt neck, chest, arm, face	Rt neck, chest, face, arm
11 11 WF	Postoperative congenital heart disease	Rt subclavian	Single	27	103 Chills	Rt neck, face, arm, chest	Severe, rt face, neck, arm, chest

TPN = total parenteral nutrition, PE = physical examination, - = negative, IV = intravenous, + = positive, SVC = superior vena cava.

inent superficial collateral venous circulation over the deltoid and pectoral areas was detected within 24 to 48 hours, after the fever, edema, and tenderness over the pectoral and axillary area had been noted.

Persistent leukocytosis greater than 15,000/mm<sup>3</sup> with an increase in polymorphonuclear cells was present in 9 patients (81%). Peripheral blood cultures were obtained during the initial febrile episode that preceded the typical physical findings of central venous thrombosis. In 3 patients *Staphylococcus epidermidis* was isolated; in 3 others, *Staphylococcus aureus*. Routine culture of the catheter tip was done in 10 patients. Only 2 had a positive culture; patient 11 had rare *Staphy. aureus*, and peripheral blood cultures on this patient were sterile. The second, case 4, had multiple positive blood cultures for *Staphy. aureus*, which also was isolated from the catheter tip. Eventually, septic thrombophlebitis of the left subcla-

vian, internal jugular, and innominate veins developed in this patient.

Bacteremia was documented in 2 patients before the initiation of TPN. A 63-year-old white woman (case 5) with active ulcerative colitis, heart failure, and a decubitus ulcer, had a *Staphy. aureus* bacteremia, which was treated with oxacillin, intravenously. However, *Staphylococcus* bacteremia was documented at the time of the central venous thrombosis. The second patient, case 3, a 55-year-old white woman with ischemic colitis, had one of two blood cultures positive for *Pseudomonas aeruginosa*, which was thought to be a contaminant.

Venograms were obtained in 9 patients (Figure) between two to eight days after the clinical diagnosis had been established. In all patients 90% to 100% thrombosis of the ipsilateral subclavian vein was demonstrated, with extension into the internal jugular in 7, the innominate, axillary,

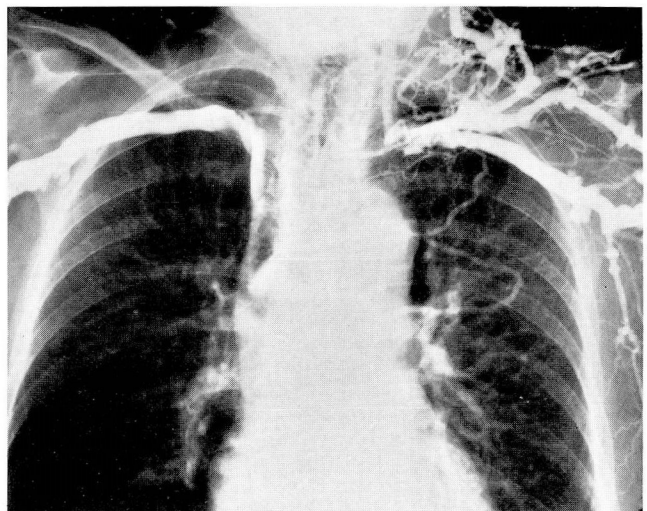


Venograms	Positive blood cultures	WBC count mm <sup>3</sup>	Heparin U/day	Antibiotic	PE	Mortality/morbidity
Thrombosis, lt subclavian, axilla, jugular	4 positive <i>Staphylococcus epidermidis</i>	18,000 86% n	33,000 × 10 days	Oxacillin × 11 days	—	Persistent lt arm edema
Thrombosis, rt axilla, subclavian	2 positive <i>S. epidermidis</i>	15,000 76% n	30,000 × 14 days	Oxacillin, IV 12 gr × 14 days	...	Well
Rt subclavian, internal jugular, innominate	Negative	20,000 94% n	36,000 × 14 days	Cefazolin, IV 4 gr/day	—	Collateral circulation persistent rt arm edema
Lt subclavian, jugular thrombosis, extension into SVC	4 positive <i>Staphylococcus aureus</i>	24,000 95% n	30,000 IV × 14 days	Nafcillin 28 days	+	Died, septic pulmonary and systemic emboli
None	2 positive <i>S. aureus</i>	16,000 91% n	None	Oxacillin 8 gr IV/day × 14 days	—	Died 3 wk later of heart failure
None	Negative	12,000 80% n	"Mini" heparin	None	+	Died suddenly 11 days after exploratory laparotomy
Rt subclavian innominate, internal jugular, extension into SVC	Negative	16,000 80% n	30,000 IV × 2 wk	Cleocin, IV 600 mg × 3/day 10 days	—	Well
Lt subclavian and internal jugular veins	One <i>S. aureus</i>	14,000 78% n	30,000 IV × 2 wk	None	—	Well
Rt/Lt subclavian, extension into SVC	<i>S. epidermidis</i>	9000	40,000 IV × 2 wk	Nafcillin, tobramycin	—	Well
Rt internal jugular, subclavian, innominate	Negative	15,000 80%	30,000 IV × 2 wk	Vancomycin	—	Well
SVC, rt/Lt subclavian, internal jugular, extension into rt atrium	Negative	19,000 90%	24,000 IV × 2 wk	Nafcillin, oxacillin	—	Died of heart failure

and superior vena cava in 4. In an 11-year-old girl (case 11), who underwent a previous modified Fontan procedure for a complex congenital heart disease, a thrombus was found extending into the right atrium that was not present before initiation of hyperalimentation.

The venograms showed a prominent venous collateral pattern in all stages. When the subclavian vein was obstructed, the predominant collateral flow followed the cephalic-transverse, scapular-transverse, cervical-jugular vein route pattern "first rib bypass."<sup>25</sup> When the axillary vein was thrombosed, the venous collateral pattern followed the thoracic-intercostal-internal mammary vein route. Also, prominent and numerous small axillary venous vessels could be seen, bridging the length of the thrombosed axillary vein segment.

When the clinical diagnosis was established and venograms were obtained, systemic hepariniza-



**Figure.** Case 4. Bilateral upper extremity venogram demonstrating extensive left subclavian and internal jugular vein thrombosis with complete occlusion of the innominate vein and extension into the superior vena cava.

tion (500 U/kg/24 hr) was administered in a continuous intravenous drip in 9 of 10 patients for ten to 14 days. Results of daily partial thromboplastin time studies were obtained to control the dose of heparin. Because of a hemothorax, the patient in case 6 was not heparinized. However, this woman was given Mini-Heparin (5000 units subcutaneously twice a day). She died suddenly 11 days after an exploratory laparotomy, possibly as a result of pulmonary embolism. Autopsy was not performed. Continuation of anticoagulation with oral anticoagulants has not been used and although unconventional, has not been associated with any untoward sequelae.

Eight of the 11 patients were treated intravenously with systemic anti-Staphylococci antibiotics for ten to 28 days, until the clinical findings and the blood cultures had become negative and fever had subsided.

One death was directly related to complications of septic thrombophlebitis in a 46-year-old woman (case 4) with Crohn's disease and rectovaginal fistula. Septic pulmonary emboli with multiple pulmonary abscesses and gangrene of the right leg developed and she subsequently died of septic shock. Death of the other 2 patients was not related to central venous thrombosis. The first one, a 63-year-old woman (case 5), died of chronic congestive failure two weeks after the central venous thrombosis had subsided. Autopsy was not done. The second patient, an 11-year-old white girl who had had a modified Fontan procedure for congenital heart disease, died three weeks after the acute episode of central venous thrombosis. Autopsy showed that the thrombus extended into the right atrium. Seven patients were discharged from the hospital, 5 entirely asymptomatic and the other 2 with mild to moderate edema of the involved extremity.

## Discussion

Catheterization of the subclavian vein is a widely accepted technique for the administration of TPN. The incidence of complications related to catheter placement have been described (*Table 1*). However, thrombosis and septic thrombophlebitis of the subclavian vein and its tributary branches are not frequently clinically recognized or reported<sup>7, 26-29</sup> and represent late potentially lethal complication.<sup>30-32</sup> In 1971 Burri and Gasser,<sup>29</sup> in a collective review based on 7225 subclavian catheterizations, noted that clinical signs of central venous thrombosis were reported in 0.7%

of cases. In their own prospective study of 1098 catheterizations, they noted a 1.5% incidence. Recently, 34 cases of clinically documented central venous thrombosis in patients receiving intravenous hyperalimentation have been reported,<sup>10, 26, 32-34</sup> representing a 0.2% to 2.3% incidence. Other authors<sup>11, 12</sup> reported a higher incidence in their series that varied from 4.8% to 10.4% in 104 and 77 patients, respectively. Autopsy incidence of central vein thrombosis in patients who received total parenteral nutrition is even greater, occurring in 6.5% to 21% of patients.<sup>3, 10, 12, 35</sup> Hoshal<sup>30</sup> and Nordlund,<sup>3</sup> also in postmortem series demonstrated the formation of fibrin sleeves around the catheter in 35% and 100% of 31 and 46 patients, respectively, who had central venous catheters. Axelsson<sup>36</sup> in a retrospective phlebographic study of 27 patients receiving TPN, demonstrated that 7 patients with central vein thrombosis were completely asymptomatic. In a similar series, Braun<sup>35</sup> and Teske<sup>37</sup> found a 35% venographic incidence of thrombus formation after seven days of catheter placement. Our own experience with patients having venograms before home parenteral nutrition catheter placement also shows a 20% incidence of subclavian vein thrombosis that is not clinically apparent.

Many factors have been reported to be related to the pathogenesis of catheter-induced central venous thrombosis. Most are associated with endothelial and intimal injury during catheter insertion, particularly when difficult or multiple venipunctures are required, as noted in 5 of our 11 patients. Catheter malposition, reinsertion, manipulation, and a break in sterile technique<sup>9</sup> may play an important role in thrombogenesis. The presence of a foreign body within the vessel lumen induces platelet aggregation<sup>8, 26, 30, 38</sup> and formation of nidus of microthrombus, both at the point of catheter entry, and the level where the catheter tip touches the vessel.<sup>20</sup> The administration of a hypertonic solution in a large caliber vessel has been proved not to be a problem.<sup>5-7, 26, 39</sup> Sepsis, hypotension, dehydration, and congestive heart failure leading to venous collapse or stasis had also been incriminated.<sup>26, 30</sup> Focal and systemic infectious processes have also been implicated as a cause of central venous thrombosis, particularly in burn patients.<sup>40</sup> In 55% of our patients, 6 of 11, Staphylococcus bacteremia was documented during the initial 24 to 48 hours that preceded the typical physical

finding of central venous thrombosis. A consistent etiologic factor is the presence of a stiff polyethylene catheter with thrombogenic properties as demonstrated by Hoshal et al<sup>30</sup> and Motin et al<sup>38</sup> in the first 24 hours after catheter insertion. Welch et al<sup>41</sup> and Tanzawa et al,<sup>42</sup> in experimental and clinical studies, suggested using heparin-coated or silicone catheters to reduce the incidence of this potential complication.

Subclavian vein thrombosis after central catheterization could pass clinically unrecognized as demonstrated in phlebographic and postmortem studies.<sup>9,10,36</sup> Once the clinical diagnosis is established and the central catheter is removed, systemic heparinization should be initiated with or without a loading dose, which provides an immediate antithrombotic effect,<sup>33</sup> and should be followed by a continuous intravenous administration for ten to 14 days. This technique prevents further proximal propagation of the thrombus, occlusion of the potential collateral circulation, and most importantly, minimizes the risk of pulmonary embolism, which has been estimated to be as high as 12% by Adams et al<sup>44</sup> in patients with primary deep vein thrombosis of the upper extremities.<sup>24</sup> Recently, there have been several reports of pulmonary embolism in patients with central vein thrombosis after subclavian catheterization.<sup>9,11,31,45</sup> Some cases have been fatal.<sup>10,26,35,40,46</sup> Phlebographic studies after central venous vein thrombosis have demonstrated that the rate of recanalization in the upper extremities is extremely low.<sup>47</sup> Some authors have reported a high incidence of long-term sequelae.<sup>24,25,47</sup> However, only 2 of our 7 long-term survival patients had mild persistent edema of the involved extremity, and one had prominent superficial collateral circulation. Because of the potential danger of septic and suppurative thrombophlebitis, systemic intravenous antibiotic therapy should be administered if sepsis is suspected, and it should be continued if bacteremia or catheter sepsis is documented. Antistaphylococcal antibiotics should be given until culture and sensitivity results are available and antibiotics should then be chosen more specifically.

Suppurative thrombophlebitis of large central veins is uncommon,<sup>40,48,49</sup> complicating central venous catheterization. However, if left untreated by aggressive combined intravenous antibiotic therapy and either surgical ligation or excision, the mortality and morbidity is extremely high.<sup>40,50-55</sup> Recently, streptokinase has

been clinically used successfully in the treatment of central venous thrombosis, particularly in cases in which heparin was not effective.<sup>28,56,57</sup>

Subclavian vein catheterization for administration of TPN can be complicated by central venous thrombosis. Prompt recognition and effective therapy can minimize potentially lethal morbidity and reduce the incidence of serious sequelae. Edema, pain, and venous distention in areas close to the insertion or course of a subclavian catheter often associated with sepsis should help to establish the diagnosis. Subclavian venography will confirm the diagnosis. Recommended therapy is catheter removal, heparinization, and antibiotics. Thrombolytic agents may also be of value.

## References

1. Aubaniac R. L'injection intraveineuse sous-claviculaire; avantages et technique. *Press Med* 1952; **60**:1456.
2. Wilson JN, Grow JB, Demong CV, Prevedel AE, Owens JC. Central venous pressure in optimal blood volume maintenance. *Arch Surg* 1962; **85**:563-578.
3. Nordlund S, Thorén L. Catheter in the superior vena cava for parenteral feeding. *Acta Chir Scand* 1964; **127**:39-45.
4. Mogil RA, DeLaurentis DA, Rosemond GP. The infraclavicular venipuncture; value in various clinical situations including central venous pressure monitoring. *Arch Surg* 1967; **95**:320-324.
5. Wilmore DW, Dudrick SJ. Safe long-term venous catheterization. *Arch Surg* 1969; **98**:256-258.
6. Dudrick SJ, Wilmore DW. Long-term parenteral feeding. *Hosp Pract* 1968; **3**(no. 10):65-78.
7. Christensen KH, Nerström B, Baden H. Complications of percutaneous catheterization of the subclavian vein in 129 cases. *Acta Chir Scand* 1967; **133**:615-620.
8. Bernard RW, Stahl WM. Subclavian vein catheterizations; a prospective study. I. Non-infectious complications. *Ann Surg* 1971; **173**:184-190.
9. Bernard RW, Stahl WM, Chase RM Jr. Subclavian vein catheterizations; a prospective study. II. Infectious complications. *Ann Surg* 1971; **173**:191-200.
10. Ryan JA Jr, Abel RM, Abbott WM, et al. Catheter complications in total parenteral nutrition; a prospective study of 200 consecutive patients. *N Engl J Med* 1974; **290**:757-761.
11. Blackett RL, Bakran A, Bradley JH, Halsall A, Hill GL, McMahon MJ. A prospective study of subclavian vein catheters used exclusively for the purpose of intravenous feeding. *Br J Surg* 1978; **65**:393-395.
12. Padberg FT, Ruggiero J, Blackburn GL, Bistrian BR. Central venous catheterization for parenteral nutrition. *Ann Surg* 1981; **193**:264-270.
13. Hurwitz BJ, Posner JB. Cerebral infarction complicating subclavian vein catheterization. *Ann Neurol* 1977; **1**:253-264.
14. Lefrak EA, Noon GP. Management of arterial injury secondary to attempted subclavian vein catheterization. *Ann Thorac Surg* 1972; **14**:294-298.
15. Larsen HW, Lindahl F. Lesion of the internal mammary artery caused by infraclavicular percutaneous catheterization of the subclavian vein; report of a case. *Acta Chir Scand* 1973; **139**:571-572.
16. Kuiper DH. Cardiac tamponade and death in a patient receiving total parenteral nutrition. *JAMA* 1974; **230**:877.
17. Reilly JJ, Cosimi B, Russell PS. Delayed perforation of the



- innominate vein during hyperalimentation. *Arch Surg* 1977; **112**:96.
18. Flanagan JP, Gradisar LA, Gross RJ, Kelly TR. Air embolus; a lethal complication of subclavian venipuncture. *N Engl J Med* 1969; **281**:488-489.
19. Obel IWP. Transient phrenic-nerve paralysis following subclavian venipuncture. *Anesthesiology* 1970; **33**:369-370.
20. Smith BE, Modell JH, Gaub ML, Moya F. Complications of subclavian vein catheterization. *Arch Surg* 1965; **90**:228-229.
21. Moosman DA. The anatomy of infraclavicular subclavian vein catheterization and its complications. *Surg Gynecol Obstet* 1973; **136**:71-74.
22. Klipper WS, Waite HD, Tomlinson CO. Endotracheal cuff perforation complicating subclavian venipuncture. *JAMA* 1974; **288**:693.
23. Holt S, Kirkham N, Myerscough E. Haemothorax after subclavian vein cannulation. *Thorax* 1977; **32**:101-103.
24. Brennan MF, Sugarbaker PH, Moore FD. Venobronchial fistula; a rare complication of central venous catheterization for parenteral hyperalimentation. *Arch Surg* 1973; **106**:871-872.
25. Swinton NW Jr, Edgett JW Jr, Hall RJ. Primary subclavian-axillary vein thrombosis. *Circulation* 1968; **38**:737-744.
26. McDonough JJ, Altemeier WA. Subclavian venous thrombosis secondary to indwelling catheters. *Surg Gynecol Obstet* 1971; **133**:397-400.
27. Stewart GR. Home parenteral nutrition for chronic short bowel syndrome. *Med J Aust* 1979; **2**:317-319.
28. Havill JH. Central venous thrombosis following central venous catheterization and parenteral nutrition; case report. *NZ Med J* 1975; **81**:420-422.
29. Burri C, Gasser D. Der Vena Cava-Katheter. [In: Frey R, Hügin W, Mayrhofer O, eds. *Anaesthesiologie und Wiederbelebung* 54 [Anaesthesiology and Resuscitation 54]. Berlin, New York, Springer-Verlag 1971, pp 17-22, 77-83, 93-99.
30. Hoshal VL Jr, Ause RG, Hoskins PA. Fibrin sleeve formation on indwelling subclavian central venous catheters. *Arch Surg* 1971; **102**:353-458.
31. Campbell BC, Chandler JG, Tegtmeyer CJ, Bernstein EF. Axillary, subclavian, and brachiocephalic vein obstruction. *Surgery* 1977; **82**:816-826.
32. Linder MM. Vena subclavia-Katheterisierung. Thrombose der Vena subclavia und tödliche Lungenarterienembolie. [Thrombosis of the subclavian vein fatal embolism of pulmonary artery.] *Fortschr Med* 1973; **91**:659-661.
33. Martin EC, Koser M, Gordon DH. Venography in axillary-subclavian vein thrombosis. *Cardiovasc Radiol* 1979; **2**:261-266.
34. Galley RL. Thrombosis after parenteral feeding via a subclavian catheter. *Med J Aust* 1979; **2**:364.
35. Braun U, Fassolt A, Teske HJ. Phlebographische Untersuchungen zur Frage der Fremdkörperbedingten Thrombose beim infraclaviculären Subclaviakatheter. *Anaesthetist* 1970; **19**:432-437.
36. Axelsson CK, Efsen F. Phlebography in long-term catheterization of the subclavian vein; a retrospective study in patients with severe gastrointestinal disorders. *Scand J Gastroenterol* 1978; **13**:933-938.
37. Teske HJ, Fassolt A, Braun U. Ergebnisse phlebographischer Kontrolluntersuchungen beim infraclaviculär eingeführten Vena-cava-Katheter. *Fortschr Röntgenstr* 1970; **112**:189-195.
38. Motin J, Fischer G, Evreux J. Intérêt de la voie sous-clavière en réanimation prolongée (à propos de 154 cas). *Lyon Med* 1964; **212**:583-593.
39. Defalque RJ. Subclavian venipuncture; a review. *Anesth Analg* 1968; **47**:677-682.
40. Warden GD, Wilmore DW, Pruitt BA Jr. Central venous thrombosis; a hazard of medical progress. *J Trauma* 1973; **13**:620-626.
41. Welch GW, McKeel DW Jr, Silverstein P, Walker HL. The role of catheter composition in the development of thrombophlebitis. *Surg Gynecol Obstet* 1971; **138**:421-424.
42. Tanzawa H, Mori Y, Harumiya N, et al. Preparation and evaluation of a new athrombogenic heparinized hydrophilic polymer for use in cardiovascular system. *Trans Am Soc Artif Intern Organs* 1973; **19**:188-194.
43. Basu D, Gallus A, Hirsh J, Cade J. A prospective study of the value of monitoring heparin treatment with activated partial thromboplastin time. *N Engl J Med* 1972; **287**:324.
44. Adams JT, McEvoy RK, DeWeese JA. Primary deep venous thrombosis of upper extremity. *Arch Surg* 1965; **91**:29-42.
45. Ladefoged K, Jarnum S. Long-term parenteral nutrition. *Br Med J* 1978; **2**:262-266.
46. Ahmed N, Payne RF. Thrombosis after central venous cannulation. *Med J Aust* 1976; **1**:217-220.
47. Tilney NL, Griffiths HJG, Edwards EA. Natural history of major venous thrombosis of upper extremity. *Arch Surg* 1970; **101**:792-796.
48. Munster AW. Septic thrombophlebitis; a surgical disorder. *JAMA* 1974; **230**:1010-1011.
49. Weinberg G, Pasternak BM. Upper-extremity suppurative thrombophlebitis and septic pulmonary emboli. *JAMA* 1978; **240**:1519.
50. Winn RE, Tuttle KL, Gilbert DN. Surgical approach to extensive suppurative thrombophlebitis of the central veins of the chest. *J Thorac Cardiovasc Surg* 1981; **81**:564-568.
51. Klein HR, Segal F. Venous ligation for septic pulmonary emboli following suppurative pelvic thrombophlebitis. *S Afr Med J* 1966; **40**:1064-1068.
52. Baker CC, Petersen SR, Sheldon GF. Septic phlebitis; a neglected disease. *Am J Surg* 1979; **138**:97-103.
53. O'Neill JA Jr, Pruitt BA Jr, Foley FD, Moncrief JA. Suppurative thrombophlebitis; a lethal complication of intravenous therapy. *J Trauma* 1968; **8**:256-267.
54. Neuhoof H, Seley GP. Acute suppurative phlebitis complicated by septicemia. *Surgery* 1947; **21**:831-842.
55. Stein JM, Pruitt BA Jr. Suppurative thrombophlebitis; a lethal iatrogenic disease. *N Engl J Med* 1970; **282**:1452-1455.
56. Rubenstein M, Creger WP. Successful streptokinase therapy for catheter-induced subclavian vein thrombosis. *Arch Intern Med* 1980; **140**:1370-1371.
57. Dotter CT, Rösch J, Seaman AJ, Dennis D, Massey WH. Streptokinase treatment of thromboembolic disease. *Radiol* 1972; **102**:283-290.