

Cardiac rhabdomyosarcoma: case report with review of clinical and pathologic features¹

Richard C. Becker, M.D.
Robert E. Hobbs, M.D.
Norman B. Ratliff, M.D.

A patient with a cardiac rhabdomyosarcoma illustrates the clinical and pathologic features of this extremely rare malignancy. Presenting manifestations are variable and nonspecific. The two-dimensional echocardiogram is the best noninvasive means of diagnosing cardiac tumors. The nuclear magnetic resonance scan accurately demonstrated the presence and location of the intracardiac mass lesion. Pathologically, rhabdomyosarcomas require light and electron microscopic examination to establish the tumor type. Surgical resection, radiation therapy, and chemotherapy do not appear to alter the natural history, and death usually occurs within one year of diagnosis.

Index terms: Heart neoplasms • Rhabdomyosarcoma • Sarcoma

Cleve Clin Q 51: 83–88, Spring 1984

The diagnosis of cardiac tumors is one of the most difficult and challenging diagnoses in medicine. The presenting signs and symptoms are variable and tend to mimic numerous disease states. Despite the low overall incidence, cardiac tumors are diagnosed more frequently during life as a result of increasing awareness by physicians and more accurate diagnostic tests. The presenting manifestations, useful diagnostic studies, pathologic description, and surgical approach are illustrated in the following case report.

Case report

A 63-year-old woman was referred because of exertional dyspnea, orthopnea, paroxysmal nocturnal dyspnea, fatigue,

cough, and a 9-kg (20-pound) weight loss over six months. Physical examination revealed a thin, pale, anxious woman whose blood pressure was 126/84 mm Hg, pulse 104 beats/min, respiration 16 beats/min, temperature 37.3°C. Results of examination of the head, eyes, ears, nose, and throat were negative. There was no jugular venous distension. The carotid pulses were 4+ with normal upstroke. Rales were heard at both lung bases. The point of maximal impulse (PMI) was diffuse and palpable 1.5 cm lateral to the mid-clavicular line. A left parasternal lift and an apical systolic thrill were palpable. The first heart sound was accentuated, and the second heart sound was normal. A grade IV/VI pansystolic murmur was heard at the apex and radiated to the axilla. A diastolic rumble was present at the apex. The remainder of the physical examination was unremarkable.

The electrocardiogram demonstrated left ventricular hypertrophy and left atrial enlargement. Chest roentgenogram revealed left ventricular enlargement with increased pulmonary vascularity. Two-dimensional echocardiography demonstrated an irregular sessile left atrial mass attached to the atrial septum and the anterior mitral valve leaflet (*Fig. 1*). Cardiac catheterization documented severe mitral valve obstruction and regurgitation (*Fig. 2*). Opacification of the left atrium outlined an atrial mass on the inferior portion of the septum and anterior mitral valve leaflet. The right ventricular outflow tract was irregular, but unobstructed. Nuclear magnetic resonance scan documented similar findings (*Fig. 3*).

Surgery was advised to establish the diagnosis and to resect the tumor if possible. At the time of operation a firm, grayish yellow mass was found within the left atrium and appeared to infiltrate the septum and mitral valve. The tumor was removed, along with a large portion of the atrial septum and mitral valve. The septum was repaired with a Dacron patch and the mitral valve replaced with a porcine xenograft.

Pathologic examination revealed a diffuse, firm mass measuring 8.5 × 5.3 × 2.5 cm extensively infiltrating the mitral valve and interatrial septum (*Fig. 4*). The tumor was composed primarily of pleomorphic spindle cells and lesser numbers of polygonal cells with eosinophilic cytoplasm located in an abundant well-vascularized myxoid stroma (*Fig.*

¹ Departments of Cardiology (R.C.B., R.E.H.) and Pathology (N.B.R.), The Cleveland Clinic Foundation. Submitted for publication Aug 1983; revision accepted Oct 1983.

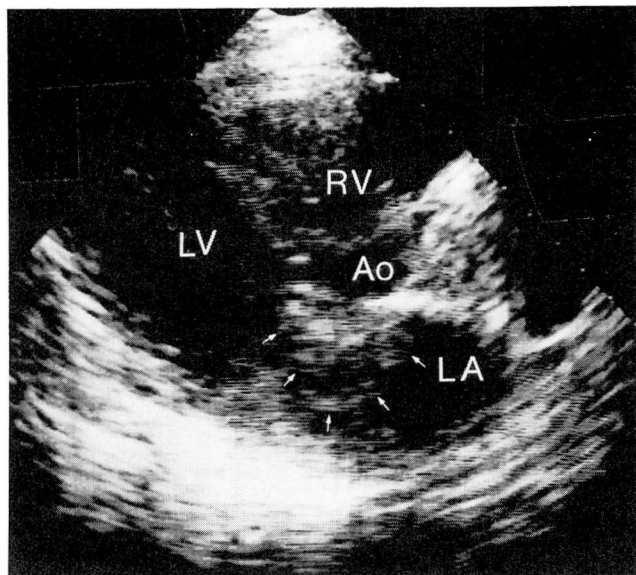


Fig. 1. Two-dimensional echocardiogram, long axis parasternal view. A mass (outlined by arrows) arises from the lower portion of the atrial septum and extends into the left atrium and onto the anterior mitral leaflet.

5). As many as five mitoses per high power field were observed in selected areas. Immunoperoxidase stains for myoglobin, alpha-1-antitrypsin, factor VIII antigen, Ulex blood group antigens, and muramidase were negative. Examination of multiple one-micron plastic embedded sections revealed occasional strap cells with faint cross-striations. Electron microscopy demonstrated that the cross-striations were poorly developed sarcomeres, establishing the diagnosis of rhabdomyosarcoma (Fig. 6).

The aortic valve was removed 14 days later because of severe aortic regurgitation and was found to be infiltrated by the tumor. The patient's postoperative course was complicated by congestive heart failure, complete heart block, right hemispheric stroke, and respiratory insufficiency. She died two and a half months after surgery.

Discussion

Approximately 25% of all primary cardiac tumors are malignant, and virtually all malignant cardiac tumors are sarcomas. Earlier descriptive diagnoses such as fibrosarcoma, spindle cell sarcoma, and giant cell sarcoma have largely been abandoned and replaced by a histogenetic classification.¹ Cardiac sarcomas are now grouped into five distinct categories and a miscellaneous group. Sarcomas of vascular origin are the most common. Sarcomas of muscle cell origin (rhabdomyosarcomas, leiomyosarcomas) are second in frequency and often require electron microscopy to identify the smooth or striated muscle origin. The remaining groups are extremely rare.

Rhabdomyosarcomas may arise in any cardiac

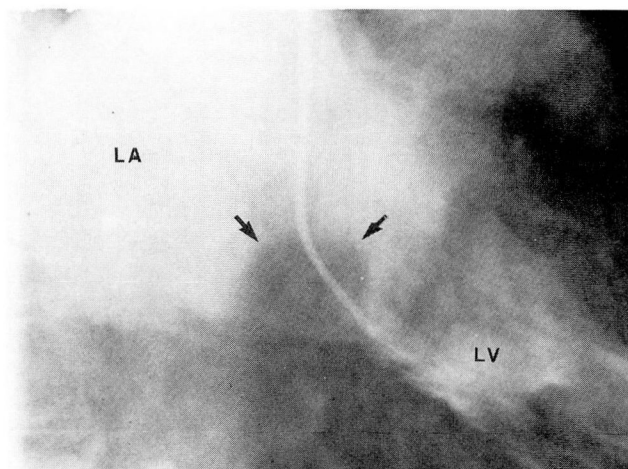


Fig. 2. Left ventriculogram right anterior-oblique (RAO) projection. Severe mitral regurgitation outlines the mass (arrows) in the lower left atrium.

chamber and occur with equal frequency in the left and right sides of the heart.² Pericardial involvement is found in 50% of patients at autopsy and usually results from direct tumor extension.³ Rhabdomyosarcomas are invasive and extend from the primary site to other cardiac chambers as well as heart valves. Extension to the mediastinum or pleura is not uncommon, and approximately 30% metastasize early in their course. The most frequent metastatic sites include lung, thoracic lymph nodes, liver, kidney, adrenals, pancreas, and bone.⁴

Rhabdomyosarcomas have occurred in individuals ranging in age from three months to 80 years, but the majority of the tumors occur during the third to fifth decades. Most patients present with nonspecific complaints such as fever, weight loss, anorexia, and fatigue.⁵ These manifestations may be the result of autoimmune or paraneoplastic phenomena, vasoactive substances, or tumor necrosis. Signs and symptoms attributable to myocardial, valvular, and pericardial disease are common.⁶ Rapidly progressive congestive heart failure of recent onset, which remains refractory to treatment, is characteristic of a cardiac tumor.^{7,8} Other cardiac manifestations include conduction defects, cardiac arrhythmias, chest pain, valvular dysfunction, syncope, pericardial effusion, and myocardial infarction.⁹⁻¹¹ Embolic phenomena, which occur less commonly than in atrial myxomas, may mimic vasculitis or bacterial endocarditis.¹² The brain is the most frequent embolic site.¹³

Laboratory findings may include anemia, ery-

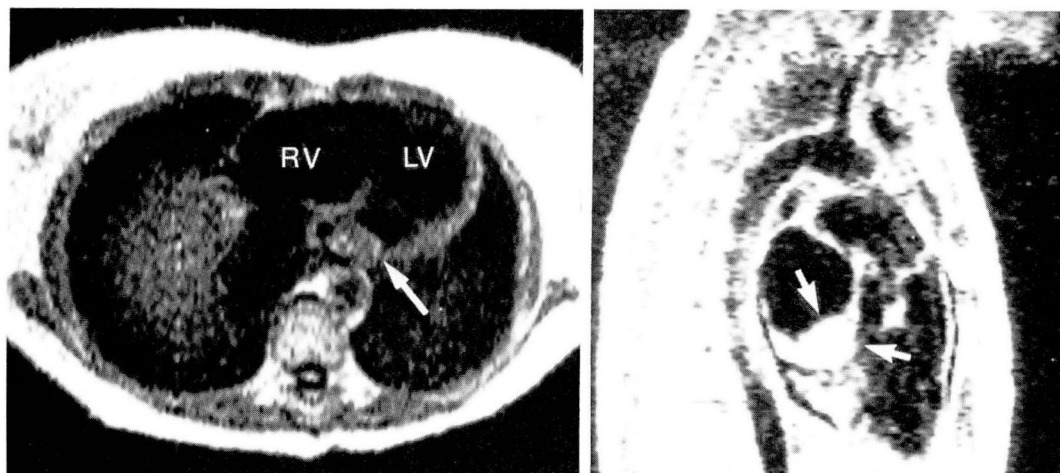


Fig. 3. Cross-sectional (A) and left parasagittal (B) nuclear magnetic resonance (NMR) scans. The mass appears to be localized to the lower portion of the left atrium (arrows).

throcytosis, thrombocytopenia, thrombocytosis, leukocytosis, elevated sedimentation rate, and elevated immunoglobulins.¹⁴

The electrocardiogram commonly shows non-specific ST-T changes, but low voltage or bundle branch block may also occur.

The chest roentgenogram frequently reveals generalized cardiac enlargement, although irregularity of the heart borders and a distorted cardiac silhouette may be observed. Additional roentgenographic changes include mediastinal widening, enlarged hilar lymph nodes, pulmo-

nary venous and arterial abnormalities, and various parenchymal densities.^{15,16}

Echocardiographic, CT scanning, and nuclear magnetic resonance (NMR) imaging provide important information about the size, shape, and extent of the tumor. Many malignant tumors are intramural and result in distortion of the septum or free wall. Occasionally, a tumor infiltrates a cardiac valve, making it readily detectable by two-dimensional echocardiography.¹⁷

The major angiographic findings consist of intracavitary filling defects, pericardial effusion,

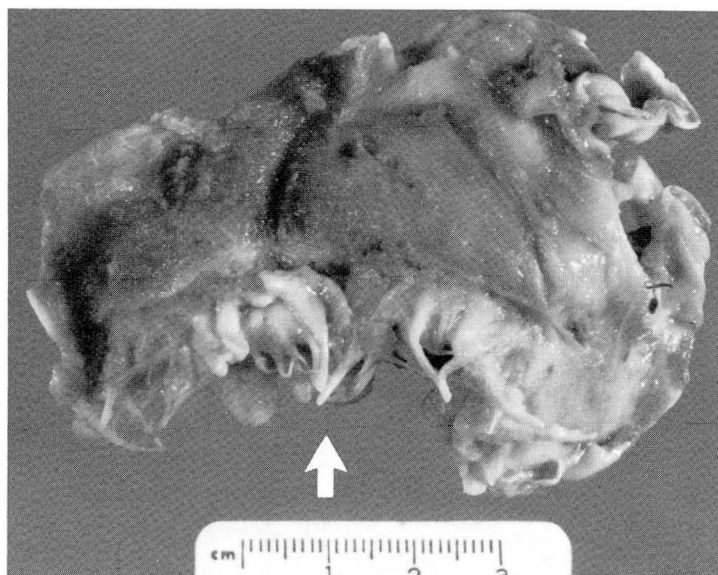


Fig. 4. Gross tumor specimen. Note tumor infiltration of the mitral valve (arrow).

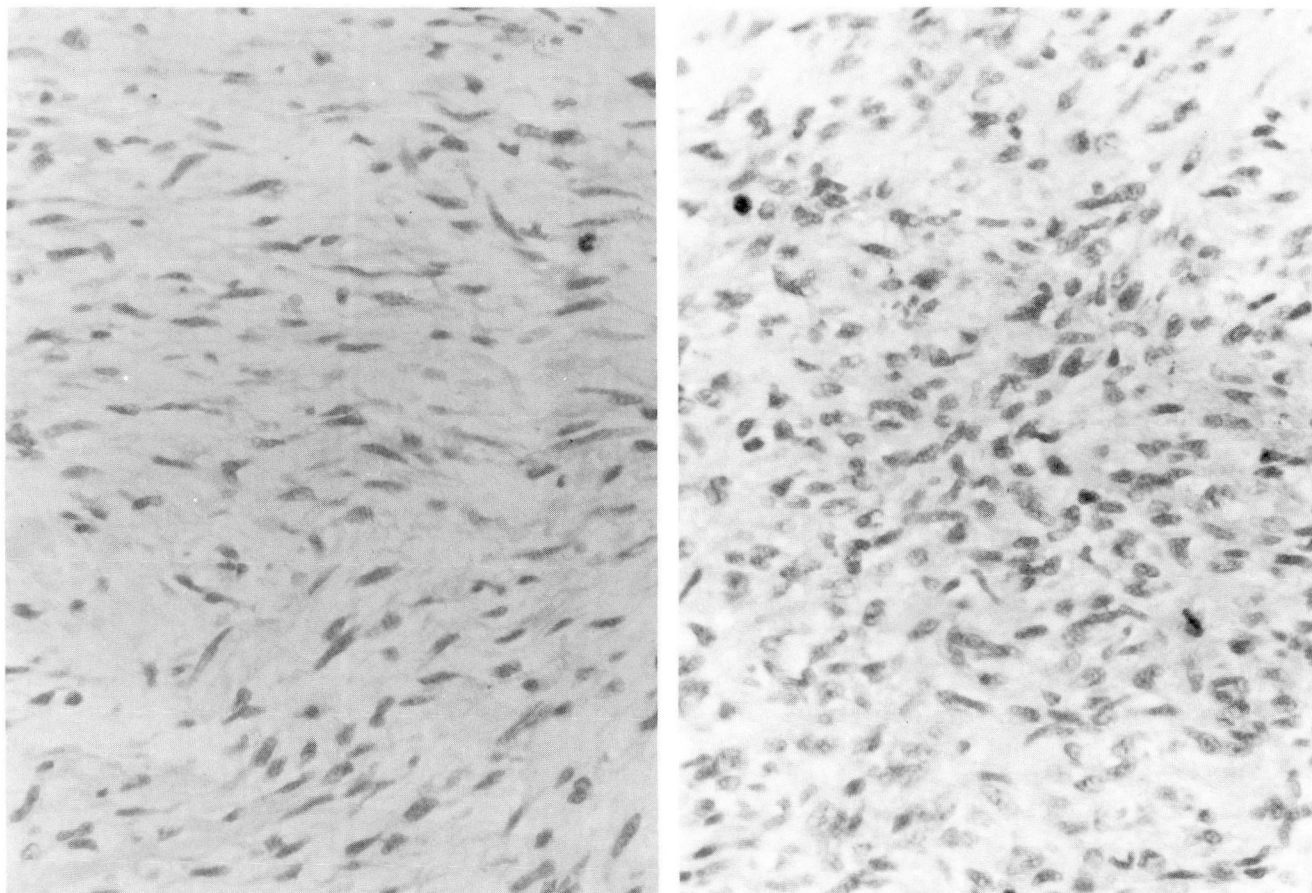


Fig. 5. Light micrograph illustrating two microscopic fields from the rhabdomyosarcoma. Note the spindle cell pattern (left) and the polygonal cell pattern (right) (hematoxylin-eosin, $\times 250$).

displacement of the cardiac chambers, deformity of the septal or muscular walls, and segmental changes in wall motion.¹⁸ The presence of mobile or fixed intracavitary filling defects usually indicates a benign tumor, while deformity of the septum or myocardial wall suggests malignancy.

To determine the best surgical approach, accurate preoperative diagnosis is mandatory. The presence of hemorrhagic pericardial effusion, mediastinal invasion, and vascular infiltration at surgery supports the diagnosis of malignancy. During surgical exploration, minimal tumor manipulation is desirable to prevent mechanical seeding.¹⁹ A surgical biopsy and frozen section are usually necessary to identify the tumor type. The majority of malignant tumors require additional pathologic study.

Pathologically, rhabdomyosarcomas are diagnosed microscopically by the presence of rhabdomyoblasts.²⁰ Tumor nuclei typically exhibit variations in shape, size, and chromaticity. Giant

nuclei with abnormal mitoses and vesiculations may be seen. Additionally, spindle cell foci, myxoid areas, necrosis, and hemorrhage are observed.²¹ Cross striations occasionally are visible with light microscopy. Electron microscopy reveals thick and thin filaments and Z bands, often arranged in a haphazard pattern.²²

Death results from a combination of widespread infiltration, obstructive symptoms, and distant metastases. Most patients die within one year of diagnosis.²³ Surgical removal of malignant cardiac tumors in general is not an effective treatment and usually does not improve survival. In addition, various combinations of radiation therapy and chemotherapy have not improved longevity in the majority of patients with malignant cardiac tumors.²⁴

Summary

This case of a cardiac rhabdomyosarcoma illustrates many features of this rare malignancy.

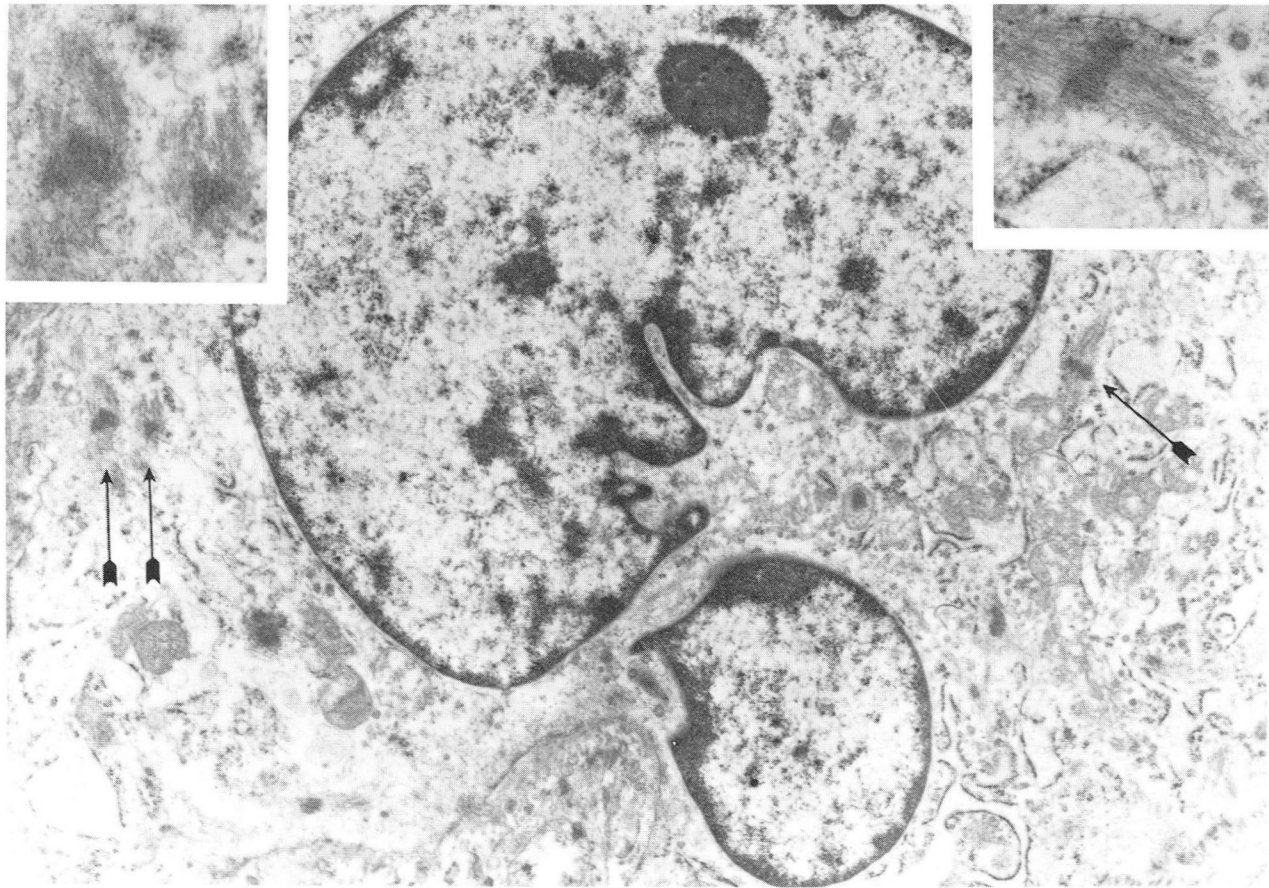


Fig. 6. Electron micrographs illustrating a single rhabdomyosarcoma cell. Rough endoplasmic reticulum, mitochondria, and small membranous profiles are evident in the cytoplasm. The nucleus is deeply indented and appears to be multinucleate, but this is probably the result of sectioning through a single pleomorphic nucleus. The arrows indicate three sarcomeres in the cytoplasm, which are also illustrated at higher magnification in the inserts. Each sarcomere is composed of a single Z line with attached thick and thin filaments ($\times 9,300$; inserts $\times 26,900$).

Presenting manifestations are variable and mimic a variety of disease states. Suspicion is aroused when a patient presents with systemic, embolic, and cardiac manifestations without obvious cause. The two-dimensional echocardiogram is presently the most useful noninvasive tool for establishing the diagnosis. However, the NMR scan appears to be a useful adjunct in visualizing distortions of normal cardiac anatomy. Most patients undergo surgery, since many cardiac tumors are benign, resectable, and curable. Unfortunately, surgical resection of cardiac malignancies has not improved overall prognosis, and despite additional radiation therapy and chemotherapy, life expectancy is usually less than one year from the time of diagnosis.

References

1. Fine G. Primary tumors of the heart. [In] Fenoglio CM, Wolfe M, eds. *Progress in Surgical Pathology*, Vol III. New York, Masson, 1981, pp 37-64.
2. Matloff JM, Bass H, Dalen JE. Rhabdomyosarcoma of the left atrium: physiologic responses to surgical therapy. *J Thorac Cardiovasc Surg* 1971; **61**:451-455.
3. Bemis EL, Pemberton AH, Lurie A. Rhabdomyosarcoma of the heart. *Cancer* 1972; **29**:924-929.
4. Pritchard RW. Tumors of the heart: review of the subject and report of one hundred and fifty cases. *Arch Pathol* 1951; **51**:98-128.
5. O'Reilly MV, McDonald RT, Fornasier VL. Clinical presentation of a myocardial rhabdomyosarcoma. *Br Heart J* 1975; **37**:672-675.
6. Chaudron JMS, Saint-Remy JM, Schmitz A, Lebacqz EG. Right atrium rhabdomyosarcoma. *Acta Cardiol* 1977; **32**:75-81.
7. Firmin R, Lowes A, Hickson B. A case of rhabdomyosarcoma of the right ventricle. *Br Heart J* 1978; **40**:1426-1428.
8. Thiene G, Miraglia G, Menghetti L, Nava A, Rossi L. Multiple lesions in the conduction system in a case of cardiac rhabdomyosarcoma with complex arrhythmias: an anatomic and clinical study. *Chest* 1976; **70**:378-381.
9. Isner JM, Falcone MW, Virmani R, Roberts WC. Cardiac sarcoma causing "ASH" and simulating coronary heart disease. *Am J Med* 1979; **66**:1025-1030.
10. Kroopf SS, Peterson CA. Anaplastic myxoma of the left atrium. *Arch Intern Med* 1957; **100**:819-824.

11. Franciosa JA, Lawrinson W. Coronary artery occlusion due to neoplasm: a rare cause of acute myocardial infarction. *Arch Intern Med* 1971; **128**:797-801.
12. Leonhardt ETG, Kullenber KPG. Bilateral atrial myxomas with multiple arterial aneurysms—a syndrome mimicking polyarteritis nodosa. *Am J Med* 1977; **62**:792-794.
13. Yufe R, Karpati G, Carpenter S. Cardiac myxoma: a diagnostic challenge for the neurologist. *Neurology* 1976; **26**:1060-1065.
14. Peters MN, Hall RJ, Colley DA, Leachman RD, Garcia E. The clinical syndrome of atrial myxoma. *JAMA* 1974; **230**:695-701.
15. Abrams HL, Adams DF, Grant HA. The radiology of tumors of the heart. *Radiol Clin North Am* 1971; 299-326.
16. Steiner RE. Radiologic aspects of cardiac tumors. *Am J Cardiol* 1968; **21**:344-355.
17. Salcedo EE, Adams KV, Lever HM, Gill CC, Lombardo H. Echocardiographic findings in 25 patients with left atrial myxoma. *J Am Coll Cardiol* 1982; **1**:1162-1166.
18. Steinberg I, Miscall L, Redo SF, Goldberg HP. Angiocardiography in diagnosis of cardiac tumors. *AJR* 1964; **91**:364-376.
19. Kabbani SS, Cooley DA. Atrial myxoma: surgical considerations. *J Thorac Cardiovasc Surg* 1973; **65**:731-737.
20. Gough JC, Connolly CE, Kennedy JD. Primary sarcoma of the heart: a light and electron microscopic study of two cases. *J Clin Pathol* 1979; **32**:601-607.
21. Orsmond GS, Knight L, Dehner LP, Nicoloff DM, Nesbitt M, Bessinger FB. Alveolar rhabdomyosarcoma involving the heart: an echocardiographic, angiographic, and pathologic study. *Circulation* 1976; **54**:837-842.
22. Morales AR, Fine G, Horn RC. Rhabdomyosarcoma: an ultrastructural appraisal. *Path Ann* 1972; **7**:81-106.
23. McAllister HA. Primary tumors and cysts of the heart and pericardium. *Curr Probl Cardiol* 1979; **4**:(no. 2)8-51.
24. Hollingsworth JH, Sturgill BC. Treatment of primary angiosarcoma of the heart. *Am Heart J* 1969; **78**:254-258.