

Endourologic management of renal transplant complications¹

Stevan B. Stroom, M.D.

Technical complications requiring reoperation following renal transplantation continue to be significant factors contributing to graft loss and subsequent death. Furthermore, repeated surgical procedures are poorly tolerated in these immunosuppressed and often azotemic patients. In the past few years, nonoperative endourologic procedures have been employed to temporize or even definitively manage many high-risk urologic patients with obstructive uropathy or urinary fistulas. While the exact indications and long-term results of such management are generally still unknown, these endourologic procedures are now being increasingly applied to selected renal-transplant recipients.

Index term: Kidney, transplantation

Cleve Clin Q 51:349-355, Summer 1984

Despite improving results after renal transplantation over the past decade, technical complications continue to contribute to the morbidity and mortality of transplant recipients. Since these patients are immunosuppressed and often azotemic, such complications are potentially life threatening and require early diagnosis and management to enhance subsequent survival of the patient and graft.

Endourologic procedures have become invaluable for the treatment of a wide variety of disorders, including obstructive uropathy and urinary fistulas, and further refinements of these techniques now allow their application to renal transplantation. While exact indications have yet to be defined and the long-term results are often still unknown, endourologic techniques are increasingly being used as both temporizing and definitive procedures.

¹ Section of Endourology, Department of Urology, The Cleveland Clinic Foundation. Submitted for publication Dec 1983; accepted Jan 1984. sb

0009-8787/84/02/0349/07/\$2.75/0

Copyright© 1984, The Cleveland Clinic Foundation.

1A, B

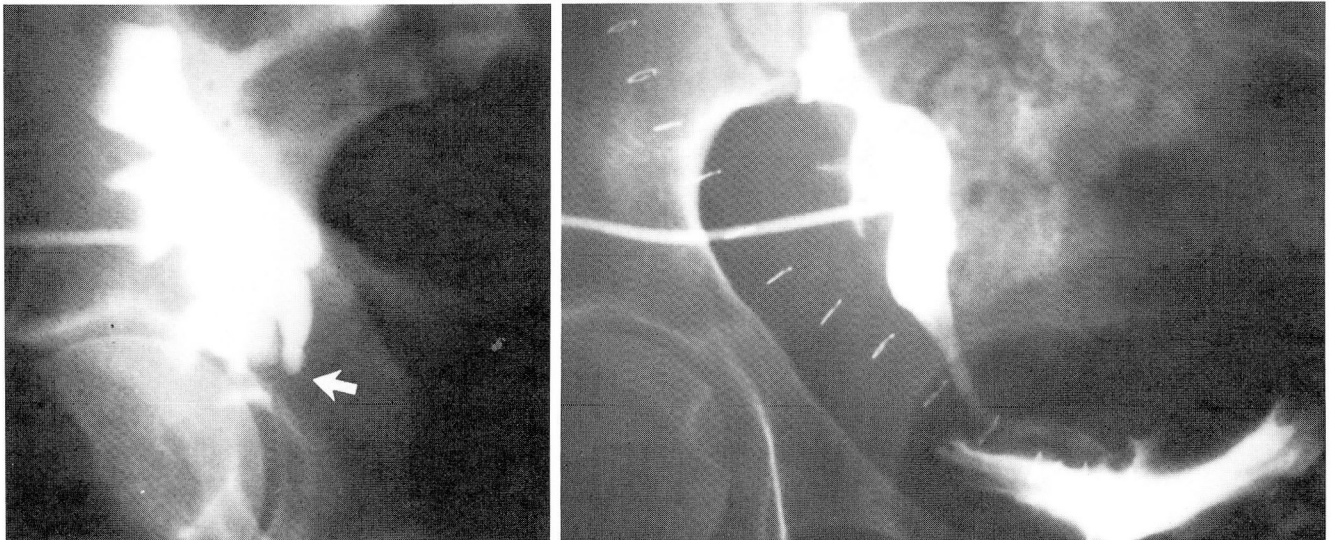


Fig. 1. A. Antegrade nephrostogram reveals complete obstruction at the proximal third of the transplanted ureter. The indwelling percutaneous nephrostomy tube was left in place to allow resolution of the obstructive uropathy prior to open surgical repair.

B. Antegrade nephrostogram, two weeks following ureterolysis and repeat ureteroneocystostomy, reveals resolution of the obstruction and no evidence of extravasation.

Obstructive uropathy

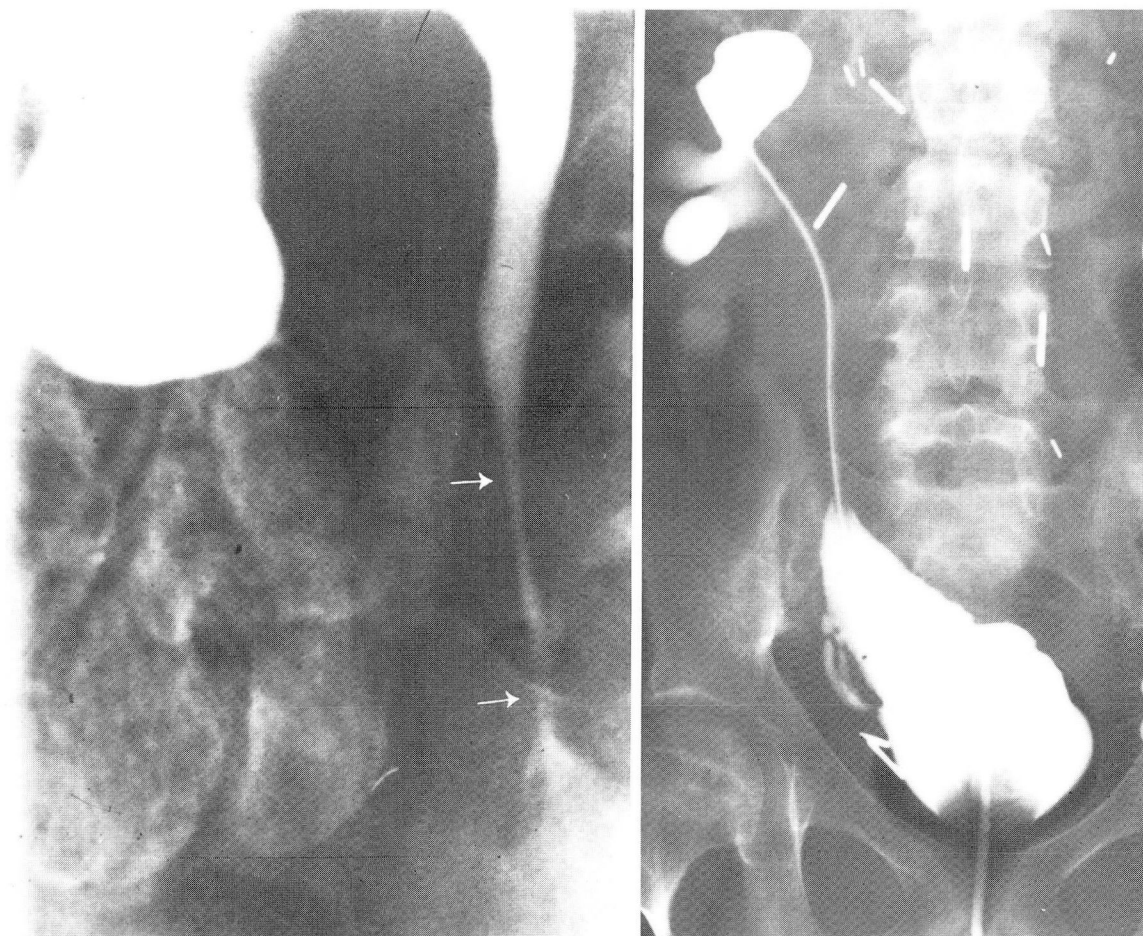
Obstructive uropathy occurs in approximately 10% of renal allograft recipients. When hydronephrosis is suggested by ultrasound or computed tomography, intravenous or retrograde pyelography is generally attempted to further define the level and etiology of the obstruction. Often, however, adequate visualization on an excretory urogram is precluded by the impaired renal function. Additionally, retrograde pyelography is often technically impossible following transplant ureteroneocystostomy. In such cases, percutaneous antegrade pyelography has proved most valuable and allows precise anatomic delineation of the site of obstruction.¹ The procedure is generally performed with ultrasound or computed-tomographic guidance using standard interventional radiographic methods. Conversion to temporary percutaneous nephrostomy drainage is then possible using one of several available techniques.²

The management of ureteral obstruction by temporary percutaneous nephrostomy drainage offers several advantages. The extent of recoverable renal function can be assessed after prolonged drainage, and renal function prior to definitive surgical repair can be optimized. In selected cases when the functional significance of an apparent obstruction is unclear, a Whitaker test may be performed for a definitive diagnosis. Initial percutaneous nephrostomy is also invaluable

for the treatment of urinary tract infection associated with the obstruction for drainage of a transplant pyohydronephrosis.³ In those cases when an open surgical procedure will ultimately prove necessary, the percutaneous nephrostomy can remain postoperatively to provide proximal diversion and protection of anastomoses. A further advantage in this setting is that this provides access to perform antegrade studies postoperatively to exclude extravasation or persistent obstruction at the anastomotic site.

Case report

A 28-year-old man received an HLA identical kidney from his sister. Urinary continuity was restored by a standard antirefluxing ureteroneocystostomy. His immediate postoperative course was uneventful, and a nadir creatinine level of 1.2 mg/dL was reached. He was readmitted to the hospital four weeks after the transplantation with acute pulmonary edema and renal failure, with a serum creatinine level of 8.6 mg/dL. Ultrasound revealed marked hydronephrosis of the transplanted kidney. Percutaneous nephrostomy drainage was immediately established. Renal function was regained, and the pulmonary edema resolved. An antegrade pyelogram revealed complete obstruction at the proximal third of the ureter (*Fig. 1A*). Exploration revealed acute angulation of the ureter at that site. Ureterolysis and repeat ureteroneocystostomy were performed, and the percutaneous nephrostomy tube was left in place for proximal diversion. Two weeks following that procedure, a repeat antegrade pyelogram showed complete resolution of the obstruction and no extravasation (*Fig. 1B*). The nephrostomy tube was removed, and the patient remains well with a serum creatinine level of 1.1 mg/dL seven months after transplantation.



2A, B

Fig. 2. A. Antegrade pyelogram reveals a long segment of distal ureteral stenosis one year following a repeat ureteroneocystostomy. Percutaneous nephrostomy drainage was established.

B. Adequate urinary drainage provided by an indwelling double-J ureteral stent passed antegrade via the percutaneous nephrostomy tract.

(Reprinted from Stroom and Novick¹ with the permission of W. B. Saunders, Co., Philadelphia, Pa.)

Comment: In selected cases, ureteral obstruction may be managed entirely by endourologic techniques. The percutaneous management of non-transplant ureteral stenosis using temporary indwelling ureteral stents has previously been described,⁴ and such therapy is now being evaluated for renal allograft recipients. Furthermore, antegrade placement of indwelling ureteral stents is often accomplished easily following percutaneous nephrostomy in transplant patients, even when retrograde catheterization is technically impossible.

Case report

A 12-year-old girl was the recipient of a cadaver renal transplant in September 1978. Her postoperative course was complicated by two episodes of acute rejection in the first four months; this was treated with methylprednisolone administered intravenously. Following the second rejection

episode, she remained azotemic with a serum creatinine level of 3.2 mg/dL. An acute rise in the serum creatinine value to 5.4 mg/dL was noted two years after transplantation and further evaluation revealed hydronephrosis secondary to distal ureteral stenosis. A repeat ureteroneocystostomy was performed, and the results of a renal biopsy specimen obtained at that time indicated chronic rejection. The serum creatinine level stabilized at 4.5 mg/dL, but then slowly rose. She was readmitted one year later with a serum creatinine value of 8.4 mg/dL. Hydronephrosis was again demonstrated by ultrasound. An antegrade pyelogram (Fig. 2A) revealed a long segment of distal ureteral stenosis. Percutaneous nephrostomy drainage was established. The serum creatinine level improved slightly, but stabilized at 7.2 mg/dL. In view of the associated chronic rejection and poor prognosis for the graft, repeat operative intervention was not deemed appropriate. Retrograde ureteral catheterization and stenting was attempted, but was technically unsuccessful. Consequently, a double-J silastic ureteral stent was easily placed antegrade via the nephrostomy tract and left in position without complications (Fig. 2B). Further deterioration of renal function over the next six months

3A, B

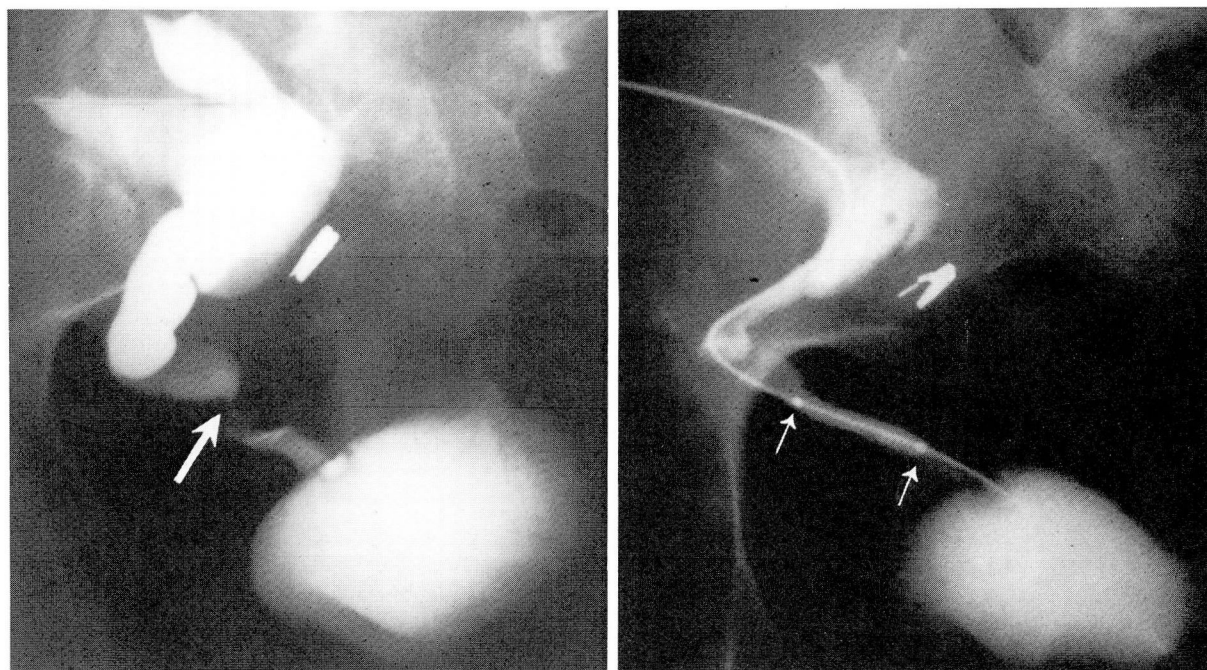


Fig. 3. A. Antegrade pyelogram reveals a segmental mid-ureteral stenosis. Percutaneous nephrostomy drainage was established.

B. Percutaneous antegrade balloon dilatation of the ureter performed via the previously established nephrostomy tract. (Reprinted from Stroom and Novick¹ with the permission of W. B. Saunders, Co., Philadelphia, Pa.)

ultimately led to a graft nephrectomy at which time a pathologic examination revealed chronic rejection.

Comment: Alternatively, an attempt may be made to treat transplant ureteral stenosis using balloon dilatation.⁵ In these cases, a guide wire is passed through a percutaneous nephrostomy tube and then through the site of stenosis. The nephrostomy tube is exchanged for an angioplasty balloon dilator which is then inflated. The balloon dilator is replaced with an indwelling ureteral stent which is generally left in place for at least two weeks.

Case report

An 18-year-old man was the recipient of a living-related renal transplant from his mother in May 1982. His nadir serum creatinine level was 1.0 mg/dL. The postoperative course was complicated by one episode of acute rejection; this was treated with methylprednisolone administered intravenously. The subsequent serum creatinine value was 3.4 mg/dL. A later rise in the serum creatinine level to 5.3 mg/dL was evaluated with ultrasound; hydronephrosis was revealed. Percutaneous nephrostomy drainage was established, and the serum creatinine level decreased to 3.6 mg/dL. An antegrade pyelogram revealed segmental stenosis of the mid-ureter (*Fig. 3A*). Antegrade percutaneous transluminal balloon dilatation of the ureter was performed (*Fig. 3B*). A ureteral stent was left in place for three weeks and then removed. The serum creatinine level currently remains stable at 3.8 mg/dL nine months after the balloon-dilatation

procedure without evidence of hydronephrosis on repeat sonograms.

Urinary Fistulas

Urinary fistulas are major complications generally evident in the early post-transplant period. In these patients, the rate of technical failure and graft loss following open surgical repair may approach 30%,⁶ with a mortality rate of approximately 20%.⁷ Vesical fistulas occur more commonly in patients with diabetes, multiple prior bladder operations, or persistent outlet obstruction. Occasionally, small vesical fistulas may be managed nonoperatively by employing extended catheter drainage alone as long as the urine is not infected and the patient's clinical course remains satisfactory.⁸

Calyceal and ureteral fistulas generally result from local ischemic factors. Fortunately, careful attention to detail when obtaining kidneys from living-related donors and cadavers, coupled with improved management of multiple renal arteries in the recipient, has resulted in a lower incidence of such problems.⁹

Early operative intervention has generally been advocated for the treatment of urinary fistulas. Recently, however, a nonoperative percutaneous approach has been employed successfully for such

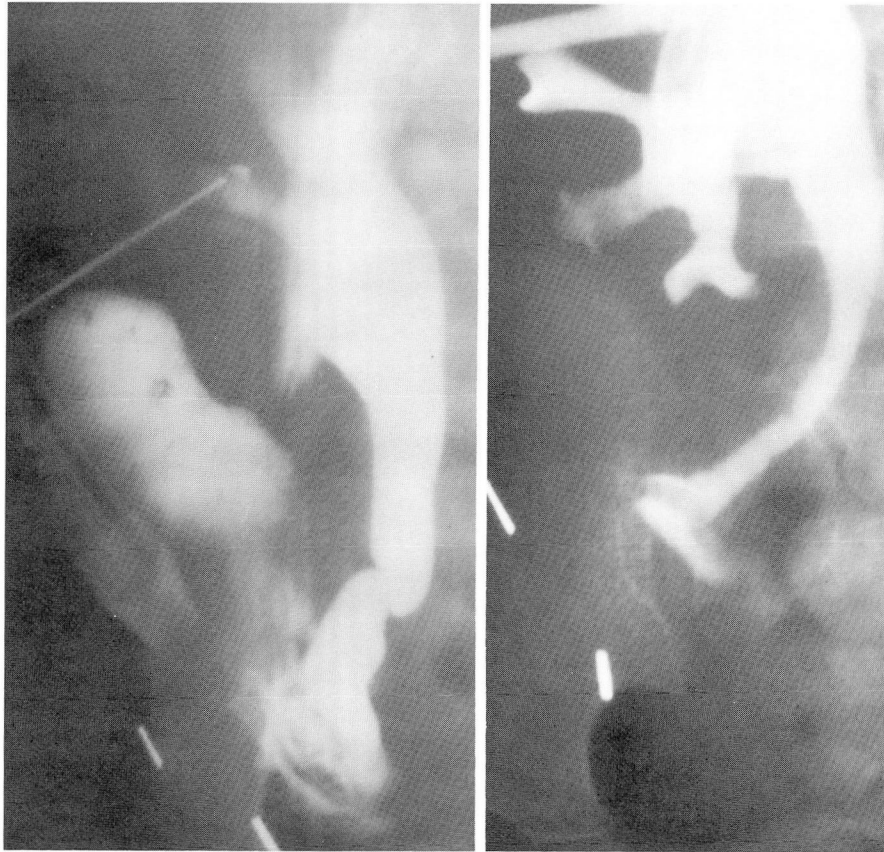


Fig. 4. A. Antegrade pyelogram reveals extravasation from the distal ureter. Percutaneous nephrostomy drainage was established.

B. Antegrade nephrostogram six weeks later revealed resolution of the extravasation, although distal ureteral obstruction was evident.
(Courtesy of Dr. Stuart Flechner)

fistulas in non-transplant patients and such techniques are currently being applied to renal allograft recipients. A recent retrospective study noted the value of preliminary open nephrostomy diversion alone in the management of selected patients with transplant urinary fistulas,⁶ and that approach has now been modified so that percutaneous drainage, rather than open nephrostomy drainage, can be employed with or without ureteral stenting.

Case report

A four-year-old boy was the recipient of a living related renal transplant from his mother. The kidney was placed intraperitoneally. Excellent function was obtained in the period immediately after transplantation; the nadir serum creatinine level was 0.5 mg/dL. Two weeks after the operation, fever, ileus, and anuria developed. The serum creatinine level rose to 2.6 mg/dL, and a renal scan suggested urinary extravasation. An antegrade pyelogram was obtained and revealed distal ureteral extravasation (Fig. 4A).

Percutaneous nephrostomy drainage was then instituted; the fever, ileus, and azotemia resolved. An antegrade nephrostogram six weeks later revealed total distal ureteral occlusion (Fig. 4B). Repeat ureteroneocystoscopy was then performed; both a ureteral stent and the previously positioned percutaneous nephrostomy tube were left in place (Fig. 5A). The ureteral stent was then removed two months later, at which time a repeat antegrade nephrostogram revealed no obstruction or extravasation (Fig. 5B). The nephrostomy tube was then removed and the results of excretory urography performed six months later were normal (Fig. 6). The serum creatinine value is currently 0.5 mg/dL.

Comment: In some cases, this approach has proved definitive and has obviated the need for subsequent surgical repair. In one report, five of six fistulas closed spontaneously one day to 10 weeks after percutaneous nephrostomy drainage. While ureteral strictures developed in 3 of those patients, 2 of them responded to dilatation by percutaneous stent placement.¹⁰

5A, B

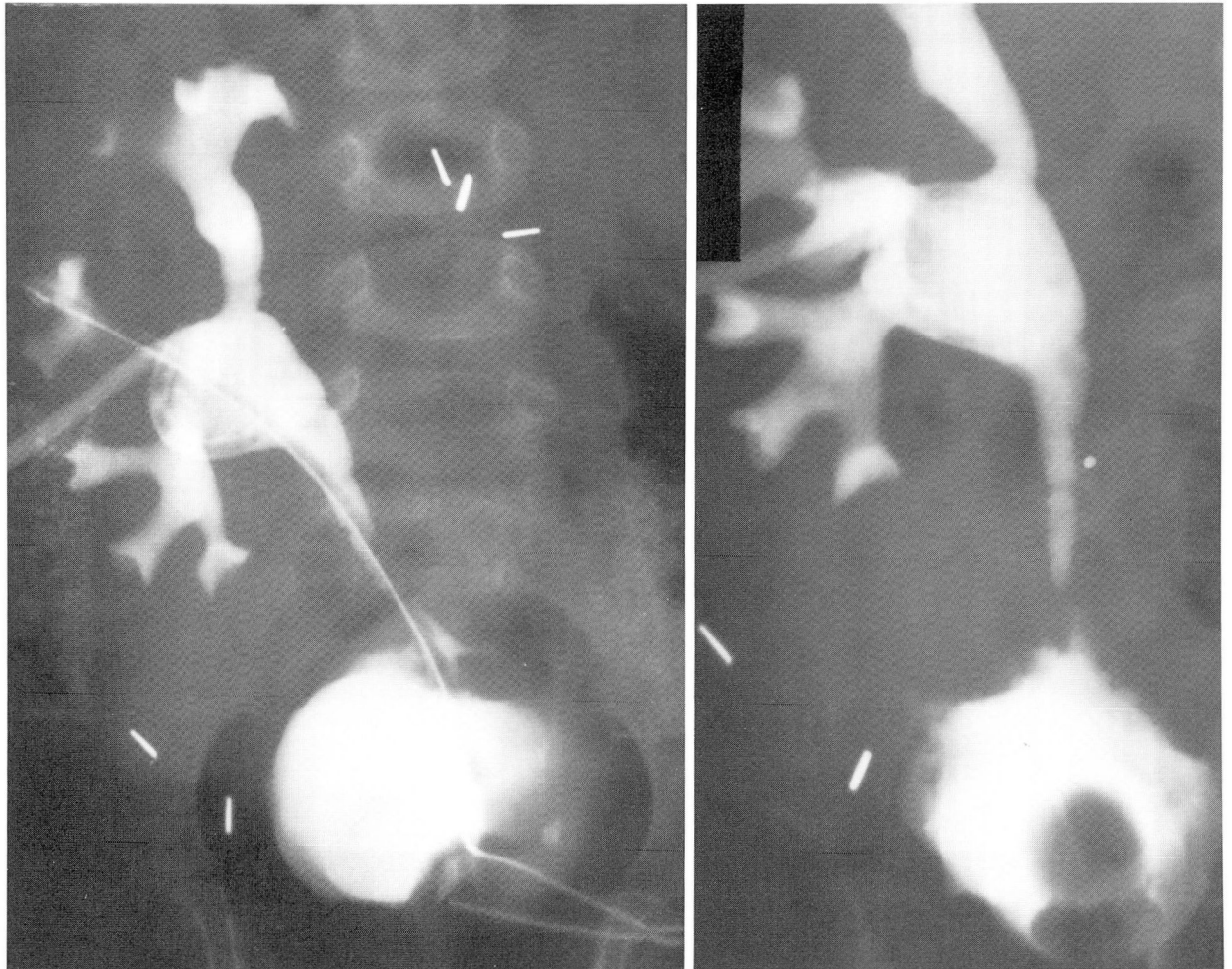


Fig. 5. A. Indwelling ureteral stent and percutaneous nephrostomy tube, providing drainage following repeat ureteroneocystostomy

B. Antegrade nephrostogram following removal of the ureteral stent shows resolution of obstruction without extravasation. (Courtesy of Dr. Stuart Flechner)

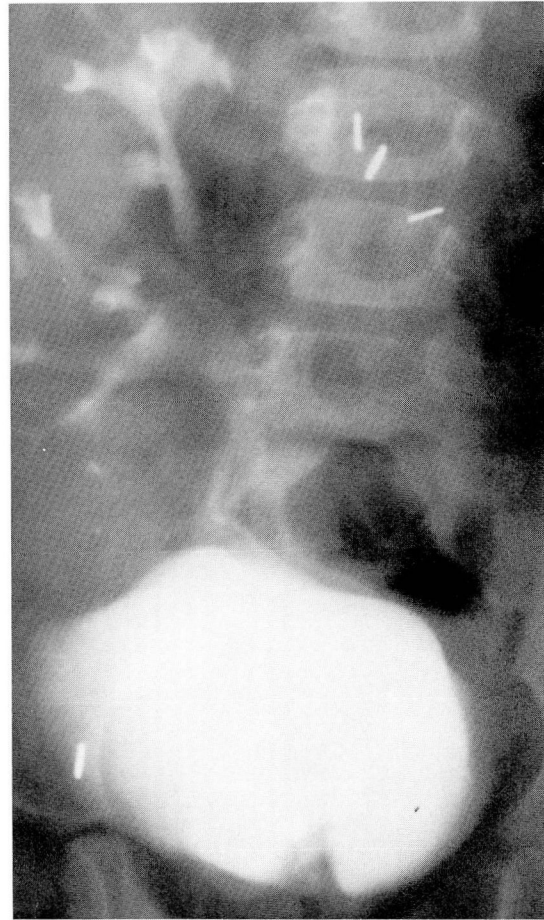
Summary

Technical complications continue to occur in a substantial proportion of renal allograft recipients. In these patients, immunosuppression and diminished renal function compromise wound healing and the ability to withstand the stress of repeated surgery. The introduction of endourologic techniques to renal transplantation has had a significant impact on the treatment of post-transplant urologic complications. In some instances, the nonoperative approach has proved useful as a temporizing procedure, while in others it has proved definitive. While many of these techniques are still being evaluated and long-term results are often unknown, their indications appear to be broadening and the frequency of their use is increasing.

References

1. Strem SB, Novick AC. Pelvic imaging techniques in renal transplantation. *Urol Clin N Am* 1983; **10**:301-313.
2. Stables DP. Percutaneous nephrostomy: techniques, indications, and results. *Urol Clin N Am* 1982; **9**:15-29.
3. Barbaric ZL, Thomson KR. Percutaneous nephropylotomy in the management of obstructed renal transplants. *Radiology* 1978; **126**:639-642.
4. Lang EK, Lanasa JA, Garrett J, Stripling J, Palomar J. The management of urinary fistulas and strictures with percutaneous ureteral stent catheters. *J Urol* 1979; **122**:736-740.
5. Lieberman SF, Keller FS, Barry JM, Rösch J. Percutaneous antegrade transluminal ureteroplasty for renal allograft ureteral stenosis. *J Urol* 1982; **128**:122-124.
6. Goldstein I, Cho SI, Olsson CA. Nephrostomy drainage for renal transplant complications. *J Urol* 1981; **126**:159-163.
7. Schiff M Jr, McGuire EJ, Weiss RM, Lytton B. Management of urinary fistulas after renal transplantation. *J Urol* 1976; **115**:251-256.
8. Novick AC. Surgery of renal transplantation and complica-

- tions. [In] Novick AC, Straffon RA, eds. *Vascular Problems in Urologic Surgery*. Philadelphia, WB Saunders, 1982, pp 233-260.
9. Salvatierra O Jr, Kountz SL, Belzer FO. Prevention of ureteral fistula after renal transplantation. *J Urol* 1974; **112**:445-448.
 10. Lieberman RP, Glass NR, Crummy AB, Sollinger HW, Belzer FO. Nonoperative percutaneous management of urinary fistulas and strictures in renal transplantation. *Surg Gynecol Obstet* 1982; **155**:667-672.



→
Fig. 6. Excretory urogram six months following removal of the percutaneous nephrostomy tube reveals normal transplant anatomy.
(Courtesy of Dr. Stuart Flechner)