

Massive unilateral renal hematuria associated with hydronephrosis¹

Jeffrey M. P. Siminovitch, M.D.
Gerald P. Herman, M.D.
Ronald Chapnick, M.D.

The authors describe a massive unilateral hematuria from a hydronephrotic kidney. The pathologic finding of renal vein herniations is reported.

Index terms: Hematuria • Hydronephrosis • Renal veins

Cleve Clin Q 51:377-379, Summer 1984

Massive unilateral renal hematuria without any apparent morphologic etiology has been ascribed to chronic hemorrhagic papillitis¹ or renal venous malformations.² The following case describes a patient with a ureteral obstruction and massive unilateral renal hematuria. Urinary tubular material was found in the renal veins.

Case report

A 62-year-old man was admitted complaining of an acute onset of severe right flank pain and irritable voiding symptoms followed by gross hematuria. The physical examination was unremarkable except for some right flank tenderness. The excretory urogram revealed delayed right renal visualization with hydronephrosis to the ureterovesical junction (*Fig. 1A*). At cystoscopy, blood could be seen flowing from the right ureteral orifice. A right retrograde pyelogram revealed mid-ureteral filling defects consistent with blood clots, but no obstruction was identified (*Fig. 1B*). Ureteral brushing and urine cytology were performed; the results of both did not reveal tumor cells. The patient continued to have gross hematuria and required transfusions. Subsequently, he underwent a right renal exploration. At

surgery, the right kidney was exposed and a pyelotomy resulted in the extrusion of copious blood clots. Fresh bleeding persisted intrarenally. A nephrectomy was performed. The patient's postoperative course was uneventful.

Pathology

A gross examination of the specimen revealed a 390-g kidney with an attached dilated ureter. The mucosa of the calyces, pelvis, and ureter was severely hemorrhagic. Microscopically, striking hemorrhagic and inflammatory changes were seen in the submucosal regions of the pelvis and calyces. Intratubular bleeding in the medullary and cortical zones were marked with occasional red blood cells in Bowman's spaces. Throughout the renal parenchyma, but more prominently in the inflamed fornical areas, hyaline material was present within the tubular lumens, interstitium, and vascular spaces (*Fig. 2A*); these appeared as polypoid extrusions which were herniating into the lumen of thin-walled veins. This material appeared vividly after application of the periodic acid Schiff (PAS) stain. Immunoperoxidase staining for Tamm-Horsfall protein was also positive (*Fig. 2B*).

Discussion

Unilateral renal gross hematuria without any apparent underlying pathology has bewildered physicians for decades and has been variously ascribed to vascular and/or inflammatory processes of unknown etiology. The finding of associated ureteral obstruction was noticed by Nation et al³ in 1 of 6 patients with unilateral renal gross hematuria. The clinical course of this case paralleled the case described here. The pathologic

¹ Departments of Urology (J.M.P.S., G.P.H.) and Pathology (R.C.), Lake County Memorial Hospital, Willoughby, Ohio. Submitted for publication Dec 1983; accepted Jan 1984. sb

0009-8787/84/02/0377/03/\$1.75/0

Copyright © 1984, The Cleveland Clinic Foundation.

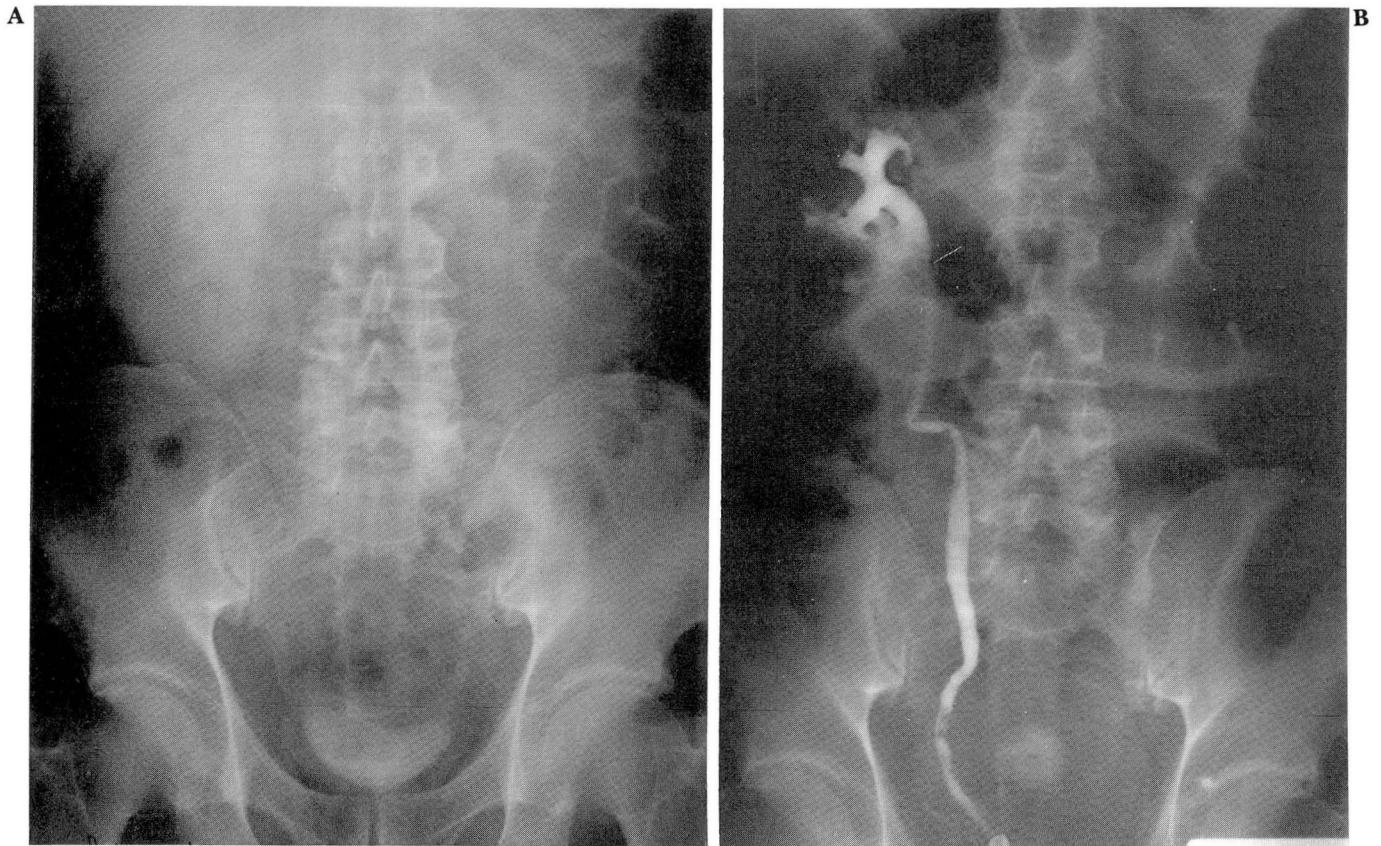


Fig. 1. A. Excretory urography (two-hour delayed image), revealing right hydronephrosis
 B. Right retrograde pyelogram, demonstrating lower ureteral filling defects without an apparent obstruction

finding of herniated polyps into the renal veins was identified during a postmortem examination of 68 patients;⁴ 48 of these patients had had concomitant hydronephrosis. Two patients reported by Iliff and Galdabini⁵ suffered hydronephrosis with massive intratubular hemorrhage, tubular rupture, and renal venous polypoid extrusions as found during a subsequent nephrectomy. When the specimens were later tested for Tamm-Horsfall protein by immunofluorescence techniques, the interstitial and intravenous masses were found to fluoresce brightly.⁶ These authors postulated that rapid-onset hydronephrosis produced a renal tubular rupture with subsequent renal vein impingement and communication which resulted in hematuria. After confirming similar findings of tubular material rupturing into renal veins occurring with ureteral obstruction in four cases, Bhagavan et al⁷ duplicated these findings in cadaver kidneys. By injecting the specimens via their ureters and veins simultaneously with different colored markers, a pyelovenous mixture was identified with increas-

ing injection pressures. Ureteral injection pressures greater than 50 mm Hg produced extravasation from the calyces into the interstitium adjacent to the small veins. Similar experiments with rat tubules produced tubulovenous communications at pelvic pressures of 40–80 mm Hg.

In the case described here, we believe that the unusual finding of tubular rupture with extrusion of Tamm-Horsfall protein into the renal interstitium and veins was due to hydronephrosis secondary to acute ureteral obstruction. Although no anatomic cause for this obstruction was identified, the most likely explanation is spontaneous passage of a small stone which was not recovered.

In clinical urologic practice, acute ureteral obstruction is a common phenomenon usually producing renal pelvic pressures of 20–25 mm Hg, but may lead to pressures surpassing the 50 mm Hg needed experimentally for tubular rupture to occur.⁸ This pelvic pressure elevation depends on the rate of urine flow prior to occlusion and the extent of renal pelvic contractions. Yet, the occurrence of intratubular hemorrhage from tu-

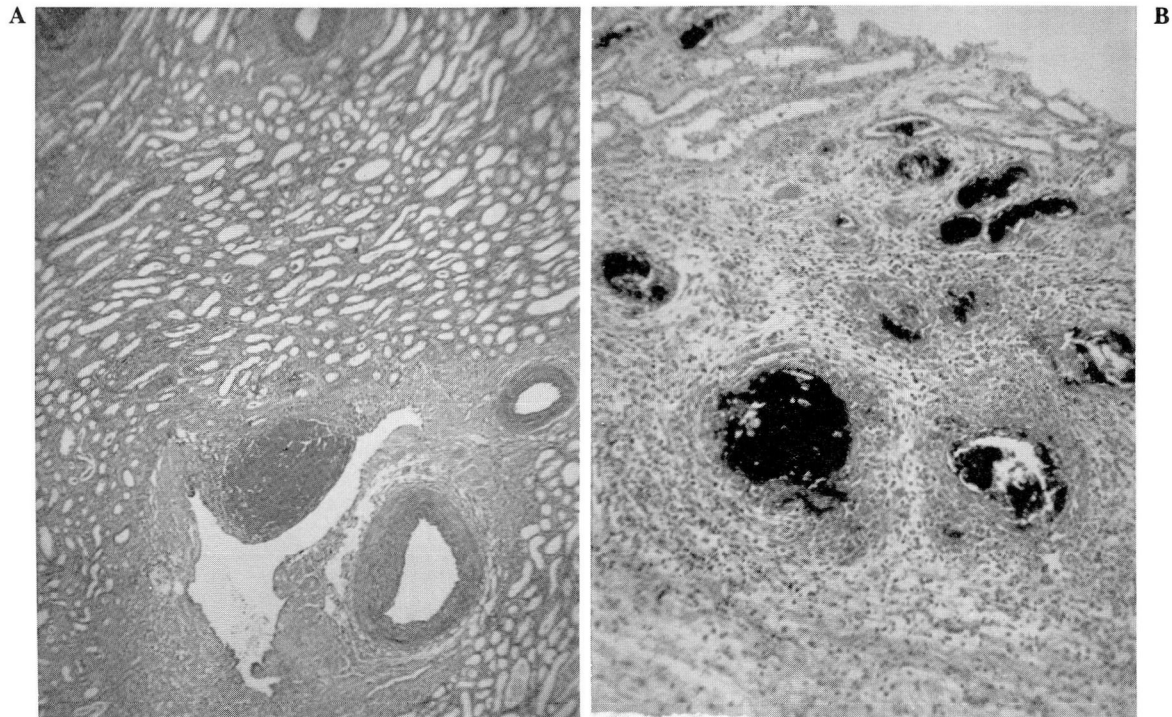


Fig. 2. A. Renal papilla with tubules and a large caliber vein with extrusion of amorphous material into the lumen (PAS stain).

B. Immunoperoxidase staining for Tamm-Horsfall protein is positive for amorphous material found within the tubes and intravenously.

bular rupture is rarely documented. This may be due to compensatory mechanisms for renal pelvic pressure reduction (i.e., pelvic expansion, lymphatic back flow, fornical rupture and extravasation, or papillary foramina compression) which prevent this pressure from being transmitted to the tubules.

References

1. McKay HW, Baird HH, Lynch KM Jr. Two unusual causes of renal hematuria. *J Urol* 1949; **61**:1-10.
2. Devlin AB, Buchanan WM, Yates AJ. Vascular abnormalities in renal fornical haemorrhage. *J R Coll Surg Edinb* 1979; **24**:238-242.
3. Nation EF, Butt EM, Massey BD, Gallup CA. Palindromic unilateral renal purpura: an explanation for renal hematuria of obscure origin. *J Urol* 1952; **68**:74-87.
4. Barrie HJ. Herniations into the renal veins with special reference to hydronephrosis. *J Path Bact* 1961; **82**:177-182.
5. Iliff WJ, Galdabini JJ. Massive intratubular hemorrhage with herniations into renal veins requiring nephrectomy. *J Urol* 1972; **108**:44-49.
6. Solez K, Heptinstall RH. Intrarenal urinary extravasation with formation of venous polyps containing Tamm-Horsfall protein. *J Urol* 1978; **119**:180-183.
7. Bhagavan BS, Wenk RE, Dutta D. Pathways of urinary backflow in obstructive uropathy: demonstration by pigmented gelatin injection and Tamm-Horsfall uromucoprotein markers. *Hum Pathol* 1979; **10**:669-683.
8. Michaelson G. Percutaneous puncture of the renal pelvis, intrapelvic pressure and the concentrating capacity of the kidney in hydronephrosis. *Acta Med Scand [Suppl]* 1974; **559**:1-26.