

Juvenile aponeurotic fibroma: a case report of a rare tumor¹

Steven R. Weasen, M.D.
John M. Pelachyk, M.D.²
Wilma F. Bergfeld, M.D.

A 15-year-old boy had a juvenile aponeurotic fibroma (Keasbey's tumor) on the left foot. Physicians should be aware of this tumor and its tendency to recur.

Index terms: Fibroma, occurrence • Foot, pathology

Cleve Clin Q 51:467-469, Summer 1984

Juvenile aponeurotic fibroma (synonyms: calcifying fibroma, Keasbey's tumor) is a rare tumor first described by Keasbey in 1953.¹ We describe a typical case involving this neoplasm.

Case report

In November 1982, a 15-year-old boy presented to the Cleveland Clinic, Department of Pediatrics, for evaluation of a left foot mass that had recurred after an excision in 1980. Since early 1982, he had had progressive discomfort in his left foot during ambulation. The physical examination revealed a firm non-mobile mass beneath the second metatarsal shaft. Other physical examination findings were normal. The plain radiograph of the left foot was unremarkable

except for the demonstration of a slight calcification near the distal shaft of the second metatarsal. The following laboratory values were either negative or normal: complete blood cell count, general chemical survey (SMA-18), prothrombin level and partial thromboplastin time, and urinalysis.

During excision, the tumor was found to be adherent to the underlying scar. Deeper portions of the tumor were adherent to and in continuity with the plantar aponeurosis (*Fig. 1*). The gross specimen showed a 2-cm grayish rubbery mass with areas of calcification (*Fig. 2*). A microscopic examination revealed a poorly circumscribed fibrous tumor with scattered foci of calcification and cartilage formation. The fibroblastic tumor cells were surrounded by a dense collagenous stroma and had plump, slightly vesicular, ovoid nuclei with indistinctly outlined cytoplasm. Mitoses were rare, but occasional multinucleated giant cells were found (*Fig. 3*). In the foci of calcification, cells possessing varying degrees of similarity to chondrocytes were present, and the surrounding fibroblastic cells tended to have a linear or palisaded arrangement (*Fig. 4*). These histologic findings were compatible with those of a calcifying fibroma.

Discussion

Since 1953 when Keasbey first described this distinctive fibrous tumor and named it "juvenile aponeurotic fibroma," more than 60 cases have been reported. Some series show an increased incidence in male patients.² The tumor is usually an asymptomatic or tender, slowly growing mass located predominantly on the hands (palms or fingers) and feet (soles) of children and young adults. Usually, the tumor is less than 3 cm in size. No other diseases are associated with this fibroma.

¹ Departments of Dermatology (S.R.W., J.M.P., W.F.B.) and Pathology (J.M.P., W.F.B.), The Cleveland Clinic Foundation. Submitted and accepted for publication March 1984.

² Present address: Pinkus Dermatopathology Laboratory, P.O. Box 360, Monroe MI 48161. jw

0009-8787/84/02/0467/03/\$1.75/0

Copyright © 1984, The Cleveland Clinic Foundation.

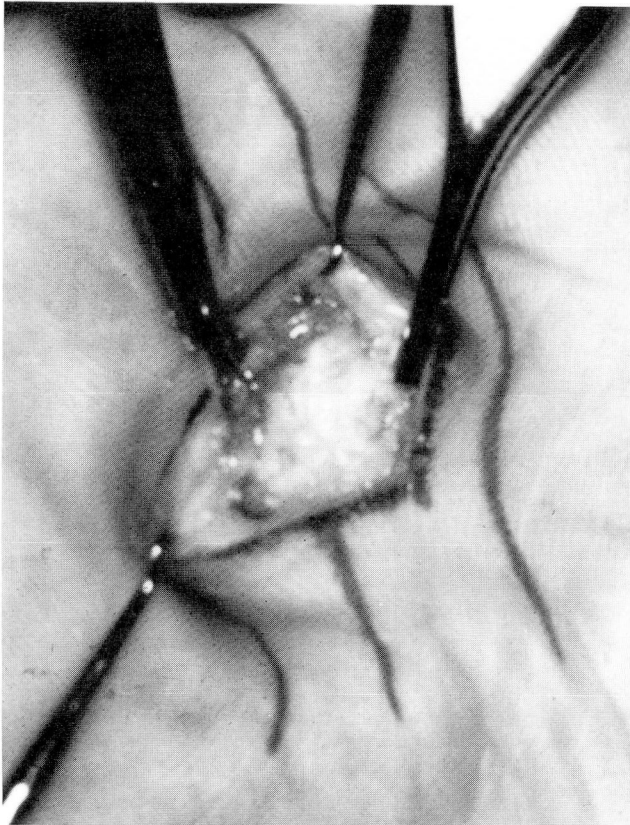


Fig. 1. An ill-defined mass adherent to an underlying scar at the previous excision site on the left plantar surface of foot

The gross pathologic examination reveals a poorly marginated solid or rubbery gray-white mass characteristically containing flecks of calcification and often attached to aponeurosis, fascia,

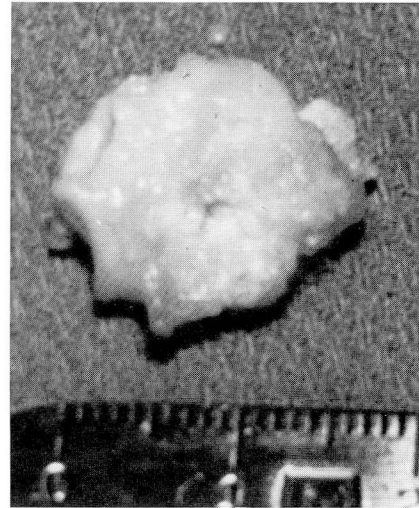

Fig. 2. Gross pathologic specimen, demonstrating a 2-cm rubbery, gray-white mass with flecks of calcifications

or tendons. Histologically, the tumor is characterized by a dense proliferation of plump fibroblasts with ovoid nuclei and indistinct cytoplasm surrounded by a dense collagenous stroma.¹ Foci of calcification and cartilage formation are invariably present in older lesions, and the fibroblasts surrounding these foci are in a peculiar linear or palisaded arrangement.^{1,2}

Although these tumors are locally aggressive and tend to recur following surgery, Enzinger and Weiss¹ did not report any malignant transformation or metastases. For symptomatic tumors, conservative surgical excision is the treat-

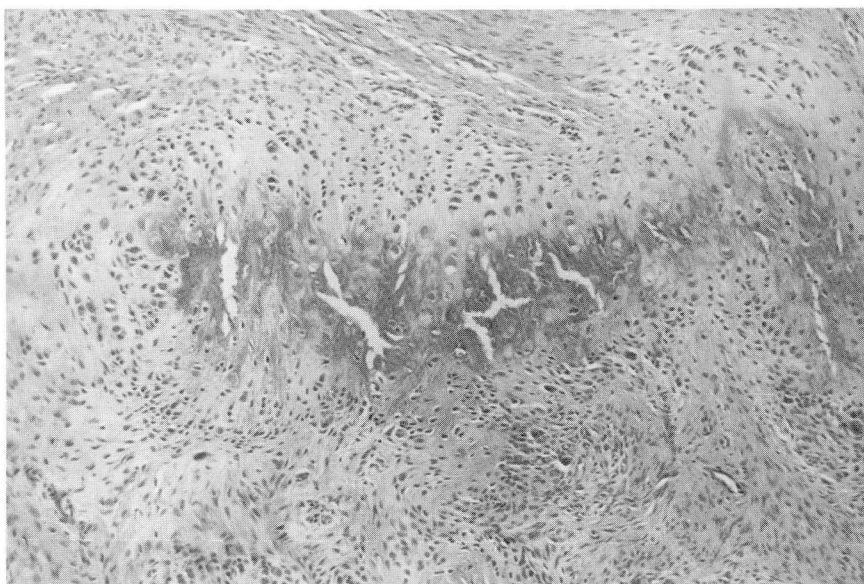


Fig. 3. Biopsy specimen demonstrates a dense proliferation of fibroblasts with occasional giant cells adjacent to a calcific focus (hematoxylin-eosin stain, $\times 10$ [original magnification]).

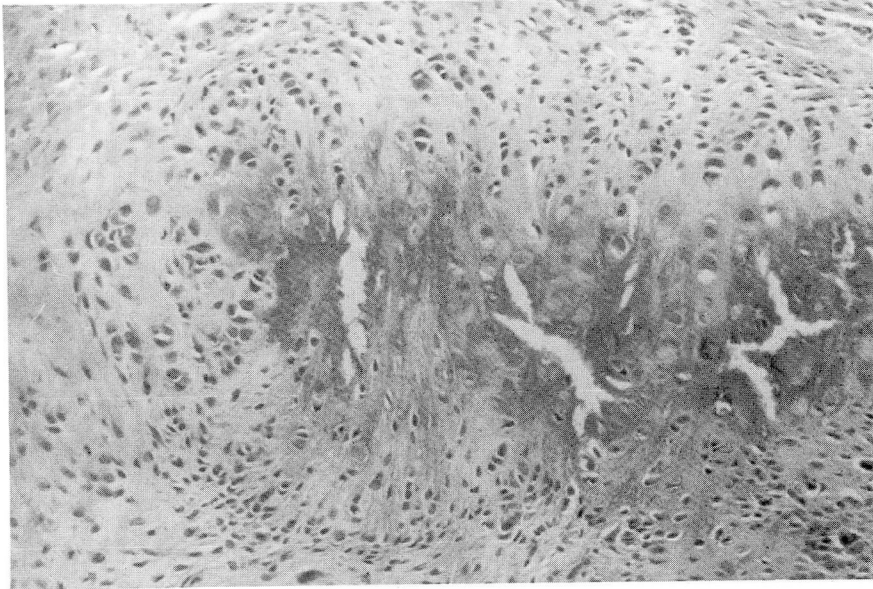


Fig. 4. Biopsy specimen demonstrates palisaded fibroblasts surrounding the calcific focus (hematoxylin-eosin stain, $\times 20$ [original magnification]).

ment of choice,³ and re-excising a recurrent tumor is preferred to performing an extensive surgical dissection. A functional defect is likely attributable to surgical complications rather than to tumor growth.

Acknowledgment

We wish to thank those Cleveland Clinic physicians who participated in the diagnosis and treatment of this patient:

Robert J. Cunningham, M.D., Pediatrics; Jack T. Andrish, M.D., Orthopaedics; and Bruce A. Sebek, M.D., Pathology.

References

1. Enzinger FM, Weiss SW. Calcifying aponeurotic fibroma. [In] Enzinger FM, Weiss SW, eds. *Soft Tissue Tumors*. St. Louis, CV Mosby, 1983, pp 93-98.
2. Allen PW, Enzinger FM. Juvenile aponeurotic fibroma. *Cancer* 1970; **26**:857-867.
3. Keller RB, Baez-Giangreco A. Juvenile aponeurotic fibroma. Report of three cases and a review of the literature. *Clin Orthop* 1975; **106**:198-205.