

Primary rectal lymphoma staged by magnetic resonance imaging: case report of an unusual cause of rectal bleeding¹

James Church, M.D.
Barry Bodie, M.D.
David G. Jagelman, M.D.
Edward Buonocore, M.D.

Rectal ulcerative disease causing bleeding is a familiar medical disorder. The usual serious diagnoses include carcinoma, chronic ulcerative colitis, and nonspecific benign ulcerative proctitis. The following case represents an unusual cause of rectal bleeding that was originally misdiagnosed even after the histologic study of multiple rectal biopsy specimens. Conventional radiographic and newer imaging techniques for diagnosis and staging of pelvic neoplasms can be compared.

Case report

A 28-year-old white man presented to the Colorectal Department at the Cleveland Clinic in December 1983 with a 12-month history of rectal bleeding on defecation, weight loss of 14 kg over eight months, diarrhea for two weeks, and fever (to 40° C). Investigations at other hospitals included a barium enema study, colonoscopy, and four rectal biopsies, which resulted in various conclusions (carcinoma, colitis, and granulations). He was treated for brief periods with methylprednisolone, sulfasalazine (Azulfidine), gentamicin, and clindamycin without relief of symptoms. Vital signs on admission were: weight, 67.7 kg; temperature, 40° C; pulse rate, 130/min; blood pressure, 110/70 mm Hg. No

abnormality was noted during the abdominal examination. Lymphadenopathy was not evident. An anorectal examination revealed a hard, knobby, circumferential mass extending from the dentate line to 5 cm from the anal verge, atypical of carcinoma. Above 5 cm, the rectal mucosa was normal. On admission, the results of routine serum laboratory tests were all within normal limits except for a mildly elevated serum alkaline phosphatase level (114 U/dL).

The chest radiograph was normal. The barium enema examination revealed an irregular diffusely and severely ulcerated circumferential mucosal pattern confined to the lower rectum (*Fig. 1*). Computed tomography (CT) scans showed a thick rectal wall. Pararectal, pelvic, and periaortic retroperitoneal lymph nodes were enlarged, but were overlooked during the initial interpretation (*Fig. 2*).

A repeat biopsy of the rectal lesion was performed, and the specimen was interpreted as a malignant B-cell lymphoma (high-grade immunoblastic type).^{*} A bone marrow examination was normal. Magnetic resonance scans (transverse projection), using a TE (echo time) of 30 and 60 msec and a TR (repetition time) of 1,000 msec, were obtained. The rectal wall was shown to be thick, and diffuse enlargement of pelvic and periaortic lymph nodes was noted (*Fig. 3* [compare with *Fig. 4*]). Additional medium-strength signals were identified in the peripelvic fat interpreted as neoplastic infiltration. Treatment was begun with combination chemotherapy using doxorubicin hydrochloride (Adriamycin), vincristine, cyclophosphamide, and prednisone in the first of a series of three weekly administrations.

Discussion

Primary rectal lymphoma, usually not considered in patients with rectal bleeding, accounts for between 3% and 6% of all primary gastrointestinal lymphomas.¹⁻³ Arriving at a diagnosis in the case reported here was made more difficult by the inability to make a histologic diagnosis of lymphoma based on initial biopsies performed prior to the patient's referral to the Cleveland

¹ From the Departments of Colorectal Surgery (J.C., B.B., D.G.J.) and Radiology (E.B.), The Cleveland Clinic Foundation. Submitted for publication and accepted Jan 1984. sb

* Rappaport classification: histiocytic; Lukes-Collins classification: B-cell immunoblastic sarcoma.

0009-8787/84/02/0477/03/\$1.75/0

Copyright © 1984, The Cleveland Clinic Foundation.

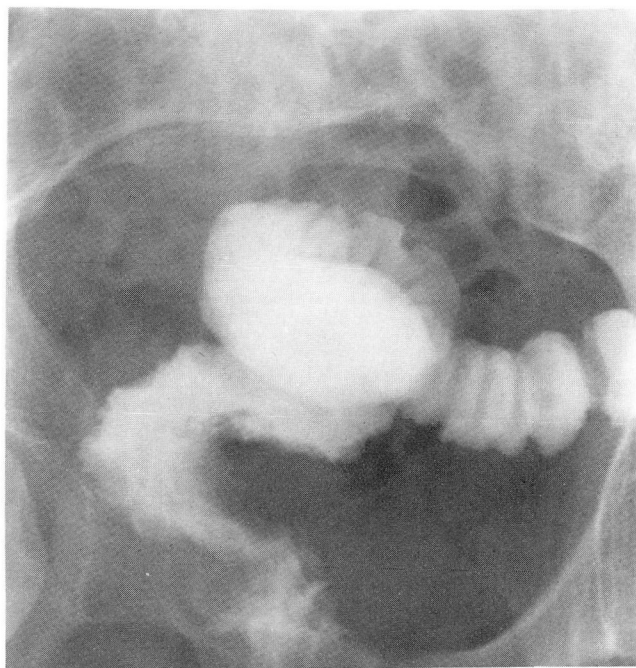


Fig. 1. Frontal view of the pelvis after instillation of barium into the rectum. Note that the distal 5 cm of the rectum is irregular, ulcerated, and contracted.

Clinic. Treatment had been for nonspecific ulcerative proctitis only. A proctoscopic examination was performed at the Cleveland Clinic and excluded the diagnosis of benign ulcerative proctitis. The endoscopic appearance of the rectal lesion was atypical for carcinoma and was more characteristic of a lymphomatous process, which was confirmed by biopsy.

Both clinical staging and histologic grading are important for determining the treatment and

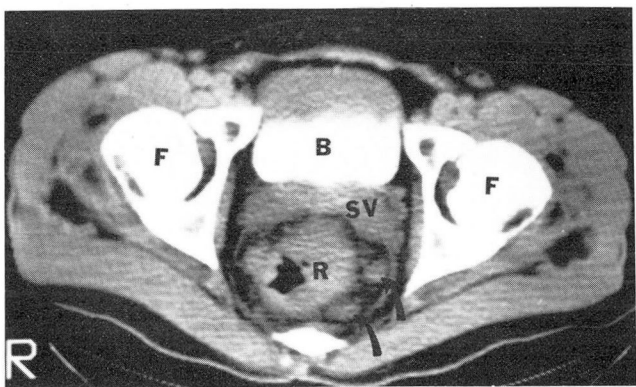


Fig. 2. Transverse CT scan of the pelvis. Contrast media was given intravenously and was identified within the urinary bladder (B). The seminal vesicles (SV) and thickened irregular rectal wall (R) can be identified. Nodular soft tissue densities are seen in the pararectal fat (arrows); these were overlooked initially. F = femoral head.

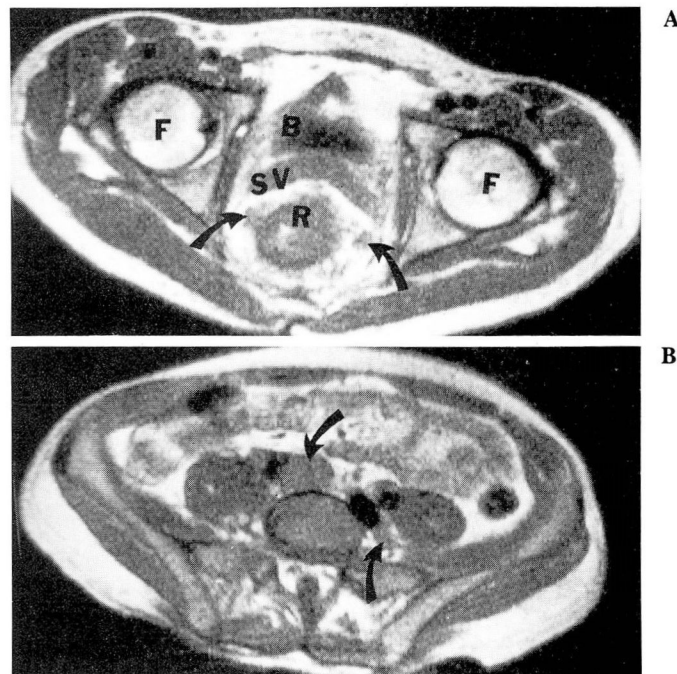


Fig. 3. A. Transverse magnetic resonance scan at the level of the femoral heads (F) (approximately the same level as the CT scan [Fig. 2]). The bladder, seminal vesicles, and the thickened rectal wall can be identified. Note the similar configuration of densities invading the pararectal fat, resembling that seen in Figure 2.

B. Transverse magnetic resonance scan at the level of the upper pelvis. Large lymph nodes can be identified adjacent to the pelvis vessels. Note that the signal strength is similar to that seen in adjacent muscle.

prognosis of gastrointestinal lymphomas as well as carcinomas of the pelvic organs.⁴⁻⁶ Filippa et al⁵ have reported that a lymphoma with the same histologic grade as the lymphoma described here has a poor prognosis, a high rate of extra-abdominal recurrence, and is associated with a median patient survival of seven months. Such an advanced histologic grading is consistent with the findings and extent of spread seen on CT and magnetic resonance scans.⁵

Clinical staging of gastrointestinal tumors involves an assessment of the extent of local spread, lymph node involvement, and the metastases to other organs. In areas apart from the pelvis, intra-abdominal assessment of local tumor spread from the gastrointestinal tract is often done during surgery. In localized rectal lymphomas or small localized rectal carcinomas which may be treated first by either chemotherapy, radiotherapy, or local resection, this is not possible. The use of CT for staging of primary gastrointestinal lymphomas and carcinomas has been described.⁷⁻⁹ Good results have been reported, usu-

ally with large tumors and extensive nodal involvement. In the case described here, CT demonstrated the typical thickened bowel wall and enlarged periaortic retroperitoneal nodes, but did not provide an indication of the extent of local pelvic spread or pelvic nodal status. This information was clearly defined by magnetic resonance imaging.

Ultrasound and CT have virtually been abandoned as a way to stage rectal tumors. Lymph node involvement, peri-rectal fat invasion, and peritoneal implants are not detected with sufficient accuracy by conventional imaging techniques due to bone and gas shielding, beam hardening artifacts, and insufficient contrast sensitivity to differentiate normal from abnormal tissues.

Magnetic resonance imaging provides a greater dynamic range and contrast sensitivity than CT. Operator-controlled methods are available with magnetic resonance imaging to enhance tissue planes and differentiate the vascular structure from the adjacent tumor. Magnetic moment properties of tissue-hydrogen nuclei are not influenced by overlying bone or gas. Pelvic fat and gastrointestinal gas are natural magnetic resonance contrast media that enhance the discovery of tumors within pelvic organs and their dissemination into adjacent pelvic fat.

Preliminary reports of the use of magnetic resonance imaging of pelvic and abdominal disease are now available.¹⁰⁻¹² Early results are promising and magnetic resonance may be superior to conventional techniques, including CT and ultrasound, for the staging of prostatic and bladder malignancies.¹⁰ The application of magnetic resonance imaging to rectal malignancies has not been described previously. This case illustrates the modality's value for the assessment of local and pelvic nodal spread and the discovery of tumor dissemination beyond the rectum, bladder, or female pelvic organs. The determination of the accuracy of pelvic tumor staging by magnetic resonance imaging is now being evaluated by a prospective study prior to surgery.

References

1. Contreary K, Nancy FC, Becker WF. Primary lymphoma of the gastrointestinal tract. *Ann Surg* 1980; **191**:593-598.
2. Vanden Heule B, Taylor CR, Terry R, Lukes RJ. Presentation of malignant lymphoma in the rectum. *Cancer* 1982; **49**:2602-2607.
3. Bruneton JN, Thyss A, Bourry J, Bidoli R, Schneider M. Colonic and rectal lymphomas. A report of six cases and review of the literature. *ROFO* 1983; **138**:283-287.
4. Allison JG. The role of surgery in the management of lymphoma. *JAMA* 1981; **246**:2843-2848.
5. Filippa DA, Lieberman PH, Weingrad DN, DeCosse JJ, Bretsky SS. Primary lymphomas of the gastrointestinal tract. Analysis of prognostic factors with emphasis on histological type. *Am J Surg Pathol* 1983; **7**:363-372.
6. Dixon AK, Fry IK, Morson BC, Nicholls RJ, Mason AY. Pre-operative computed tomography of carcinoma of the rectum. *Br J Radiol* 1981; **54**:655-659.
7. Megibow AJ, Balthazar EJ, Naidich DP, Bosniak MA. Computed tomography of gastrointestinal lymphoma. *AJR* 1983; **141**:541-547.
8. Thoeni RF, Moss AA, Schnyder P, Margulis AR. Detection and staging of primary rectal and rectosigmoid cancer by computed tomography. *Radiology* 1981; **141**:135-138.
9. Oliver TW Jr, Bernardino ME, Sones PJ Jr. Monitoring the response of lymphoma patients to therapy: correlation of abdominal CT findings with clinical course and histologic cell type. *Radiology* 1983; **149**:219-224.
10. Hricak H, Williams RD, Spring DB, et al. Anatomy and pathology of the male pelvis by magnetic resonance imaging. *AJR* 1983; **141**:1101-1110.
11. Bryan PJ, Butler HE, LiPuma JP, et al. NMR scanning of the pelvis: initial experience with a 0.3 T system. *AJR* 1983; **141**:1111-1118.
12. Buonocore E, Borkowski GP, Pavlicek W, Ngo F. NMR imaging of the abdomen: technical considerations. *AJR* 1983; **141**:1171-1178.

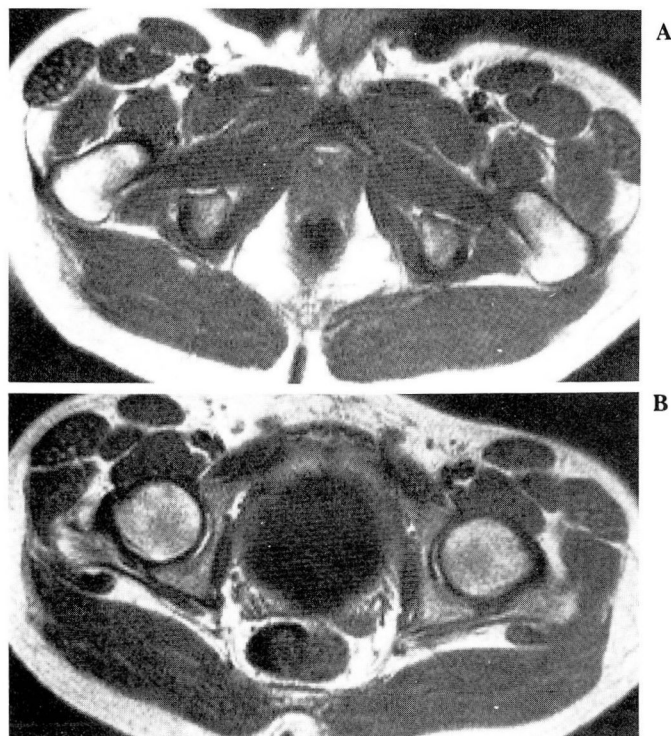


Fig. 4. A and B. Magnetic resonance scans of the pelvis of a normal volunteer. Note the uniform configuration of the rectal wall and the uniform appearance of the peripelvic fat as compared to that seen in the patient in **Figure 3**.