

Pulmonary embolism: a review of 200 cases with emphasis on pathophysiology, diagnosis, and treatment¹

Richard C. Becker, M.D.
Robert Graor, M.D.
John Holloway, M.D.

Pulmonary embolism is not an uncommon occurrence in major medical centers. It is a significant cause of morbidity and mortality in both medical and surgical patients. Clinical and laboratory findings are characteristically nonspecific and may be misleading. Venography, ventilation-perfusion lung scanning, and pulmonary angiography techniques are critical diagnostic tools. Various treatment modalities, including the use of heparin, warfarin, and streptokinase, are available to the physician and often affect both the short- and long-term medical course. The authors review 200 cases evaluated for the effectiveness of diagnostic procedures and methods of treatment for pulmonary embolism at The Cleveland Clinic Foundation.

Index terms: Pulmonary embolism • Review articles

Cleve Clin Q 51:519-529, Fall 1984

¹ Department of Peripheral Vascular Disease, The Cleveland Clinic Foundation. Submitted for publication Feb 1984; revision accepted June 1984. lp

0009-8787/84/03/519/11/\$3.75/0

Copyright © 1984, The Cleveland Clinic Foundation

Pulmonary embolism (PE) continues to be a major cause of morbidity and mortality among the general hospital population. There is evidence that the incidence of PE is increasing as a result of (a) increased life expectancy, particularly in individuals with neoplastic disease; (b) increased use of steroidal compounds; (c) the increased number of extensive surgical procedures; and (d) an increased awareness and diagnosis of PE.¹

The incidence of PE in the United States approaches 650,000 cases per year, 30% of which are fatal.² Unfortunately, an alarming number of cases go undiagnosed. Despite extensive experience and the development of sensitive diagnostic tools, some confusion remains as to the clinical presentation, evaluation, and treatment of PE.

Table 1. Study population

Data	No. of patients (%)
Age	
<50 years	68 (34%)
>50 years	132 (66%)
Sex	
Males	138 (69%)
Females	62 (31%)
Postoperative	144 (72%)
Autopsy	84 (42%)
Oral contraceptives	0 (0%)

We reviewed 200 cases retrospectively and evaluated the effectiveness of diagnostic procedures and methods of treatment for PE at The Cleveland Clinic Foundation.

Methods

Two hundred patients were studied by retrospective chart review. Study population data are described (*Table 1*). Patients were selected on the basis of a diagnosis of PE. Data were collected to determine the most reliable methods of diagnosis and to evaluate the methods used at our institution (ventilation-perfusion scanning, venography, and pulmonary angiography).

Results

The common symptoms of the 200 patients with pulmonary emboli are listed (*Table 2*). Fifty-two patients (26%) were diagnosed clinically as having PE without radiographic documentation to substantiate the diagnosis. One hundred forty-eight patients (74%) had a radiographically diagnosed PE; of these, 62 patients (42%) had ventilation-perfusion lung scans and 48 patients (32%) had perfusion lung scans only. Sixteen patients (11%) underwent pulmonary arteriography. Sixty-two percent of the lung scans were interpreted as indicating a high probability, 16% low probability, and 22% indeterminate for PE. Six patients (2%) diagnosed as having PE had

Table 2. Symptoms of pulmonary embolism

Symptoms	No. of patients (%)
Dyspnea	170 (85%)
Cough	124 (62%)
Chest pain	92 (46%)
Hemoptysis	8 (4%)
Syncope	8 (4%)

only ascending venography to document a source of emboli.

Of the 200 patients studied, 162 patients (81%) were treated with heparin followed by warfarin, 4 patients (2%) were given streptokinase, and 34 patients (17%) had inferior vena caval interruptions.

Forty-eight deaths (24%) occurred. Sixteen (8%) were thought to be directly related to the PE and the remainder died from other causes.

Autopsy was performed on 42 patients (86%). Forty of these patients (95%) had massive PE and 100% had an antemortem diagnosis of suspected PE. Of the 2 patients with submassive pulmonary emboli, 1 had a clinical diagnosis of PE during the antemortem period.

Of the 144 patients in whom PE developed in the postoperative period, 98 patients (68%) had a radiographically documented embolus on either pulmonary angiograms or high-probability perfusion lung scans. The remainder of these patients were clinically diagnosed.

In two patients who underwent lung scanning several days before death, PE was not detected until postmortem examination. The lung scan was interpreted as indicating a low probability two days before one patient's death, and the other was interpreted as indeterminate four days antemortem. The scan indicating low probability was ordered after the abrupt onset of pleuritic chest pain and hypotension. It showed two segmental defects in areas of the chest radiograph abnormalities at both lung bases. At autopsy, there were multiple segmental pulmonary emboli. In retrospect, this patient's scan was reviewed and was again interpreted as revealing a low probability. For the patient with the indeterminate lung scan, pulmonary angiography was recommended and obtained three days before the patient's death. The pulmonary angiogram had been correctly interpreted, leading to a diagnosis of PE.

Discussion

The mortality of undiagnosed PE approaches 30%. Once identified and treated, this figure decreases substantially to less than 10%.³ Such statistics dramatically emphasize the importance of early diagnosis and treatment. The diagnosis, however, is often difficult because of the varying presentation of PE.

Critical to the diagnosis of PE is an awareness that the clinical presentation is an outward man-

ifestation of a series of complex pathophysiological processes that occur following the embolic event.

The significant incidence, high morbidity, and potential mortality of PE in the hospital setting warrant complete understanding of its predisposition, presentation, evaluation, and treatment. The problem should be approached in a swift, logical, and precise manner as in other acute, life-threatening events, such as myocardial infarction, overwhelming sepsis, and the acute abdomen.

Factors predisposing to pulmonary embolism

Approximately 90% of pulmonary emboli originate from thrombi within the deep venous systems of the pelvis and thighs. Exceptions include tumor emboli, air emboli, amniotic fluid emboli, fat emboli, and thrombi originating in the right side of the heart.⁴

The risk of embolization is approximately 40% in patients who have thrombosis proximal to the popliteal vein. Although it is said that calf vein thrombi rarely embolize, almost 20% of these will propagate proximally and then present a more significant risk for embolization.⁵

Risk factors for development of deep venous thrombosis (DVT) include serious illness necessitating prolonged bed rest, such as congestive heart failure; recent myocardial infarction or cerebrovascular accident; recent abdominal, pelvic, thoracic or orthopedic surgery; major trauma; malignancy; polycythemia rubra vera; obesity; sickle cell anemia; pregnancy; and antithrombin III deficiency. Patients more than 40 years of age, particularly those with cardiac disease or a history of previous DVT, also pose a significant risk.^{6,7}

Pathogenesis of venous thrombosis

In 1858, Virchow⁸ stated that venous thrombosis resulted from a triad of underlying conditions: (a) stasis of blood flow, (b) injury to the blood vessel wall, and (c) a hypercoagulable state.

Stasis of blood flow is considered the most important risk factor, particularly in operative patients. In this setting, the velocity of venous blood flow in the lower extremities is reduced with the induction of general anesthesia. This fact supports the theory that most DVT begin to develop intraoperatively. The reduction of venous flow persists during the postoperative period and may continue for weeks if the patient remains at bed rest.^{9,10} The initiating mechanism

for thrombus formation is the stagnant blood flow itself, which allows substances such as fibrin, thrombin, and intrinsic coagulation factors to remain in close contact with platelets for a critical length of time. Platelets are then stimulated to produce prostaglandins, which induce further aggregation and subsequent clot formation.^{11,12}

The effect of direct injury to the vascular endothelial surface has been studied extensively. Following intimal damage, zeta potential changes and exposure of collagen strands promote platelet aggregation and degranulation with release of adenosine diphosphate (ADP) and thromboxane A₂. Both substances induce further platelet aggregation at the site of injury.¹³

The "hypercoagulable state" often referred to in connection with neoplasia, oral contraceptives, blood dyscrasias, old age, and obesity is not fully understood. It is thought to be secondary to a combination of factors including hyperviscosity, stasis of blood flow, elevated coagulation factors and "tissue substances," which are capable of both activating the Hageman factor (factor XII) and stimulating platelet aggregation, the end result being thrombus formation.¹⁴

Clinical manifestations of pulmonary embolism

The classic presentation of massive PE with severe circulatory compromise should not pose a diagnostic dilemma. However, the majority of patients who experience PE have nonspecific signs and symptoms.

The clinical presentation of PE can be grouped into three categories, based on the degree of vascular compromise:

1. Submassive without infarction,
2. Submassive with infarction, and
3. Massive with acute right heart failure (cor pulmonale).

Submassive PE without infarction may cause only mild dyspnea, tachycardia, and low-grade fever. Patients with pulmonary infarction commonly experience pleuritic pain, dyspnea, and hemoptysis. In acute cor pulmonale cyanosis, dyspnea, right heart failure, and cardiogenic shock rapidly ensue.

The urokinase-streptokinase PE trials, while not designed to study the diagnosis of PE, provide substantial clinical data.^{15,16} The following symptoms and signs were noted by patients subsequently diagnosed angiographically as having suffered an acute PE: chest pain (88%), apprehension (59%), and dyspnea (84%). Nonproductive

Table 3. Electrocardiographic findings in pulmonary embolism (in order of descending frequency)

Sinus tachycardia
T-wave inversion
ST segment depression
Low voltage in frontal plane
S ₁ Q ₃ T ₃ pattern
ST segment elevation
Complete right bundle branch block
Left axis deviation
Premature ventricular contractions
Normal
P pulmonale
Right axis deviation
Premature atrial contractions
Atrial fibrillation

cough, hemoptysis, sweats, and palpitations were present in variable degrees. Fever, changes in the pulmonic component of the second heart sound, and nonspecific findings on auscultation of the lungs were common physical signs. A respiratory rate >16 breaths/min was noted in 93% of the patients and >30 breaths/min in 25%.

Changes in laboratory values are common in acute PE and include an elevation in sedimentation rate, white blood count, lactate dehydrogenase (LDH), serum bilirubin, and fibrin split products. Such findings, however, are nonspecific and rarely influence the diagnosis.

Pathophysiology of pulmonary embolism

Obstruction of the pulmonary arteries by an embolus affects the pulmonary circulation, bronchial circulation, the airways, and the function of the right and left sides of the heart.

The degree of hemodynamic compromise correlates with the degree of arterial obstruction in patients without preexisting cardiopulmonary disease. However, in patients with underlying heart or lung disease, severe pulmonary hypertension and cardiovascular collapse may occur with submassive obstruction and occasionally following small peripheral embolism.¹⁷

The reduction in blood flow following pulmonary artery occlusion leads to an increase in total pulmonary vascular resistance. The pressure in the right ventricle must increase in order to maintain constant blood flow. This increase in work load may result in right-side heart failure since the right ventricular muscle is thin and is not designed to tolerate high pressure loads. A

compensatory mechanism for increased right ventricular work begins early following pulmonary artery obstruction. This is an intrinsic autoregulation of the coronary arteries, which results in an increase in selective right coronary artery blood flow and a twofold to threefold increase in right ventricular myocardial blood flow. Such a compensatory mechanism obviously would be blunted in the presence of underlying coronary artery disease.

The role of "reflex mechanisms" resulting from pulmonary artery occlusion has received a great deal of attention in the literature. It is believed that platelet degranulation accompanied by the release of serotonin, histamine, catecholamines, and prostaglandins results in both bronchial and pulmonary arteriolar constriction. This increases total pulmonary vascular resistance, thereby potentiating ventilation-perfusion mismatching. Platelet-released mediators also stimulate intrinsic pulmonary bronchiolar mechanisms, such as the Hering-Breuer reflex, which contribute to the dyspnea and tachypnea often observed in PE.¹⁸

The cause of acute hypoxia is not well defined. Alveolar hypoventilation, intrapulmonary shunting, decreased diffusion capacity, and alveolar collapse secondary to a reduction in surfactant may all contribute.^{19,20}

Diagnostic evaluation

The major objective of a diagnostic evaluation is to confirm or exclude the presence of PE as quickly and efficiently as possible. The following basic diagnostic tests should be performed: (a) electrocardiogram (ECG), (b) chest radiograph, and (c) arterial blood gas analysis.

Electrocardiogram. The ECG is neither a specific nor a sensitive indicator of PE. Sinus tachycardia is the most common abnormality seen on the ECG. Atrial fibrillation may occur as well as varying types of heart block. Right axis deviation resulting from acute right ventricular dilatation may be seen, as well as Q waves in lead 3. ST segment changes and T-wave inversions are common (Table 3).

Radiographic findings. There are no pathognomonic radiographic signs in acute PE. As with the ECG, changes may be encountered and, given the appropriate clinical setting, may be of help in making the correct diagnosis. Radiographic evidence of pulmonary infarction was first described by Hampton and Castleman²¹ in 1940 following

postmortem radiograph and lung necropsy correlations. "Hampton's hump" classically represents a wedge-shaped area in infarction with the base lying along a pleural surface (parietal, diaphragmatic, mediastinal, or outer lobar) and apex at the site of the embolus, usually pointing toward the hilum. In reality, however, this classic finding is rare because most infarctions are incomplete, with the consolidation involving the base of the wedge (pleural surface) only. In this setting, the shadow cast is semispherical rather than triangular and resolves within one to three weeks as the extravasated blood is resorbed.²²

Other radiographic findings described in PE include (a) elevation of the hemidiaphragm (on the involved side), (b) hyperemia in nonaffected lung fields, (c) enlargement of the hilar shadow, and (d) unilateral or bilateral pleural effusions. Less common findings are dilatation of the superior vena cava, lobar collapse, pulmonary edema, and right ventricular enlargement. It is important to keep in mind that a normal chest radiograph *does not* exclude the diagnosis of PE. In fact, up to 15% of massive pulmonary emboli, including those which result in major hemodynamic compromise, have normal chest radiographs.²³

Arterial blood gas. At one time it was thought that a normal partial pressure of oxygen within arterial blood (PaO_2) virtually eliminated the diagnosis of acute PE. However, clinical studies have shown that 5% of patients experiencing PE have a $\text{PaO}_2 > 90$ Torr and 15% have a $\text{PaO}_2 > 80$ Torr.²⁴

Lung scanning. Although clinical, radiographic, and laboratory findings are suggestive of acute PE, perfusion lung scanning is necessary in establishing a diagnosis. Imaging in the anterior, posterior, right lateral, left lateral, right posterior oblique, and left posterior oblique views effectively demonstrates regional pulmonary blood flow. If multiple views fail to show perfusion defects, PE is highly unlikely, and diagnostic efforts to determine PE may be reduced or abandoned (Fig. 1).

The ventilation scan adds specificity to lung scanning, using xenon-133, which when inhaled, distributes itself evenly throughout the lungs. A "first breath" view, equilibrium view, and washout view are obtained. A normal ventilation scan projects a uniform distribution of gas in the wash-in and equilibrium phases and a uniform washout from all lung fields. In PE, an area that is abnor-

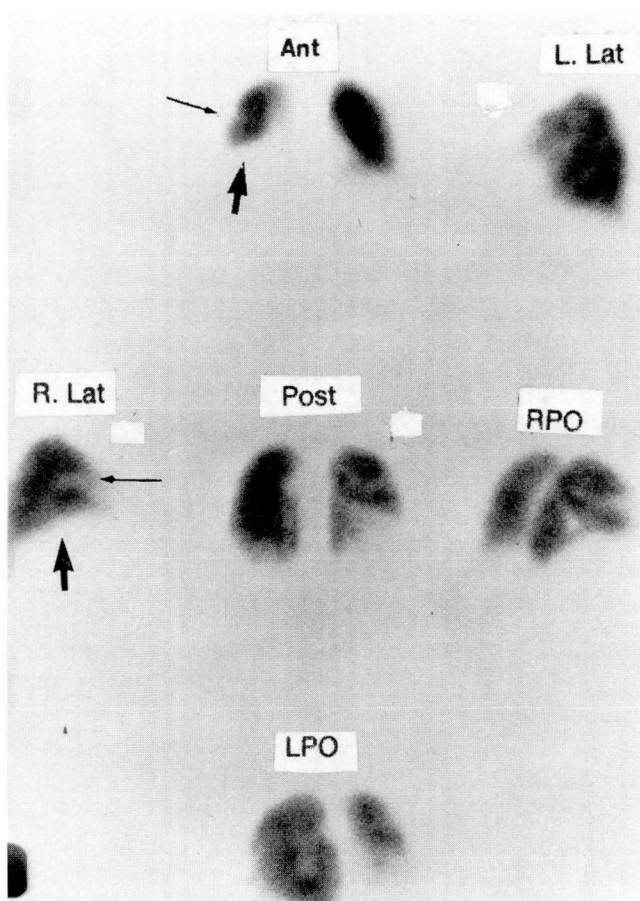


Fig. 1. Abnormal lung perfusion scan showing segmental (small arrow) and lobar (large arrow) perfusion defects in the right lung.

Table 4. Ventilation-perfusion lung scanning probability of diagnosis^{47,48}

Probability	Ventilation-perfusion (V/Q) findings
Low	<ul style="list-style-type: none"> — V/Q matching defect — Small subsegmental defects with mismatch — Perfusion defect smaller than chest radiograph abnormality
Indeterminate	<ul style="list-style-type: none"> — Multiple segmental defects with mismatch and match — Single segmental defect with mismatch — Perfusion defect equal to chest radiograph abnormality
High	<ul style="list-style-type: none"> — Multiple segmental or lobar defects with mismatch — Perfusion defect much larger than chest radiograph abnormality
Normal	<ul style="list-style-type: none"> — Normal chest radiograph, normal ventilation and perfusion scan

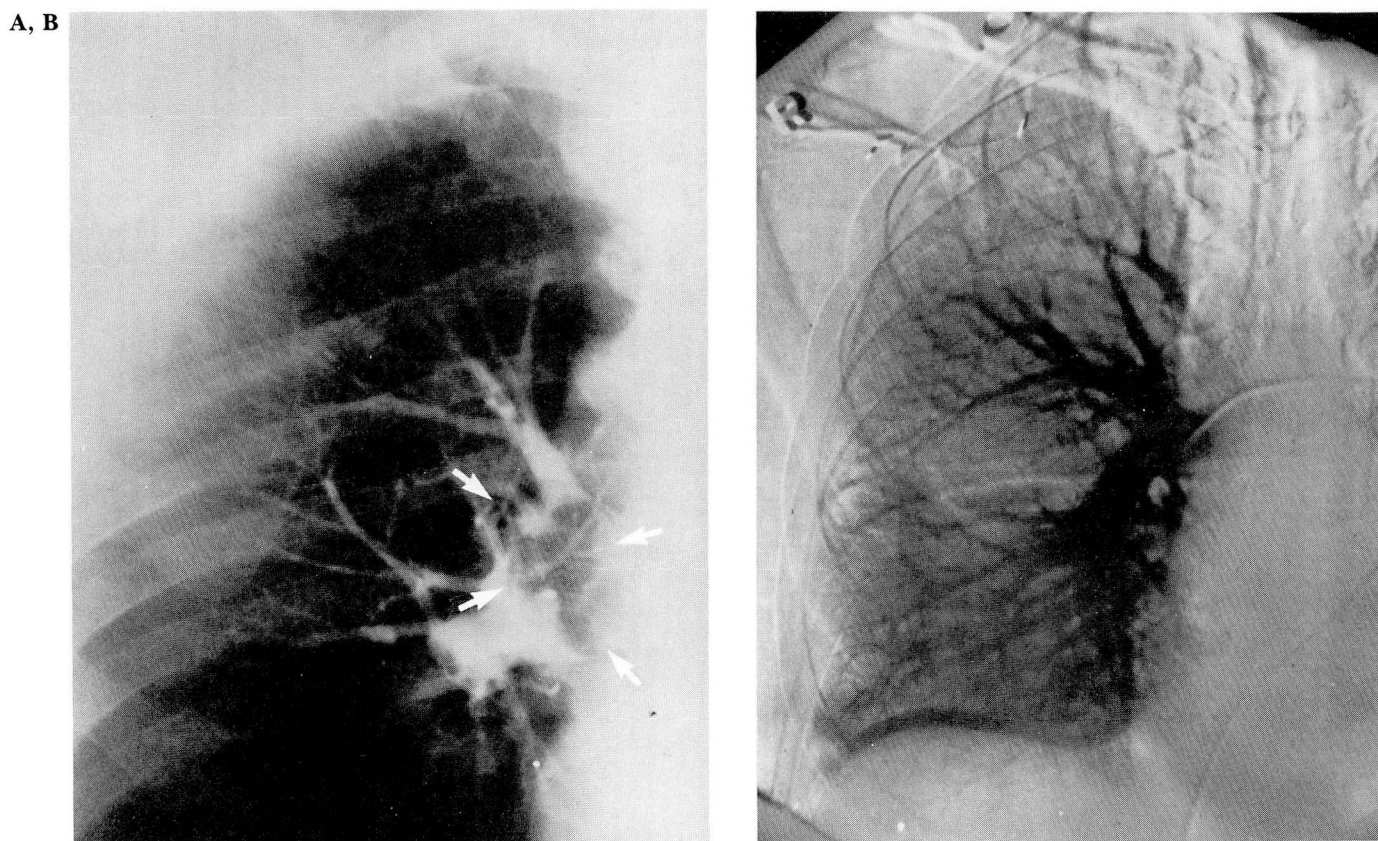


Fig. 2. A. Selective right pulmonary artery angiogram, showing a large pulmonary embolus.
B. Repeat subtraction selective angiogram following administration of intraarterial streptokinase, showing clot lysis and resumption of normal blood flow.

mally perfused will usually be normally ventilated. This is referred to as a ventilation-perfusion (V/Q) mismatch. Disorders such as chronic obstructive pulmonary disease, pulmonary infiltrates, tumors, granulomatous diseases, and primary lung disease may have perfusion scan abnormalities. However, they are usually accompanied by areas of abnormal ventilation as well (V/Q match).

The diagnosis of PE can be determined with high probability, based on ventilation-perfusion scan findings (*Table 4*).

Angiography. Selective pulmonary angiography is the definitive test by which PE can be diagnosed. Positive signs are a sharp cutoff of the artery filled with contrast material and/or an intravascular filling defect (*Fig. 2, A and B*). Angiography is particularly useful when: (a) there are perfusion defects that match radiographic abnormalities; (b) there are multiple perfusion defects, some normally ventilated, some not; (c) there is a history of unconfirmed pulmonary em-

boli in a patient with an indeterminate lung scan; and (d) there is massive embolism necessitating surgical or fibrinolytic intervention. In addition, pulmonary angiography may help differentiate recurrent embolism from embolus fragmentation with distal migration.

Pulmonary artery and pressures of the right side of the heart can be obtained during pulmonary angiography. These values are useful in determining the magnitude of the hemodynamic disturbance caused by the PE. In patients with preexisting cardiopulmonary disease, the interpretation of these values may be difficult.

Treatment of pulmonary embolism

When PE is suspected, initial therapy should be directed toward stabilizing the patient and initiating anticoagulation.

Heparin therapy. Heparin is the anticoagulant of choice for the treatment of acute PE. Unless contraindicated, it should be given immediately to all patients suspected of having PE before

diagnostic testing. Heparin is the ideal agent for initial treatment because its onset of action is immediate and it is rapidly metabolized.²⁵

Heparin's major effect is the inhibition of the coagulation cascade, thereby preventing further thrombus formation, propagation, and embolization. The body's intrinsic thrombolytic system may then dissolve the thrombus or allow it to become organized and firmly adherent to the vessel wall.²⁶

The usual initial dosage is 500 U/kg daily, given as a continuous intravenous infusion. A baseline partial thromboplastin time (PTT) is obtained before beginning therapy and the dose of heparin is adjusted to maintain the PTT 1½–2 times the baseline value. A loading dose of 10,000 units (150 U/kg) given intravenously is used in the patient with massive PE or when there will be a delay in instituting a continuous infusion.

Hemorrhage is the major side effect of heparin.²⁷ Patients at highest risk include the elderly, those with underlying coagulopathy, those recently having undergone surgery, and individuals with significant hepatic dysfunction. Heparin-induced thrombocytopenia is an uncommon immune phenomenon.^{28,29}

Warfarin therapy. Warfarin sodium (Coumadin) is the prototype of a class of drugs that inhibits the hepatic synthesis of the vitamin K-dependent coagulation factors II, VII, IX, and X, thereby preventing thrombin formation. It is administered one or two days after the institution of heparin therapy. The starting dose is 10 mg/day by mouth and is adjusted to maintain the prothrombin time at twice normal. The daily dose required varies, depending upon concomitant medical illness and other drug ingestion (Table 5). Three months is the usual length of time that warfarin is continued following PE. Beyond three months, the risk of bleeding usually outweighs the benefit.^{30,31}

It is important that heparin therapy be continued during the first four to five days of warfarin therapy to assure a state of anticoagulation while adequate depletion of all vitamin K-dependent factors is taking place.³²

Thrombolytic therapy. In the patient with respiratory or hemodynamic compromise caused by PE, thrombolytic therapy should be considered. This is the only treatment available that promotes actual lysis of thrombus, thereby restoring normal pulmonary circulation. Currently, two drugs are available: streptokinase and urokinase. Streptokinase acts by combining with plasminogen to form an activator substance, which indirectly converts plasminogen to plasmin, thereby promoting fibrin degradation and clot lysis. Urokinase acts directly on plasminogen to yield the same results.^{33,34}

Table 5. Factors affecting coagulation response to Coumadin

Increased response	
Liver disease	Diuretics
Neoplasia	Nonsteroidal anti-inflammatory agents
Congestive heart failure	Quinidine
Antibiotics	Oral hypoglycemics
Decreased response	
Diabetes mellitus	Oral contraceptives
Hyperlipidemias	Barbiturates
Hypothyroid state	Vitamin K administration
Antacids	Vitamin C (excessive)
Antihistamines	

Streptokinase or urokinase may be directly infused into the involved pulmonary artery via a catheter inserted through either a femoral or brachial vein. This approach may produce more rapid clot lysis, and further, monitoring progress with repeated pulmonary angiograms can be easily accomplished. When clot lysis is confirmed, the catheter is removed and the patient is treated with conventional intravenous and oral anticoagulants. Guidelines to thrombolytic therapy are outlined (Table 6).

Inferior vena cava interruption therapy. Occasionally, a patient who has had a PE and has a contraindication to anticoagulation or who embolizes while receiving adequate anticoagulation may require inferior vena cava interruption with a caval filter or by ligation.^{35–39} This provides protection from further embolic episodes. However, it does not treat the pulmonary embolus itself or the underlying thrombotic process. A risk (3%–5%) of thrombus extension causing inferior vena cava thrombosis with embolization from above the umbrella exists. Inferior vena cava thrombosis may result in severe chronic venous insufficiency.^{40–44}

Pulmonary embolectomy. Surgical removal of massive pulmonary emboli can be lifesaving in patients with shock who have been refractory to medical management. The surgery depends upon angiographic documentation of the embolus and the availability of an experienced cardiothoracic surgical team.^{45,46}

Table 6. Guidelines for thrombolytic therapy

I. Patient selection	
1.	Diagnosis of pulmonary embolism
2.	Duration of symptoms, 7 days
3.	Cardiopulmonary compromise
4.	Contraindications
A. Absolute	
—	Active internal bleeding
—	Recent (within 2 months) cerebrovascular accident or other active intracranial process. There is evidence that currently used thrombolytic regimens carry the hazard of inducing cerebral hemorrhage in those with a recent history of stroke. (However, studies are currently underway using lower dosage for the treatment of stroke.)
B. Relative	
Major	
—	Recent (<10 days) major surgery, obstetrical delivery, organ biopsy, previous puncture of noncompressible vessels
—	Recent serious gastrointestinal bleeding
—	Recent serious trauma
—	Severe arterial hypertension (≥ 200 systolic or ≥ 110 diastolic)
Minor	
—	Recent minor trauma, including cardiopulmonary resuscitation
—	High likelihood of a left heart thrombus, e.g., mitral valve disease with atrial fibrillation
—	Bacterial endocarditis
—	Hemostasis defects, including those associated with severe hepatic or renal disease
—	Pregnancy
—	Age: >75 years
—	Diabetic hemorrhagic retinopathy
II. Drug administration	
Loading dose: streptokinase (250,000 units IV for 20–30 min)	
urokinase (4,400 units/kg IV for 10 min)	
Maintenance: streptokinase (100,000 U/hr for 48–72 hr)	
urokinase (4,400 U/kg/hr for 12–24 hr)	
III. Monitoring	
Thrombin time: $1\frac{1}{2}$ times normal	
Fibrinogen level: <200 mg/100 mL	
If lytic state is not achieved in 4 hr, reload and continue infusion as indicated. When lytic state is achieved, obtain clotting parameters once or twice daily.	
IV. Complications	
1.	Major bleeding requiring cessation of therapy (<5%)
2.	Febrile reaction (streptokinase) (20%)
3.	Allergic cutaneous reaction (streptokinase) (<1%)
V. Treatment of complications	
1.	Bleeding: minimize invasive procedures
	compression dressings
2.	Major bleeding: discontinue infusion
	fresh frozen plasma/RBC transfusion
3.	Febrile/skin rash: hydrocortisone (100 mg IV)
	diphenhydramine (50 mg IV)

IV = intravenous.

Prevention. Death from a PE in a patient who has otherwise undergone successful surgical or medical treatment is tragic. Prophylactic measures are available that decrease the incidence of deep vein thrombosis and subsequent emboliza-

tion. Heparin (5,000 units) given subcutaneously every 12 hours inactivates factor X, thereby preventing thrombus formation. The efficacy of this regimen has proved effective in patients with heart disease, stroke, neoplasia, and in those >40

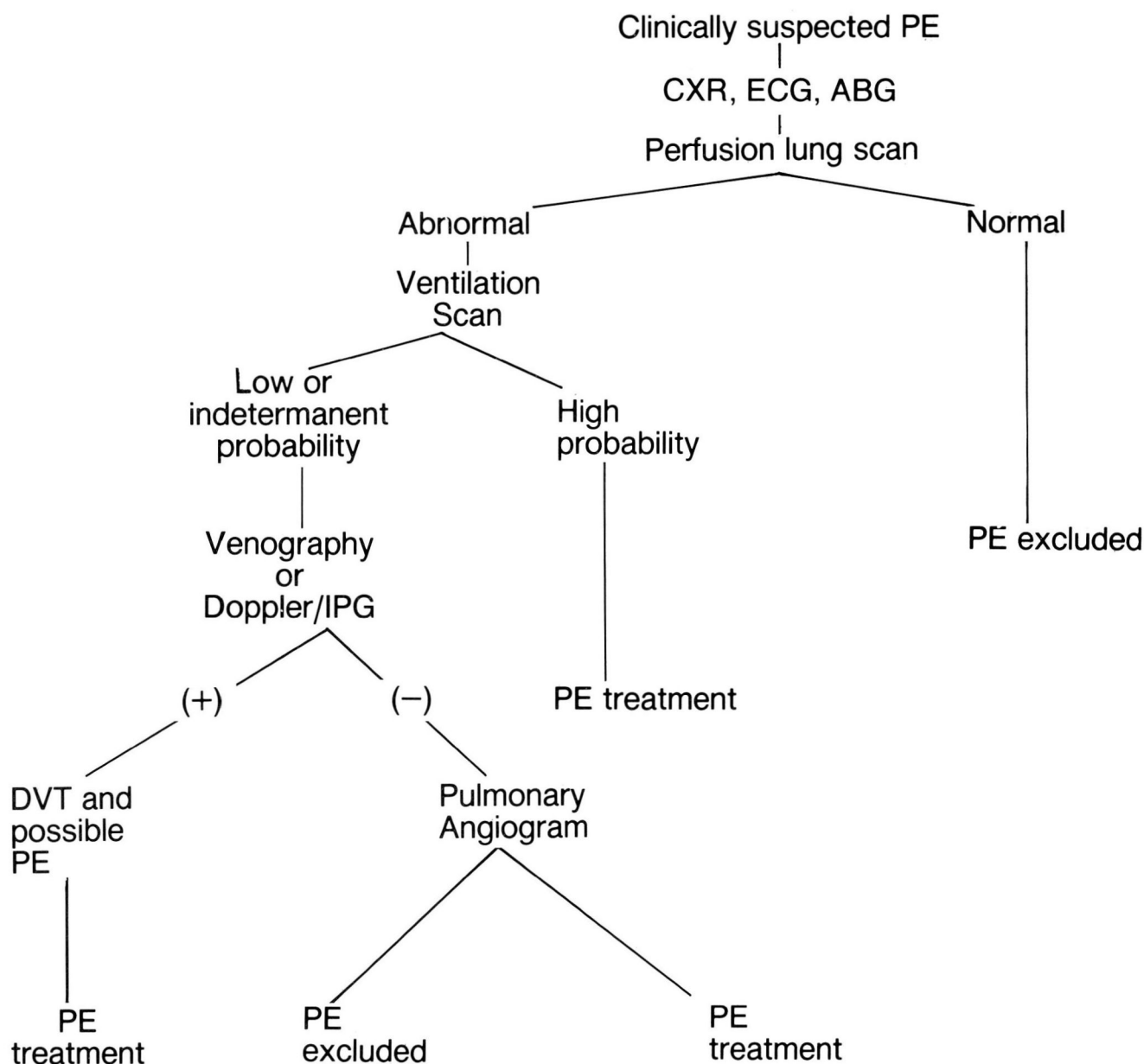


Fig. 3. Algorithm for diagnosing PE.

years of age undergoing thoracic or abdominal surgery. Patients undergoing major orthopedic or urologic surgery are not protected by low-dose heparin therapy.⁴⁹ Intermittent compression stockings alone or combined with low-molecular weight dextran⁵⁰ or low-dose warfarin seem to be effective prophylactic measures in these patients.⁵¹ When anticoagulation is contraindicated, such as in neurosurgical or ophthalmological procedures, intermittent compression stockings may be effective.

Other methods of prophylaxis are available and include adjusted doses of heparin,^{52,53} heparin and dihydroergotamine, continuous passive motion devices, and antiplatelet agents such as aspirin.

Conclusion

The mortality of undiagnosed PE approaches 30%. Short- and long-term morbidity exceeds this figure. Our retrospective review of patients diagnosed as having suffered a PE while hospi-

talized at The Cleveland Clinic Foundation emphasize that the approach to evaluating a patient suspected of having a PE must be logical, precise, and systematic (*Fig. 3*).

In summary, PE is common in the hospital setting. Most emboli originate from thrombi within the deep veins of the pelvis and lower extremities. The presentation of PE may be non-specific or classic with chest pain, dyspnea, hemoptysis, and hemodynamic compromise. PE should always be considered in a patient at risk with unexplained cardiopulmonary signs and symptoms. The approach to diagnosis should be prompt and systematic, using ventilation-perfusion lung scanning and pulmonary angiography when indicated. Early treatment significantly affects morbidity and mortality.

Robert Graor, M.D.

Department of Peripheral

Vascular Disease

The Cleveland Clinic Foundation

9500 Euclid Ave.

Cleveland OH 44106

References

- Rosenow EC III, Osmundson PJ, Brown L. Pulmonary embolism. *Mayo Clin Proc* 1981; **56**:161-178.
- Dalen JE, Alpert JS. Natural history of pulmonary embolism. *Prog Cardiovasc Dis* 1975; **17**:259-270.
- Barritt DW, Jordan SC. Anticoagulant drugs in the treatment of pulmonary embolism: a controlled trial. *Lancet* 1960; **1**:1309-1312.
- Satiani B. Management of acute deep vein thrombosis. *Am Fam Physician* 1982; **25**:103-109.
- Moser KM, LeMoine JR. Is embolic risk conditioned by location of deep venous thrombosis? *Ann Intern Med* 1981; **94**:439-444.
- Maurer BJ, Wray R, Shillingsford JP. Frequency of venous thrombosis after myocardial infarction. *Lancet* 1971; **2**:1385-1387.
- Harvey-Kemle JV. Incidence of deep vein thrombosis. *Br J Hosp Med* 1971; **6**:721-726.
- Virchow R. Cellular pathology as based upon physiological and pathological histology. Translated from 2nd ed. London, John Churchill, 1860.
- Allison PR. Pulmonary embolism and thrombophlebitis. *Br J Surg* 1967; **54**:466-470.
- Browse NL. Effect of surgery on resting calf blood flow. *Br Med J* 1962; **1**:1714-1721.
- Moncada S, Higgs EA, Vane JR. Human arterial and venous tissues generate prostacyclin (prostaglandin X), a potent inhibitor of platelet aggregation. *Lancet* 1977; **1**:18-20.
- Moncada S, Vane JR. Pharmacology and endogenous roles of prostaglandin endoperoxides, thromboxane A₂, and prostacyclin. *Pharmacol Rev* 1979; **30**:293-332.
- Du P Heyns A, Badenhorst CJ, Retief FP. A stable non-prostaglandin inhibitor of platelet aggregation in human aorta intima extracts. *S Afr Med J* 1979; **55**:908-912.
- Henderson ES, Rapaport SI. The thrombotic activity of activation product. *J Clin Invest* 1962; **41**:235-240.
- A cooperative study. Urokinase pulmonary embolism trial, phase 1 results. *JAMA* 1970; **214**:2163-2172.
- A cooperative study. Urokinase-streptokinase embolism trial, phase 2 results. *JAMA* 1974; **229**:1606-1613.
- Nelson JR, Smith JR. The pathologic physiology of pulmonary embolism: a physiologic discussion of the vascular reactions following pulmonary arterial obstruction by emboli of varying size. *Am Heart J* 1959; **58**:916-932.
- Widdicombe JG. Reflex mechanisms in pulmonary thromboembolism. [In] Moser KM, Stein M, eds. *Pulmonary Thromboembolism*. Chicago, Year Book Medical Publishers, 1973.
- Stein M, Hirose T, Yasutkat, Tarabeih A. Airways response to pulmonary embolism: pharmacologic aspects. [In] Moser KM, Stein M, eds. *Pulmonary Thromboembolism*. Chicago, Year Book Medical Publishers, 1973.
- Jardin F, Gurdjian F, Desfonds P, Fouilladieu JL, Margairaz A. Hemodynamic factors influencing arterial hypoxemia in massive pulmonary embolism with circulatory failure. *Circulation* 1979; **59**:909-912.
- Hampton AO, Castleman B. Correlation of postmortem chest teleroentgenograms with autopsy findings, with special reference to pulmonary embolism and infarction. *AJR* 1940; **43**:305-326.
- Chang CH. Radiological considerations in pulmonary embolism. *Clin Radiol* 1967; **18**:301-309.
- Kerr IH, Simon G, Sutton GC. The value of the plain radiograph in acute massive pulmonary embolism. *Br J Radiol* 1971; **44**:751-757.
- McIntyre KM, Sasabara AA. Determinations of cardiovascular responses to pulmonary embolism. [In] Moser KM, Stein M, eds. *Chicago, Year Book Medical Publishers, 1973*.
- Sasabara AA. Therapy for pulmonary embolism. *JAMA* 1974; **229**:1795-1798.
- Genton E, Hirsh J. Observations in anticoagulant and thrombolytic therapy in pulmonary embolism. *Prog Cardiovasc Dis* 1975; **17**:335-343.
- Kelton JG, Hirsh J. Bleeding associated with antithrombotic therapy. *Semin Hematol* 1980; **17**:259-291.
- Bell WR, Royall RM. Heparin-associated thrombocytopenia: a comparison of three heparin preparations. *N Engl J Med* 1980; **303**:902-907.
- Powers PJ, Cuthbert D, Hirsh J. Thrombocytopenia found uncommonly during heparin therapy. *JAMA* 1979; **241**:2396-2397.
- Thomas DP. Heparin in the prophylaxis and treatment of venous thromboembolism. *Semin Hematol* 1978; **15**:1-17.
- Brozović M. Oral anticoagulants in clinical practice. *Semin Hematol* 1978; **15**:27-34.
- Gurewich V. Guidelines for the management of anticoagulant therapy. *Semin Thromb Hemostas* 1976; **2**: 176-196.
- Sherry S, Lindemeyer RI, Fletcher AP, Alkjaersig N. Studies on enhanced fibrinolytic activity in man. *J Clin Invest* 1959; **38**:810-822.
- Sherry S, Fletcher AP, Alkjaersig N. Fibrinolysis and fibrinolytic activity in man. *Physiol Rev* 1959; **39**:343-382.
- Bergan JJ, Trippel OH. Vena cava operations for prevention of pulmonary embolism. *Surg Clin North Am* 1966; **46**:195-207.
- Wheeler CG, Thompson JE, Austin DJ, Patman RD, Stockton RL. Interruption of the inferior vena cava for thromboem-

- bolism: comparison of ligation and plication. *Ann Surg* 1966; **163**:199–204.
37. Mobin-Uddin K, Callard GM, Bolooki H, Rubinson R, Michie D, Jude JR. Transvenous caval interruption with umbrella filter. *N Engl J Med* 1972; **286**:55–58.
 38. Silver D, Sabiston DC Jr. The role of vena caval interruption in the management of pulmonary embolism. *Surgery* 1975; **77**:1–10.
 39. Greenfield LJ, Zocco JJ. Intraluminal management of acute massive pulmonary thromboembolism. *J Thorac Cardiovasc Surg* 1979; **77**:402–410.
 40. Gurewich V, Thomas DP, Rabinov KR. Pulmonary embolism after ligation of the inferior vena cava. *N Engl J Med* 1966; **274**:1350–1354.
 41. Piccone VA Jr, Vidal E, Yarnoz M, Glass P, LeVeen HH. The late results of caval ligation. *Surgery* 1970; **68**:980–998.
 42. Wingerd M, Bernhard VM, Maddison F, Towne JB. Comparison of caval filters in the management of venous thromboembolism. *Arch Surg* 1978; **113**:1264–1271.
 43. Donaldson MC, Wirthlin LS, Donaldson GA. Thirty-year experience with surgical interruption of the inferior vena cava for prevention of pulmonary embolism. *Ann Surg* 1980; **191**:367–372.
 44. Stewart JR, Greenfield LJ. Transvenous vena caval filtration and pulmonary embolectomy. *Surg Clin North Am* 1982; **62**:411–430.
 45. Gifford RW, Groves LK. Limitations in the feasibility of pulmonary embolectomy: a clinicopathologic study of 101 cases of massive pulmonary embolism. *Circulation* 1969; **39**:523–530.
 46. Sabiston DC Jr, Wolfe WG. Pulmonary embolectomy. [In] Moser KM, Stein M, eds. *Pulmonary Thromboembolism*. Chicago, Year Book Medical Publishers, 1973.
 47. McNeil BJ. A diagnostic strategy using ventilation-perfusion studies in patients suspect for pulmonary embolism. *J Nucl Med* 1976; **17**:613–616.
 48. McNeil BJ. Ventilation-perfusion studies and the diagnosis of pulmonary embolism: concise communication. *J Nucl Med* 1980; **21**:319–323.
 49. Hampson WG, Harris FC, Lucas HK, et al. Failure of low-dose heparin to prevent deep-vein thrombosis after hip-replacement arthroplasty. *Lancet* 1974; **2**:795–797.
 50. Nicolaides AN, Fernandes e Fernandes J, Pollock AV. Intermittent sequential pneumatic compression of the legs in the prevention of venous stasis and postoperative deep venous thrombosis. *Surgery* 1980; **87**:69–75.
 51. Hull R, Delmore T, Carter C, et al. Adjusted subcutaneous heparin versus warfarin sodium in the long-term treatment of venous thrombosis. *N Engl J Med* 1982; **306**:189–194.
 52. Leyvraz PF, Richard J, Bachmann F, et al. Adjusted versus fixed-dose subcutaneous heparin in the prevention of deep-vein thrombosis after total hip replacement. *N Engl J Med* 1983; **309**:954–958.
 53. Harris WH, Salzman EW, Athanasoulis C, Waltman AC, Baum S, DeSanctis RW. Comparison of warfarin, low-molecular-weight dextran, aspirin, and subcutaneous heparin in prevention of venous thromboembolism following total hip replacement. *J Bone Joint Surg* 1974; **56-A**:1552–1562.