

# Leukemia cutis presenting as a chronic herpes zoster ulceration<sup>1</sup>

Jerry F. Mikesell, M.D.  
Philip L. Bailin, M.D.  
Wilma F. Bergfeld, M.D.

**A 75-year-old white man with leukemia had a persistent herpes zoster ulceration with biopsy-specimen evidence of B-cell leukemic infiltrate. Leukemia should be considered in patients with persistent, nonhealing herpes zoster ulceration.**

**Index terms:** Dermatology features • Herpes zoster • Leukemia

**Cleve Clin Q** 51:667-669, Winter 1984

Herpes zoster has long been recognized as a frequent manifestation of lymphoreticular disease. The reported incidence of herpes zoster in patients with hematological neoplasia varies from 2.0% to 15.4%.<sup>1</sup> Leukemic infiltrations of zoster scars can occur, but are rare. Nonspecific skin ulcerations may occur in patients with leukemia with no predilection for the site of previous skin disease.

This is a case report describing the development of a leukemic infiltration in a chronic ulceration of herpes zoster. Ten reported cases of leukemic infiltrates and herpes zoster scars presented as papules, nodules, plaques, or milia.<sup>2</sup> Our patient had ulcerative skin disease.

<sup>1</sup> Department of Dermatology, The Cleveland Clinic Foundation. Submitted for publication and accepted Aug 1984. sb

0009-8787/84/04/0667/03/\$1.75/0

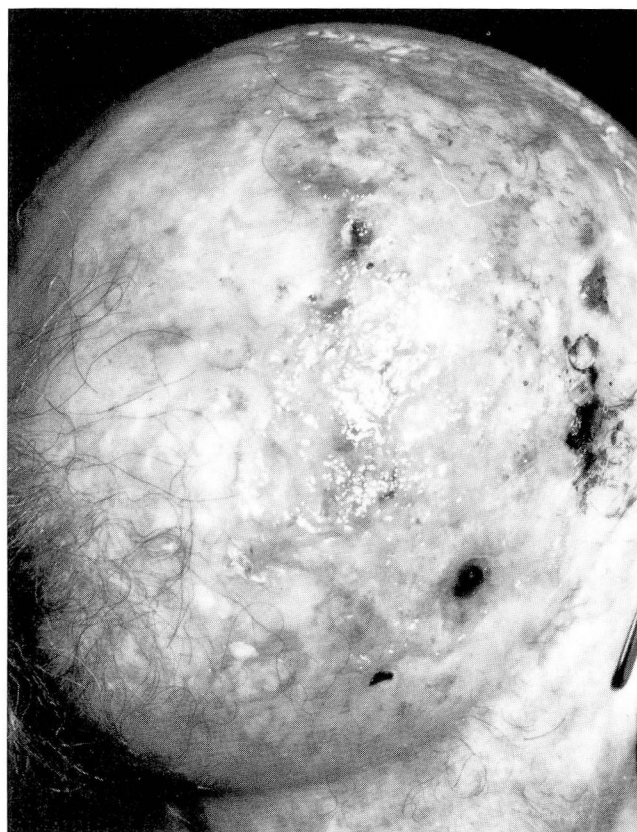
Copyright © 1984, The Cleveland Clinic Foundation

## Case report

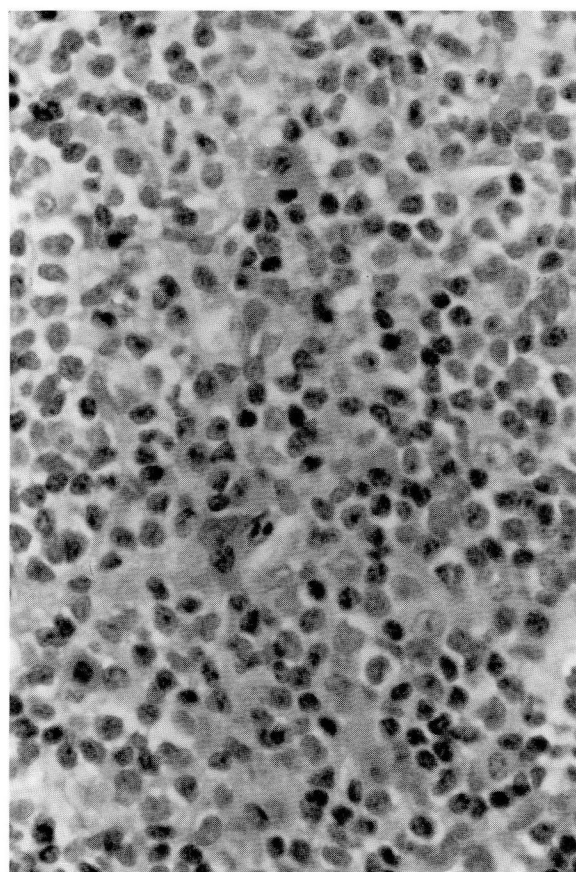
A 75-year-old white man was referred to The Cleveland Clinic Foundation in March 1983 with a 1½-year history of a nonhealing scalp ulceration. Since 1973, the diagnosis had been chronic lymphocytic leukemia. He was treated and subsequently maintained on chlorambucil. In September 1981, herpes zoster developed on the right sides of his scalp, neck, and face in the distribution of the facial nerve, with resultant ulceration of the right side of the scalp. The area failed to heal despite multiple therapies and surgical debridement. In March 1982, a histological examination of the ulceration revealed extensive, mature, lymphocytic infiltrate consistent with chronic lymphocytic leukemia cutis, for which he received local radiation with 1,800 rads divided over six treatments. After debridement and radiation, the ulcer still failed to heal. In November 1982, he received acyclovir intravenously for possible chronic herpes zoster infection. This produced no clinical response. While hospitalized, he was noted to have a left pulmonary mass as shown on the chest radiograph; tissue examination revealed squamous cell carcinoma which was treated by resection of his left lung.

On physical examination at The Cleveland Clinic Foundation, a thick crust covered a superficial ulcer (12.5 × 6.5 cm) on the right parieto-occipital area of the scalp. The ulcer was surrounded by erythema and scaling (*Fig. 1*). Hypopigmented scars were present on the right side of the neck and on the right cheek in the site of the previous herpes zoster infection. The remainder of the physical examination was normal except for marked enlargement of the spleen and decreased breath sounds of the left lung field.

Pertinent laboratory-test values included: white blood cell count, 71,000 with 72% lymphocytes, 9% monocytes, 9% neutrophils, and 3% atypical lymphocytes; hemoglobin, 9.7 g/dL; hematocrit, 30%; and platelets, 120,000. Viral cul-



**Fig. 1.** Superficial ulcers on the right parieto-occipital area of the scalp.



**Fig. 2.** Monomorphic dermal infiltrate composed mainly of mature lymphocytes (hematoxylin-eosin stain; original magnification,  $\times 40$ ).

tures of the ulcer were negative. A computed tomogram of the abdomen showed marked enlargement of the spleen, as well as retroperitoneal lymphadenopathy. There was no evidence of intrahepatic metastatic disease. No masses were shown on the chest radiograph. Diagnostic considerations included a persistent viral ulceration, a chronic nonspecific ulceration, and leukemia cutis in a nonhealing herpes zoster ulceration.

A skin biopsy specimen of the ulcer demonstrated superficial ulcer formation with an acute inflammatory infiltrate. In addition, there was a diffuse, dense, monomorphic dermal infiltrate composed mainly of mature lymphocytes with occasional plasma cells (*Fig. 2*). An active viral process was not evident. Immunohistochemistry stains were kappa positive, lambda negative, T-cell diffuse scant positive, and B1 positive; this is compatible with a B-cell lymphomatous infiltrate.

The patient received two courses of cyclophosphamide, vincristine, and prednisone. His ulcer became smaller, but did not heal. His course was complicated by pleural effusions, pneumonia, and weight loss. White blood counts have been in the range of 40,000.

## Discussion

Cutaneous lesions associated with leukemias have been divided into specific and nonspecific

groups (*Table*).<sup>3</sup> Specific lesions are papules, nodules, or plaques which, based on the histological examination, demonstrate large collections of lymphocytes or lymphoblasts within the dermis and subcutaneous tissue. Leukemic infiltrates of the skin are similar to lymphomatous infiltrates and cannot be distinguished.<sup>4</sup> Nonspecific leukemia lesions are numerous. A histological examination of such nonspecific changes demonstrates a benign, nonspecific infiltrate composed of lymphocytes, plasma cells, and eosinophils in a diffuse pattern throughout the dermis and occasionally in the subcutaneous tissue.

A review of the literature revealed 10 cases in which a leukemic infiltrate developed in the sites of herpes zoster. There was no predilection for a particular dermatome, sex, or race. Most frequently, leukemic infiltrates occurred after the zoster healed.<sup>2</sup> Jadassohn<sup>5</sup> described a 68-year-old man with lymphocytic leukemia and gener-

alized herpes zoster who developed “pea-sized” papules in the zoster scars, which biopsy results revealed to be leukemic infiltrates. Wilkinson<sup>6</sup> described a 52-year-old man with brownish-purple, smooth nodules and plaques within the scars of herpes zoster. Skin biopsy findings revealed a typical leukemic infiltrate. Anhalt and Forsey<sup>7</sup> described papules in healed areas of zoster in a 49-year-old man five months after the herpes zoster had healed.

In patients with impaired cellular immunity (e.g., leukemia or lymphoma), a viral infection such as herpes zoster may produce persistent tissue necrosis and ulceration because of continued viral replication.<sup>8</sup> Since the patient described here showed no evidence of active viral disease by culture or skin biopsy, we believe his disease represented ulcerative leukemia cutis in an area of increased skin fragility. Herpes zoster ulcers in those patients with leukemia may be predisposed to the development of leukemia cutis because of the decreased skin resistance. To our knowledge, this is the first reported case of a patient with chronic lymphocytic leukemia and the subsequent development of leukemia cutis in an ulcer of herpes zoster. Physicians should be aware that persistent herpes zoster ulceration may be an indicator of an underlying disease, such as lymphoreticular disease, which impairs cellular immunity.

Philip L. Bailin, M.D.  
Department of Dermatology  
The Cleveland Clinic Foundation  
9500 Euclid Ave.  
Cleveland OH 44106

References

1. Andrus MS, Cigtay OS. Lymphoma with herpes zoster. *Am Fam Physician* 1980; **22**:117–118.  
2. Bluefarb SM. Leukemia Cutis. Springfield, Ill, Charles C Thomas, 1960, pp 217–221.  
3. Bluefarb SM. Cutaneous manifestations of the leukemia-lymphoma group. *Postgrad Med* 1967; **41**:476–485.  
4. Cleland JB. Leukaemic infiltrations. *Br Med J* 1935; **2**:1191–1194.  
5. Jadassohn J. Leukämische Infiltrate zoster Narben. *Zentralbl Haut U Geschlkr* 1926; **20**:741.  
6. Wilkinson JF. Cutaneous leukaemic deposits supervening on herpes zoster in a case of chronic lymphatic leukaemia. *Br J Dermatol* 1947; **59**:57–59.

Table. Cutaneous lesions*	
Nonspecific or toxic	
Pruritus with or without excoriation; pyoderma and lichenification	
Papules, prurigo	
Pigmentation, including jaundice	
Urticaria and scarlatiniform and morbilliform erythema; increased perspiration	
Erythema multiforme and erythema nodosum-like changes	
Eczematoid and psoriasiform changes	
Erythroderma (an exfoliative dermatitis)	
Bullous pemphigoid-like changes	
Herpes zoster and herpes simplex	
Purpura and hemorrhage	
Edema and lymphedema (elephantiasis)	
Trophic changes (alopecia, and ichthyosis and hyperkeratosis of the palms and soles)	
Dermatomyositis	
Phlebitis	
Miscellaneous	
Specific	
Papules	
Infiltrations or plaques	
Nodules or tumors	
Ulcers	
Mixed, or a combination of the above	
* Adapted, with permission, from Bluefarb. <sup>3</sup>	
7. Anhalt AW, Forsey RR. Herpes zoster, leukemia cutis and leukaemic infiltration of the lesions of herpes zoster. <i>Can Med Assoc J</i> 1956; <b>75</b> :750–751.	
8. Rosen T. Leukemia and lymphoma: recognizing cutaneous signs of internal malignancies. <i>Geriatrics</i> 1980; <b>35</b> :65–72 (Dec).	