

# Ultrastructural and immunomorphologic study of perinuclear filaments in Merkel cell tumors<sup>1</sup>

James T. McMahan, Ph.D.  
Raymond R. Tubbs, D.O.  
Wilma F. Bergfeld, M.D.  
Ronald G. Wheeland, M.D.  
Philip L. Bailin, M.D.

**Two cases of cutaneous small-cell tumor in patients without overt lung disease are presented. Histologic and ultrastructural findings support the diagnosis of Merkel cell tumor. Immunohistochemistry and immunoelectron microscopy demonstrate distinctive perinuclear keratin filaments that may be of histologic significance in separating a Merkel cell tumor from other nonendocrine tumors. A possible mechanism for the formation of perinuclear filamentous whorls is discussed.**

**Index terms:** Pathology features • Skin neoplasms

**Cleve Clin Q 52:103-110, Spring 1985**

The Merkel cell was first described in 1875,<sup>1</sup> and has since been described as a distinct type of neurotactile cell acting as a mechanoreceptor and transducer in vertebrate skin.<sup>2</sup> Its structure, location, and association with nerve endings have implied a sensory function, while the ultrastruc-

tural finding of dense-core granules has suggested the presence of a chemical transmitter substance.<sup>3-5</sup> The histochemical finding of metenkephalin<sup>3</sup> and neuron-specific enolase (NSE)<sup>4</sup> in Merkel cells has helped affirm its function as a receptor cell, although recent electrophysiologic studies have challenged this concept.<sup>6</sup> In 1972, Toker<sup>7</sup> described a primary carcinoma of the skin, composed of small cells in rosette-like nests and anastomosing trabeculae. Electron-microscopic studies of similar skin tumors showed intracytoplasmic neurosecretory granules typical of those seen in Merkel cells.<sup>8</sup> Descriptions of other primary skin tumors containing neuroendocrine cellular similarities<sup>5,9-13</sup> have suggested a link between small-cell tumors of the skin and the Merkel cell.

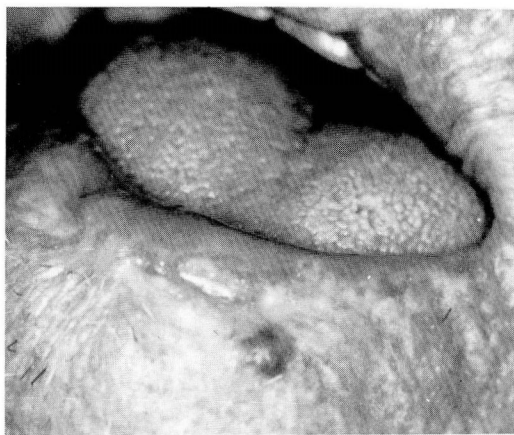
While histologic silver stains and immunohistochemical methods have generally been unreliable indicators of Merkel cell tumors,<sup>5,9-11,13,14</sup> electron microscopy has demonstrated the consistent presence of perinuclear filamentous whorls that may be useful in the differential diagnosis of cutaneous small-cell tumors.<sup>13</sup>

We present two cases of cutaneous small-cell carcinoma in patients without lung tumors. Electron microscopy and immunohistology are presented as potentially useful approaches to the

<sup>1</sup> Departments of Pathology (J.T.M., R.R.T.) and Dermatology (W.F.B., R.G.W., P.L.B.), The Cleveland Clinic Foundation. Submitted for publication Oct 1984; revision accepted Dec 1984.

0009-8787/85/01/0103/08/\$3.00/0

Copyright © 1985, The Cleveland Clinic Foundation



**Fig. 1.** A translucent, reddish-brown, 4-mm papule can be seen on the left lower lip adjacent to the vermilion border. Several small telangiectatic blood vessels were seen at the periphery.

differentiation of these neoplasms from nonendocrine tumors. The perinuclear filamentous whorls found in Merkel cell tumors are also described.

### Materials and methods

Surgical and biopsy specimens from 2 patients with nonulcerating skin masses were prepared for light-microscopic, immunohistologic, electron-microscopic, and immunoelectron-microscopic studies. Histologic sections of formalin-fixed tissue were stained with hematoxylin and eosin, Fontana-Masson, and Grimelius stains.

Immunohistologic studies were done on formalin-fixed, paraffin-embedded tissue sections, using rabbit antibodies to keratin, somatostatin, calcitonin, and NSE (Dako). Sections were incubated with biotinylated affinity-purified goat anti-rabbit IgG and preformed avidin-biotinylated complexes.<sup>15</sup> A color reaction product was developed with 3-amino, 9-ethylcarbazole (AEC) and hydrogen peroxide and counterstained with hematoxylin. Appropriate positive and negative controls were done.

Material for electron microscopy was made available through either primary glutaraldehyde fixation or electron-microscopic processing of formalin-fixed materials, each with postfixation in osmium tetroxide and embedment in Spurr resin. Thin sections were stained with uranyl acetate and lead citrate.

Immunoelectron-microscopic studies were performed on formalin-fixed sections, cut on a Vi-

bratome at 40  $\mu$ . Sections were immersed in antikeratin polyclonal antibodies and subsequently treated in a sequence of solutions similar to those used for light-microscopic antibody localization. Diaminobenzadine, however, was substituted for AEC to form osmiophilic reaction products that could be visualized under the electron microscope following osmication, embedment, and thin sectioning. Sections produced in this manner were viewed unstained so as to easily distinguish between electron-dense antibody binding sites and other nonreactive cellular components.

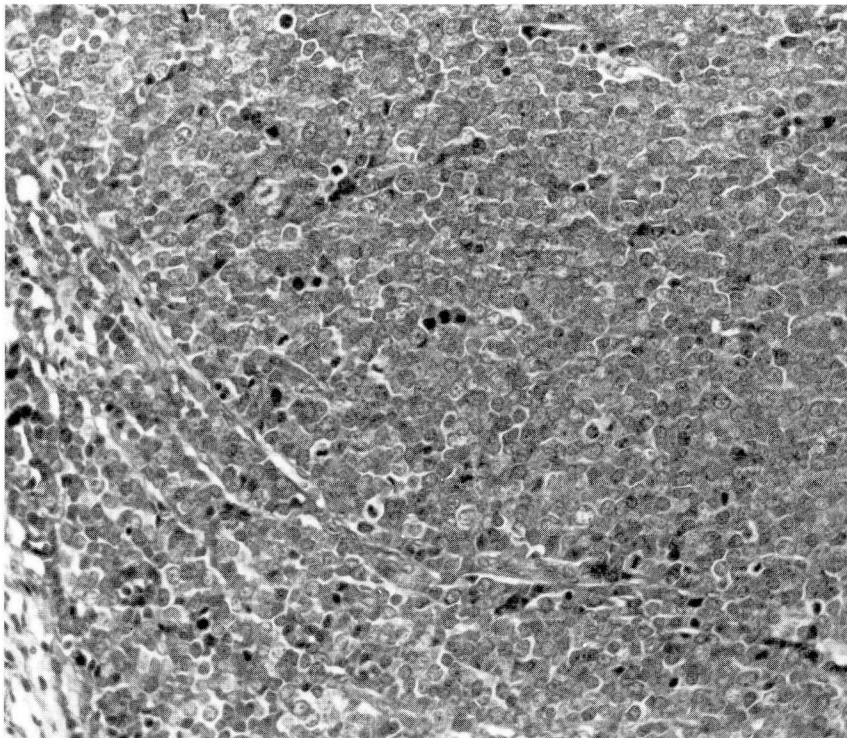
### Case reports

**Case 1.** A 77-year-old man had been treated with superficial radiation for acne as an adolescent. Beginning at the age of 43 years and continuing for 29 years, numerous facial basal cell carcinomas developed, which were treated by excision. At the age of 71, he underwent right hemicolectomy for adenocarcinoma. On admission, he had a translucent, reddish-brown 4.0-mm papule adjacent to the vermilion border of the lower lip (*Fig. 1*), which was diagnosed on biopsy as a Merkel cell tumor and was resected as a 5.0-cm nodular tumor located just beneath the lip mucosa. Chest radiographs at that time showed no active lesion. The patient subsequently received cobalt treatment to cervical lymph nodes for what was described as Merkel cell tumor metastases. The patient was readmitted several months later with abdominal pain and a 11.4-kg (25-pound) weight loss and was found to have an enlarged liver with a metastatic neoplasm demonstrated by computed tomography. The patient declined treatment, did not undergo liver biopsy, and died shortly thereafter. Autopsy was not performed.

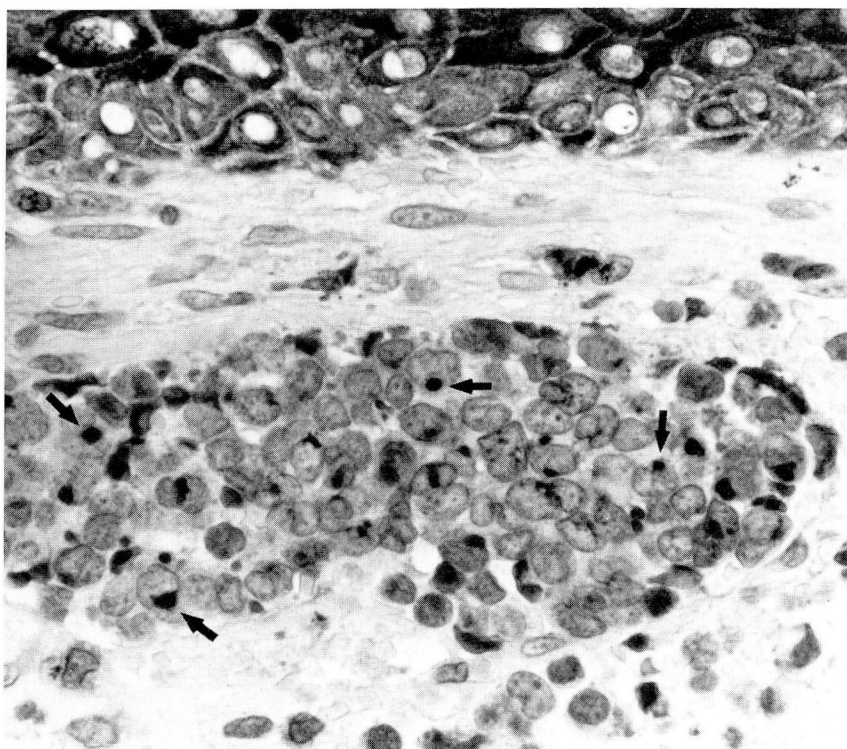
**Case 2.** A 67-year-old woman had a right axillary mass measuring 5.9 cm in greatest dimension. It was diagnosed as a Merkel cell tumor and removed by wide excision. A second Merkel cell tumor appeared at the same site within a year, at which time clinical evaluation demonstrated distant metastases to the liver. Chest radiographs were unremarkable. The patient received a course of chemotherapy, but died within 18 months of the original diagnosis. Autopsy was not performed.

### Results

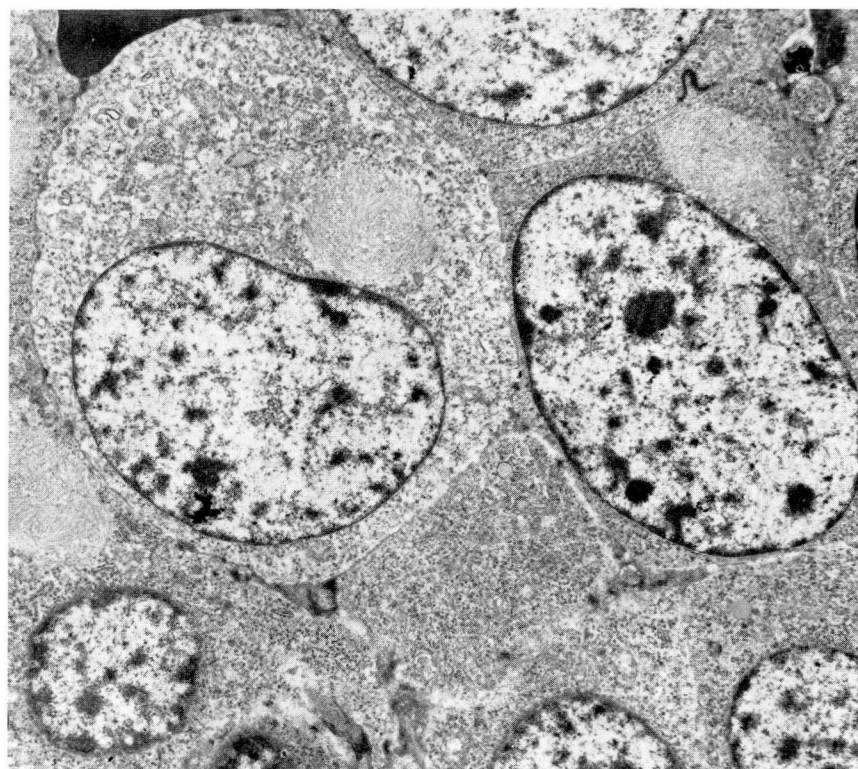
On light microscopy (*Fig. 2*), both tumors were seen to be confined to the upper dermis. They were composed of cells with a small amount of eosinophilic cytoplasm divided into clusters or nests by a fine fibrovascular network. Cells were also organized into large epithelioid sheets, or occasionally had infiltrated between collagen bundles as trabecular extensions into the dermis. Individual cells were of uniform size (15–20  $\mu$  in diameter). Nuclei were generally round to oval and exhibited finely granular chromatin with frequent invagination of the nuclear membrane.



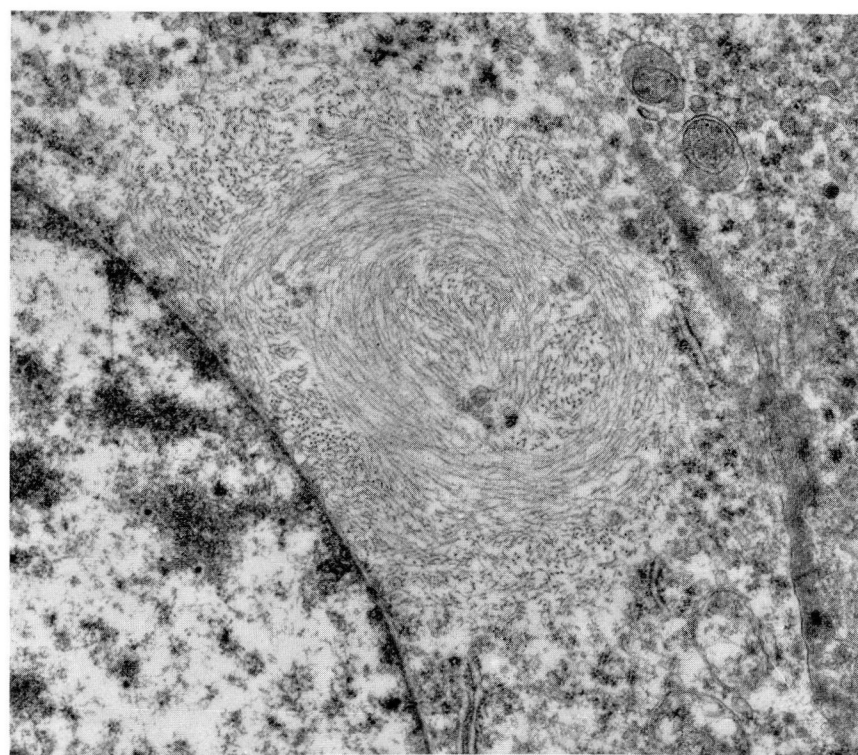
**Fig. 2.** Dermal and subcutaneous small-cell tumor demonstrates a predominantly solid growth pattern (hematoxylin and eosin stain,  $\times 325$ ).



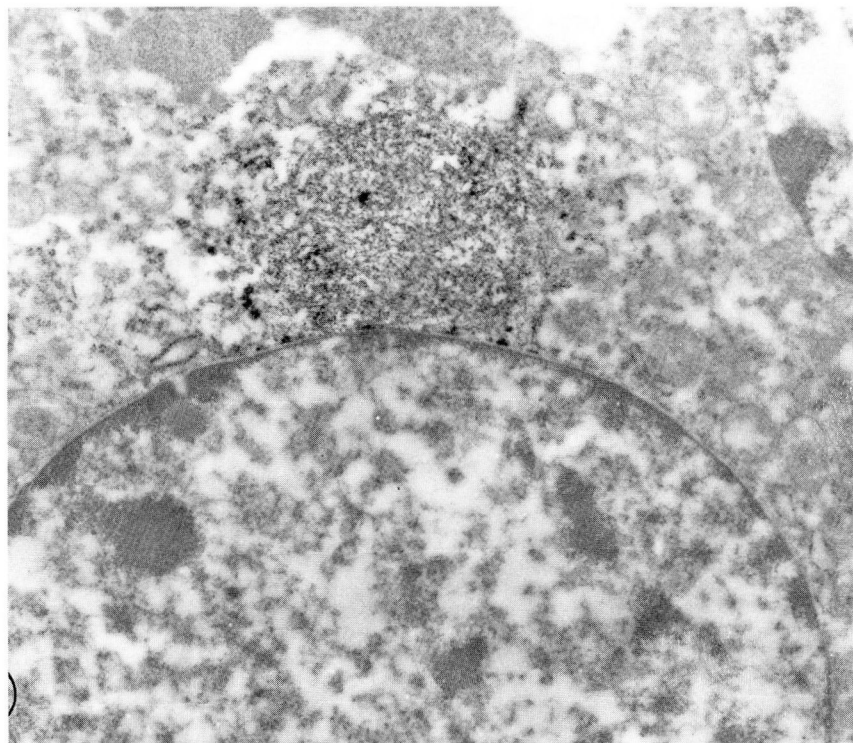
**Fig. 3.** Tumor cells with spherical perinuclear bodies containing immunoreactive keratin (*arrows*) (avidin-biotinylated peroxidase technique with aminoethylcarbazole as chromogen; hematoxylin counterstain,  $\times 1,300$ ).



**Fig. 4.** Tumor cells contain few organelles ultrastructurally. Distinctive perinuclear filamentous whorls can be identified (uranyl acetate and lead citrate,  $\times 5,600$ ).



**Fig. 5.** Filamentous whorls shown here contain 10-12-nm intermediate filaments (uranyl acetate and lead citrate,  $\times 20,000$ ).



**Fig. 6.** Immunoelectron microscopic staining of tumor cells demonstrates antikeratin binding to perinuclear filamentous whorls (avidin-biotinylated peroxidase technique with diaminobenzidine as chromogen; unstained,  $\times 16,000$ ).

Cells had a high mitotic rate, with 3–5 division figures per high-power field. Special stains, including Fontana-Masson and Grimelius, were negative. Immunohistologic stains for calcitonin, somatostatin, and NSE were also negative.

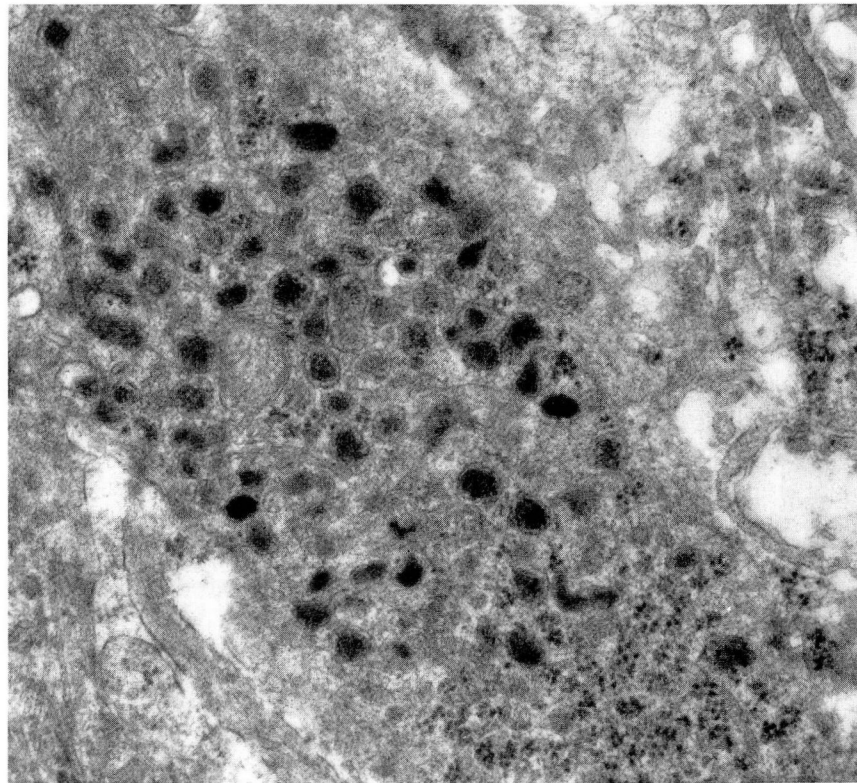
Immunolocalization of keratin revealed discrete, intracytoplasmic staining of spherical, perinuclear bodies, usually in proximity with nuclear clefts or invaginations (*Fig. 3*). These immunolabeled bodies were easily overlooked with casual light microscopy, but were distinctive and consistent on careful examination. There were one or two bodies per cell with either a patchy or diffuse distribution.

Electron microscopy demonstrated small, round to polygonal cells with poorly formed desmosomal junctions. Nuclei were variably clefted and round to oval with dispersed chromatin and small eccentric nucleoli. The scanty cytoplasm contained sparse organelles and was generally unimpressive, except for the uniform presence of perinuclear bodies ( $3\ \mu$  in diameter), composed of whorls of intermediate-sized filaments (10–12 nm in diameter) frequently found within the nuclear cleft (*Figs. 4 and 5*). The bodies were

non-membrane-bound, but were sharply demarcated from the rest of the cytoplasm, and could be seen readily in low-power fields as low-density regions immediately adjacent to the nuclei (*Fig. 4*). Immunoelectron microscopy confirmed the keratin content of the cytoplasmic filaments (*Fig. 6*). Cell membranes were generally smooth, but occasional dendritic processes contained scant to abundant numbers of dense-core neurosecretory granules (150–200 nm in diameter) with primary deposition near the cell periphery (*Fig. 7*).

### Discussion

Merkel cells in the skin of humans and other animals are closely associated with nerves and produce met-enkephalin<sup>3</sup> and NSE,<sup>4</sup> thereby supporting the concept that Merkel cells may act as transducers in neurotactile stimulation of mechanoreceptor cells. It has also been hypothesized that Merkel cells are part of the APUD cell system proposed by Pearse<sup>16</sup> as a classification of hormone-producing neuroectodermally derived cells that have Amine content, amine Precursor Uptake, and amino acid Decarboxylase activity (APUD). Ultrastructurally, Merkel cells



**Fig. 7.** Cellular processes of tumor cells contain dense-core neurosecretory granules with preferential distribution along surface membranes (uranyl acetate and lead citrate,  $\times 37,000$ ).

have dense-core granules, further supporting the hypothesis of a neurosecretory function.<sup>3,4</sup>

Merkel cell tumors are a rare but well-known entity described by various names (trabecular carcinoma,<sup>7</sup> primary small cell carcinoma of the skin,<sup>17</sup> neuroendocrine carcinoma of the skin,<sup>9</sup> cutaneous APUDoma,<sup>18</sup> and small cell neuroepithelial tumors of the skin<sup>12</sup>). It is important to recognize Merkel cell tumors due to their local aggressiveness, tendency to invade regional lymph nodes, and ability to metastasize to distant sites. Histologically, they can resemble metastatic oat cell bronchogenic carcinoma, carcinoid tumor, neuroblastoma, sweat gland carcinoma, or lymphoma. On light microscopy, Merkel cell tumors can be seen as groups of small cells growing in expansive sheets or forming organoid or trabecular patterns. Pseudoglandular formations and cellular rosettes may be seen along with prominent necrosis. Prominent lymphocytic and plasmacytic infiltrates may be seen peripheral to tumor cell masses and admixing with tumor cells. The localization of calcitonin<sup>19</sup> and somatostatin<sup>14</sup> in such tumors implies APUD derivation,

but the variability in these immunodemonstrations and the inconsistency in silver staining has made histologic classification of these tumors unreliable and misleading.

The two cases reported here are consistent with other histologic descriptions of Merkel cell tumors, and as also reported in the literature,<sup>5,9-11,13,14</sup> lack positive staining for both silver stain and immunolocalization of calcitonin, somatostatin, and NSE. Presentation of these cases is intended to demonstrate the utility of electron microscopy and immunohistology in differentiating Merkel cell tumors from other nonendocrine skin tumors, even in cases where proliferating tumor cells have lost the potential to produce polypeptide hormones or biogenic amines, or when silver stains are inconclusive.

Recent reports<sup>9,11,13</sup> have indicated that perinuclear whorls of filaments, like those described here, are consistently reproducible in Merkel cell tumors and that their ultrastructural identification may be of diagnostic importance, especially in excluding nonneuroendocrine skin tumors, which lack such features. Sidhu<sup>20</sup> has described

round masses of cytoplasmic filaments as indicators of embryologic origin in a series of APUD tumors, including small cell carcinomas of the lung and carcinoid tumors from a variety of sites. Similar-appearing filaments have also been reported as a common finding in pituitary adenomas.<sup>21</sup> Our study demonstrates the consistent presence of intracytoplasmic perinuclear whorls of intermediate filaments (10–12 nm) in skin tumor cells that also contain dense-core neurosecretory granules. The prominence of these filament bodies prompted us to further investigate their composition and to establish their presence at the light-microscopic level.

Polyclonal antibodies to keratin, demonstrated with immunoperoxidase methods, confirmed the keratin content of the filaments at the electron-microscopic level and demonstrated potential usefulness of antikeratin staining of small cell tumors of the skin at the light-microscopic level. The distinctive staining pattern of one or two spherical bodies per cell presaged ultrastructurally defined perinuclear whorls of keratin filaments and provided histologic evidence suggesting a neuroendocrine tumor despite negative silver staining and negative immunostaining for biogenic amines.

The function and genesis of the filamentous whorls in Merkel cell tumors are speculative. They may reflect perturbation of the natural state brought on by neoplastic transformation. Intermediate filaments are normally associated with cytoskeletal maintenance of cell shape and reflect a constancy in the functional state of the cell. The filamentous whorls in Merkel cell tumors may reflect continual conformational changes precipitated by a high mitotic rate, precluding cellular commitment to cell shape. The perinuclear pooling of filaments is a possible result of this noncommitment. Goldman<sup>22</sup> demonstrated perinuclear spheres of 10–12-nm filaments in cultured cells treated with colchicine and suggested that microtubules may help determine the normal distribution of intermediate filaments in spread cells. Under the influence of alkaloids, these filaments may collapse and become arrested as perinuclear caps. In a rapidly dividing tumor cell, microtubules are continually being assembled and disassembled during the repeated process of mitosis; hence, it is possible that without the sustained influence of formed cytoplasmic microtubules, intermediate filaments may form perinuclear whorls like those seen in

Merkel cell tumors. Why these filamentous whorls seem to appear principally in neuroendocrine tumors is not clear.

James T. McMahon, Ph.D.  
Department of Pathology  
The Cleveland Clinic Foundation  
9500 Euclid Ave.  
Cleveland OH 44106

## References

1. Merkel F. Tastzellen und Tastkörperchen bei den Haustieren und beim Menschen. *Arch Mikrosk Anat* 1875; **11**:636–652.
2. Smith KR Jr. The Haarscheibe. *J Invest Dermatol* 1977; **69**:68–74.
3. Hartschuh W, Weihe E, Büchler M, Helmstaedter V, Feurle GE, Forssmann WG. Met-enkephalinlike immunoreactivity in Merkel cells. *Cell Tissue Res* 1979; **201**:343–348.
4. Gu J, Polak JM, Tapia FJ, Marangos PJ, Pearse AGE. Neuron-specific enolase in the Merkel cells of mammalian skin. The use of specific antibody as a simple and reliable histologic marker. *Am J Pathol* 1981; **104**:63–68.
5. Warner TF, Uno H, Hafez GR, et al. Merkel cells and Merkel cell tumors. Ultrastructure, immunocytochemistry and review of the literature. *Cancer* 1983; **52**:238–245.
6. Gottschaldt KM, Vahle-Hinz C. Merkel cell receptors: structure and transducer function. *Science* 1981; **214**:183–186.
7. Toker C. Trabecular carcinoma of the skin. *Arch Dermatol* 1972; **105**:107–110.
8. Tang C-K, Toker C. Trabecular carcinoma of the skin: an ultrastructural study. *Cancer* 1978; **42**:2311–2321.
9. Sibley RK, Rosai J, Foucar E, Dehner LP, Bosl G. Neuroendocrine (Merkel cell) carcinoma of the skin. A histologic and ultrastructural study of two cases. *Am J Surg Pathol* 1980; **4**:211–221.
10. Sidhu GS, Feiner H, Flotte TJ, Mullins JD, Schaeffler K, Schultenover SJ. Merkel cell neoplasms. Histology, electron microscopy, biology, and histogenesis. *Am J Dermatopathol* 1980; **2**:101–119.
11. Pilotti S, Rilke F, Lombardi L. Neuroendocrine (Merkel cell) carcinoma of the skin. *Am J Surg Pathol* 1982; **6**:243–254.
12. Pollack SV, Goslen JB. Small-cell neuroepithelial tumor of skin: a Merkel-cell neoplasm? *J Dermatol Surg Oncol* 1982; **8**:116–122.
13. Wick MR, Goellner JR, Scheithauer BW, Thomas JR III, Sanchez NP, Schroeter AL. Primary neuroendocrine carcinomas of the skin (Merkel cell tumors). A clinical, histologic, and ultrastructural study of thirteen cases. *Am J Clin Pathol* 1983; **79**:6–13.
14. Silva EG, Ordonez NG, Lechago J. Immunohistochemical studies in endocrine carcinoma of the skin. *Am J Clin Pathol* 1984; **81**:558–562.
15. Hsu SM, Raine L, Fanger H. A comparative study of the peroxidase-antiperoxidase method and an avidin-biotin complex method for studying polypeptide hormones with radioimmunoassay antibodies. *Am J Clin Pathol* 1981; **75**:734–738.

16. Pearse AGE. Common cytochemical and ultrastructural characteristics of cells producing polypeptide hormones (the APUD series) and their relevance to thyroid and ultimobranchial C cells and calcitonin. *Proc R Soc Lond (Biol)* 1968; **170**:71-80.
17. Taxy JB, Ettinger DS, Wharam MD. Primary small cell carcinoma of the skin. *Cancer* 1980; **46**:2308-2311.
18. DeWolf-Peeters C, Marien K, Mebis J, Desmet V. A cutaneous APUDoma or Merkel cell tumor? A morphologically recognizable tumor with a biological and histological malignant aspect in contrast with its clinical behavior. *Cancer* 1980; **46**:1810-1816.
19. Johannessen JV, Gould VE. Neuroendocrine skin carcinoma associated with calcitonon production: a Merkel cell carcinoma? *Human Pathol* 1980; **11**(suppl):586-589.
20. Sidhu GS. The endodermal origin of digestive and respiratory tract APUD cells. Histopathologic evidence and a review of the literature. *Am J Pathol* 1979; **96**:5-20.
21. Horvath E, Kovacs K. Morphogenesis and significance of fibrous bodies in human pituitary adenomas. *Virchows Arch [Cell Pathol]* 1978; **27**:69-78.
22. Goldman RD. The role of three cytoplasmic fibers in BHK-21 cell motility. I. Microtubules and the effects of colchicine. *J Cell Biol* 1971; **51**:752-762.