Presumptive evidence of cardiac rheumatoid nodules assessed by two-dimensional echocardiography

A preliminary report[1]

Barney B. Beaver, D.O.
Ernesto E. Salcedo, M.D.
John Yiannikas, M.D.
Rafael Arsuaga, M.D.

Three patients with nodular rheumatoid arthritis underwent two-dimensional echocardiography for evaluation of cardiac murmurs of undefined etiology. Each patient had long-standing rheumatoid arthritis with palpable and visible extensor surface nodules. Discretely identifiable, nodular-appearing, echodense masses involving various cardiac structures were visualized in each of the patients examined. These echodense masses may represent cardiac rheumatoid nodules—the unique cardiac manifestation of rheumatoid heart disease.

Index terms: Heart, ultrasound studies • Rheumatoid nodule

Cleve Clin Q 52:61–64, Spring 1985

Rheumatoid nodules invading the pericardium, myocardium, and valve leaflets are recognized as the unique cardiac manifestation of rheumatoid arthritis.[1–3] Although cardiac rheumatoid nodules are more likely to be found in association with diffusely scattered subcutaneous nodules in patients with rheumatoid arthritis, their clinical presence has always been speculative and has awaited confirmation at autopsy.

In this report, we present presumptive evidence for the presence of cardiac rheumatoid nodules recognized by use of two-dimensional echocardiography in 3 patients with documented active, nodular rheumatoid arthritis. To our knowledge, no antemortem recognition of cardiac rheumatoid nodules has been reported previously.

[1] Departments of Cardiology (B.B.B., E.E.S., J.Y.) and Rheumatic and Immunologic Disease (R.A.), The Cleveland Clinic Foundation. Submitted for publication Aug 1984; revision accepted Nov 1984. lp

0009-8787/85/01/0061/04/$2.00/0

Copyright © 1985, The Cleveland Clinic Foundation

Downloaded from www.ccjm.org on April 24, 2024. For personal use only. All other uses require permission.

A, B

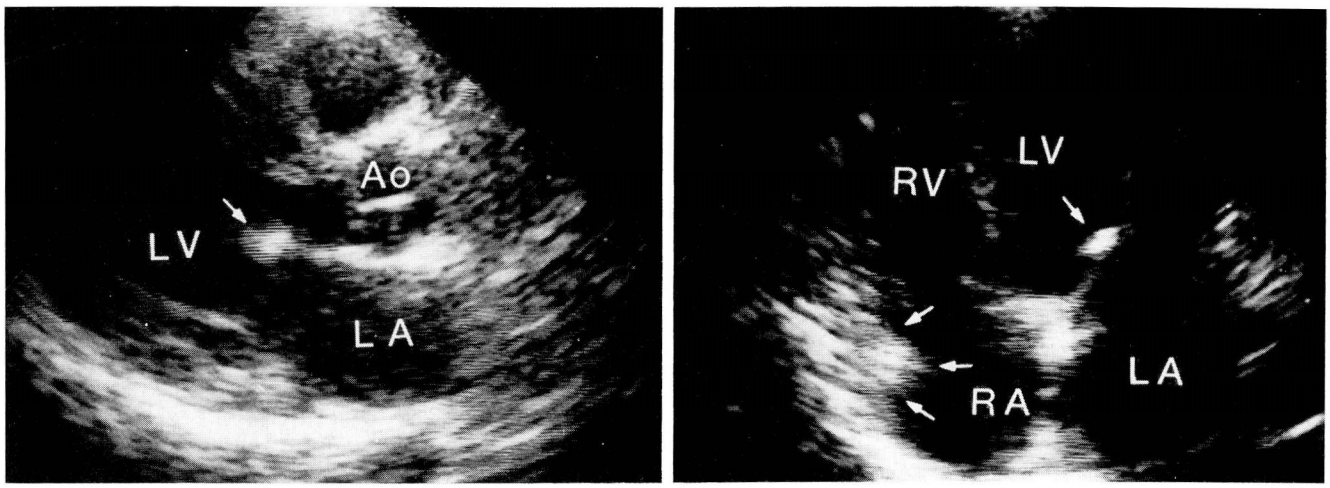

Fig. 1. Case 1.
A. Long-axis left parasternal view, demonstrating a nodular density in the top of the anterior mitral leaflet (arrow).
B. Apical four-chamber view, demonstrating a round mass in the lateral wall of the right atrium near the tricuspid ring (group of three arrows). The nodular density in the top of the mitral valve can also be noted from this view (single arrow).
Ao = aorta, *LA* = left atrium, *LV* = left ventricle, *RA* = right atrium, and *RV* = right ventricle.

Case reports

Case 1. A 66-year-old white woman was referred for echocardiographic evaluation following an episode of congestive heart failure associated with a new heart murmur. The patient had a six-month history of active nodular rheumatoid arthritis for which she was using a nonsteroidal antiinflammatory agent. Her medical history was negative for previous cardiovascular abnormalities. At physical examination, the patient was afebrile and normotensive although she had bibasilar rales and a gallop rhythm in association with a soft apical holosystolic murmur. Peripheral signs of infective endocarditis were absent. The chest radiograph revealed a pleural effusion and a diffuse reticulonodular interstitial pattern. The electrocardiogram demonstrated nonspecific ST-T wave changes, and the rheumatoid factor was positive at 152 RLS units (normal, <10 RLS units).

A two-dimensional echocardiogram was obtained with the use of a Hewlett-Packard 77020A phased-array echocardiograph. The left parasternal, long-axis view demonstrated an obvious, moderately large echodense mass near the tip of the anterior mitral leaflet (*Fig. 1A*). The four-

A, B

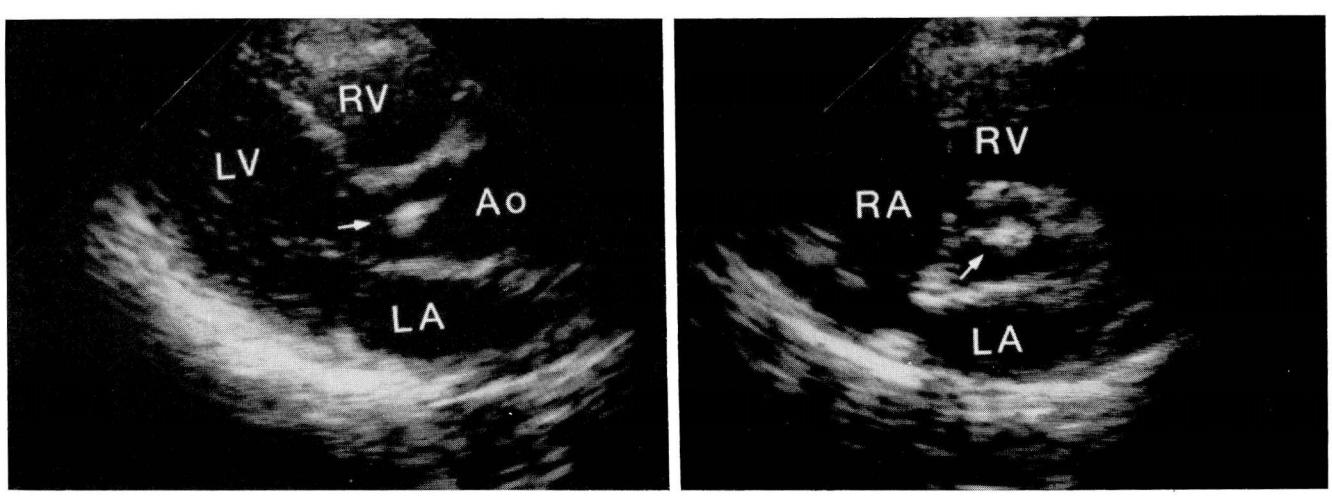

Fig. 2. Case 2.
A. Left parasternal long-axis view shows nodular thickening of the aortic valve compromising primarily the anterior leaflet (arrow).
B. Left parasternal short-axis view at the level of the aorta shows that the nodular density involves primarily the right coronary cusp (arrow).
Ao = aorta, *LA* = left atrium, *LV* = left ventricle, *RA* = right atrium, and *RV* = right ventricle.

Downloaded from www.ccjm.org on April 24, 2024. For personal use only. All other uses require permission.

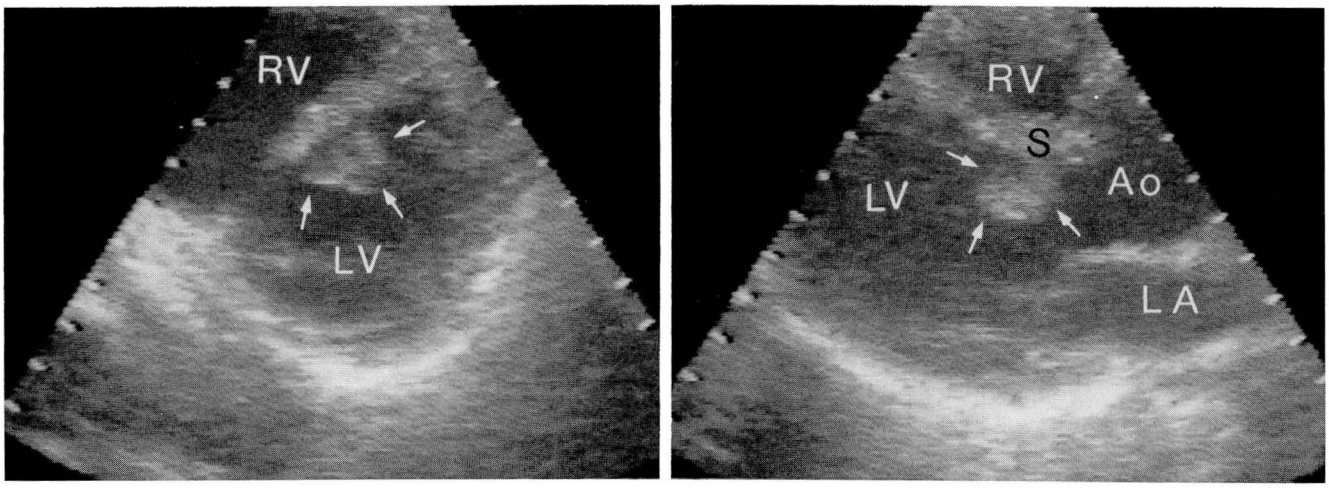

Fig. 3. Case 3.

A. Left parasternal short-axis view, demonstrating a round echo-dense mass attached to the interventricular septum protruding into the left ventricle (arrows).

B. Left parasternal long-axis view, demonstrating a round echo-dense mass attached to the high interventricular septum partially obstructing the left ventricular outflow tract.

Ao = aorta, *LA* = left atrium, *LV* = left ventricle, *RV* = right ventricle, and *S* = septum.

chamber view clearly delineated the nodular-appearing mass to be located on the anterior mitral leaflet (*Fig. 1B*). This view also revealed a distinct, round, less-echodense mass in the tricuspid annular region and the base of the tricuspid leaflet. The left and right ventricles were dilated with a generalized reduction in contractility. The M-mode echocardiogram demonstrated an increased density of the anterior mitral leaflet when the transducer beam was directed over the nodule.

Case 2. A 58-year-old white woman with a 28-year history of seropositive rheumatoid arthritis was referred for echocardiographic examination to evaluate a heart murmur. There was no history of cardiac disease except that a murmur had been noted since 1979 coincident with the development of extensor surface nodules. The physical examination was unremarkable except for the presence of a grade III/VI systolic ejection murmur along the left sternal border and evidence of active synovitis in association with multiple extensor surface nodules. The electrocardiogram revealed nonspecific ST-T wave changes, and the chest radiograph was normal. The rheumatoid factor was positive at 173 RLS units.

A two-dimensional echocardiogram was obtained with the use of a Hewlett-Packard phased-array echocardiograph. The left parasternal long-axis view revealed a discrete echodense mass at the level of the aortic valve. The mitral valve was normal. Left ventricular and atrial chamber sizes were normal (*Fig. 2A*). The left parasternal short-axis view demonstrated that this discrete mass of echoes was attached to the right coronary cusp of the aortic valve (*Fig. 2B*). The aortic leaflets were otherwise freely mobile without evidence of commissural fusion or doming.

Case 3. A 62-year-old white woman with long-standing progressive nodular rheumatoid arthritis was referred for an echocardiogram to evaluate a heart murmur. The patient had an eight-year history of chronic stable angina and hypertension. The physical examination revealed a grade II/VI holosystolic apical murmur and extensive upper and lower joint deformity. The rheumatoid factor was positive by latex fixation. Nonspecific ST-T wave changes were noted on the electrocardiogram.

A two-dimensional echocardiogram was obtained with the use of an Irex phased-array sector scanner. The left parasternal short-axis view showed a round echodense mass attached to the interventricular septum and protruding into the left ventricle (*Fig. 3A*). The long-axis left parasternal view revealed this mass to be attached to the interventricular septum just below the aortic valve leaflets (*Fig. 3B*). The mass appeared to be immobile during continuous scanning. The left atrial and ventricular chamber sizes were normal, and no thickening of the valve leaflets was identified.

Coronary angiography and left ventriculography was performed in another institution. A filling defect was identified in the septal region of the left ventricle during contrast opacification in addition to diffuse coronary atherosclerosis. No mitral regurgitation was observed.

Discussion

Initial descriptions of discrete rheumatoid involvement of the heart originated from postmortem studies of patients with rheumatoid arthritis.[1–4] Pericarditis, myocarditis, and valvular thickening were the most commonly recognized manifestations of rheumatoid heart disease, yet these findings were nonspecific in nature. The pathognomonic lesion in rheumatoid heart disease—the cardiac rheumatoid nodule—was identified in 1% to 3% of selected autopsy patients

Downloaded from www.ccjm.org on April 24, 2024. For personal use only. All other uses require permission.

and was morphologically and histologically indistinguishable from typical subcutaneous nodules. In those patients with cardiac rheumatoid nodules, the mitral valve appeared to be affected most frequently, followed by the aortic, tricuspid, and pulmonary valves.[5]

Carpenter et al[5] and Roberts et al[6] described the exact location of rheumatoid nodules within the cardiac valves and valve rings as observed in two autopsied patients with quadrivalvular involvement. Besides the visibly identifiable nodules within the myocardium, a focal lesion was identified at the basal attachment of the septal and anterior leaflets of the tricuspid valve, which was similar to the lesion we described in Case 1. Discrete nodules were identified at the basilar attachment of the pulmonary valve cusps in each of their patients. Generally, cardiac nodules involving left-sided cardiac valves tended to be diffuse and gave the appearance of valvular thickening. Moreover, both of their patients had murmurs of aortic and mitral insufficiency antemortem and these were believed to be secondary to diffuse nodular involvement of the respective valve leaflets.

Multiple conflicting M-mode echocardiographic investigation results involving patients with rheumatoid arthritis can be found in the literature.[7-12] Most of these studies defined nonspecific abnormalities of the mitral valve which were believed to be indirect evidence of nodular invasion of valvular tissue. Two subsequent investigations[10,12] concluded that improper transducer positioning was frequently responsible for the reported mitral valve abnormalities.

With the advent of two-dimensional echocardiography, the antemortem identification of cardiac rheumatoid nodules appears to be more feasible. Our presumptive diagnosis of cardiac rheumatoid nodules in 3 patients lacked tissue confirmation, although the gross appearance and location of the cardiac nodules we have described was supported by the similar pathological location of cardiac nodules in two autopsied patients described by Carpenter et al[5] and Roberts et al.[6] Although superimposed cardiovascular conditions could be responsible for the murmurs noted in our cases, the presence of valvular rheumatoid nodules should also be considered. Further, it is possible that these nodules may represent vegetations, thrombus, tumors, or myxomatous proliferation. Nevertheless, in each of the cases described, severe nodular rheumatoid arthritis was present without a history of endocarditis or rheumatic carditis, and our premise that these nodules are rheumatoid in etiology would seem tenable.

Our preliminary report suggests a potentially important role for two-dimensional echocardiography in the assessment of patients with rheumatoid arthritis and heart murmurs of unexplained etiology. Prospective studies that will corroborate our echocardiographic findings with tissue evidence are needed. We may then be able to further define the natural history of rheumatoid heart disease, which will allow appropriate clinical intervention.

Acknowledgment

The authors are grateful to Robert Murnane, M.D., for allowing us to evaluate his patient (Case 3).

Ernesto E. Salcedo, M.D.
Department of Cardiology
The Cleveland Clinic Foundation
9500 Euclid Ave.
Cleveland OH 44106

References

1. Sokoloff L. The heart in rheumatoid arthritis. Am Heart J 1953; **45:**635–643.
2. Cruickshank B. Heart lesions in rheumatoid disease. J Pathol Bacteriol 1958; **76:**223–240.
3. Lebowitz WB. The heart in rheumatoid arthritis (rheumatoid disease: a clinical and pathological study of sixty-two cases). Ann Intern Med 1963; **58:**102–123.
4. Cathcart ES, Spodick DH. Rheumatoid heart disease: a study of the incidence and nature of cardiac lesions in rheumatoid arthritis. N Engl J Med 1962; **266:**959–964.
5. Carpenter DF, Golden A, Roberts WC. Quadrivalvular rheumatoid heart disease associated with left bundle branch block. Am J Med 1967; **43:**922–929.
6. Roberts WC, Kehoe JA, Carpenter DF, Golden A. Cardiac valvular lesions in rheumatoid arthritis. Arch Intern Med 1968; **122:**141–146.
7. Prakash R, Atassi A, Poske R, Rosen KM. Prevalence of pericardial effusion and mitral-valve involvement in patients with rheumatoid arthritis without cardiac symptoms: an echocardiographic evaluation. N Engl J Med 1973; **289:**597–600.
8. Nomeir A, Turner R, Watts E, Smith D, West G, Edmonds J. Cardiac involvement in rheumatoid arthritis. Ann Intern Med 1973; **79:**800–806.
9. Bacon PA, Gibson DG. Cardiac involvement in rheumatoid arthritis: an echocardiographic study. Ann Rheum Dis 1974; **33:**20–24.
10. Davia JE, Cheitlin MD, de Castro CM, Lawless O, Niemi L. Absence of echocardiographic abnormalities of the anterior mitral valve leaflet in rheumatoid arthritis. Ann Intern Med 1975; **83:**500–502.
11. Hernandez-Lopez E, Chahine RA, Anastassiades P, Raizner AE, Lidsky MD. Echocardiographic study of the cardiac involvement in rheumatoid arthritis. Chest 1977; **72:**52–55.
12. MacDonald WJ Jr, Crawford MH, Klippel JH, Zvaifler NJ, O'Rourke RA. Echocardiographic assessment of cardiac structure and function in patients with rheumatoid arthritis. Am J Med 1977; **63:**890–896.

Downloaded from www.ccjm.org on April 24, 2024. For personal use only. All other uses require permission.